ORIGINAL RESEARCH PAPER

Volume-7 | Issue-2 | February-2018 | PRINT ISSN No 2277 - 8179

INTERNATIONAL JOURNAL OF SCIENTIFIC RESEARCH

A CASE OF 14 YR OLD PATIENT DIAGNOSED AS A CASE OF HERLYN WERNER WUNDERLICH SYNDROME.

Gynaecology

Yogesh P. Patel* PG Student Dept of OBGY, BJMC, Ahmedabad. *Corresponding Author

Tejal L. Patel Associate Professor, Dept of OBGY, BJMC, Ahmedabad

ABSTRACT

Introduction: The Herlyn-Werner-Wunderlich syndrome is a rare, congenital disorder characterised by uterus didelphys, unilateral obstructed hemivagina and ipsilateral renal agenesis, all being secondary to mesonephric duct-induced Mullerian anomalies. It is also known as obstructed hemivagina and ipsilateral renal anomaly (OHVIRA). It is generally observed in post-menarche adolescents and young women with dysmenorrhea, irregular menses, abdominal pain and pelvic mass.

Case report: A 14 years old Unmarried girl presented with complaints Pain in left illiafossa since 3 months white discharge Per vaginum since 3 days, pain during defecation since 3 months and bed weating (At night) since childhood.she had regular menstrual periods. She was admitted at Rajkot civil hospital from 30/1/2015 to 17/02/2015 for heamatocolpos and haematometra and hydrosalpinx and managed conservatively and was on oral antibiotics tablet doxycycline. Her MRI (6/10/2015) showed Bicornuatebicollis, Uterine didelphys cannot be ruled out. Large collection detected at vaginal cavity with gross dilatation of cavity and also extending to left side cervical and uterine cavity with its mild dilatation. Both ovaries appears normal. Mild ascitis. Left Kidney appears ectopic at left iliac fossa with altered axis with gross dilatation of PC system and visible ureter. Her vitals were normal and on abdominal examination soft swelling in left iliac fossa was felt. On per speculum, soft collection in vagina seen and on per rectum examination, soft bulking felt 10*8cm felt anteriorly. Incision and drainage done .under short general anaesthesia. A curvilinear incision kept over bulging area chochlate material drained and no active bleeding present. Diagnostic laproscopy was done and Dye test performed no spillage on left tube found. Few adhesions present between left ovary and left tube. Dissected with sharp scissor. Patient had given injectable antibiotics after procedure for 7 days and then patient discharged with no complaints.

KEYWORDS

Herlyn-Werner-Wunderlich syndrome, post-menarche adolescents

Introduction

The Herlyn-Werner-Wunderlich syndrome is a rare, congenital disorder characterised by uterus didelphys, unilateral obstructed hemivagina and ipsilateral renal agenesis, all being secondary to mesonephric duct-induced Mullerian anomalies. It is also known as obstructed hemivagina and ipsilateral renal anomaly (OHVIRA). It is generally observed in post-menarche adolescents and young women with dysmenorrhea, irregular menses, abdominal pain and pelvic mass [1]

Case Report

Unmarried with haematocolposhaematometra&Hydrosalpinx AND left renal agenesis.

With Complaints: Pain of left illiafossa * Since 3 month
White discharge P/V * Since 3 day
Pain during defecation * Since 3 month
Bed weating (At night) since childhood.

Menstrual history lmp 6/11/2015 regular moderate painful
Obstetric history unmarried

Past history : patient was admitted at Rajkot civil hospital from 30/1/2015 to 17/02/2015 for heamatocolpos and haematometra and hydrosalpinx and managed conservatively and was on oral antibiotics tablet doxycycline.

Outsided investigations
Mri(6/10/2015)

Bicornuatebicollis uterus detected, however lower end of right sided cavity can not be traced due to large collection,Uterine didelphys cannot be ruled out.Right cavity appears smaller compare to left side.

Large collection detected at vaginal cavity with gross dilatation of cavity and also extending to left side cervical and uterine cavity with its mild dilatation, which appears hyperintense on T1 WI and hypointense on T2 WI and does not show suppression on T1FS sequences.

Approx size of vaginal collection is 15X8X7.2 cm.
On GRE no evidence of blooming within collection – suggest no evidence of internal haemorrhage.

Both ovaries appears normal.

Mild ascitis.

Left Kidneyappears ectopic at left iliac fossa with altered axis with gross dilatation of PC system and visible ureter.

USG – ABDOMEN-PELVIS(6/nov/2015)
Left kidney is not seen in left renal fossa but is seen in left iliac fossa with gross dilation of left renal pelvis (43mm) with dilated upper ureter showing moving internal echoes.

Urinary bladder appear well distended with internal echoes.
Bicornuate uterus is noted with 23CC sized collection in left cornua communicating with collection with vagina is noted.

Approx 350cc sized collection with internal echoes is noted in vaginal cavity.

Approx 4.7X2.3 sized mm sized cystic with fine internal septations is noted in left ovary s/o hemorrhagic cyst.

Minimal free in peritoneal cavity.
USG – ABDOMEN-PELVIS (27/nov/2015)
Left kidney is not seen in left renal fossa or any other ectopic p/o agenesis.

Urinary bladder appear well distended and normal.
Bicornuate uterus is noted

Minimal fluid collection is noted along left side of cervix.
Both ovaries shows multiple follicles within.

Left fallopian tube appears dilated with thickened wall and shows internal echoes, maximum diameter = 2cm.
With following vitals
Pulse 96 per minute
Bp 110/70

Per abdomen : soft with swelling in left iliac fossa
Per speculum : soft collection in vagina
Per rectum : soft bulking felt 10*8cm,,anteriorly.
On 6/11/2015

Incision and drainage done .under short general anaesthesia.
A curvilinear incision kept over bulging area chochlate material

drained and no active bleeding present.

Per op finding
Hymen ruptured collection drained uterus soft and bulging 10*8cm anteriorly.haematocolpos and haematometra.

Post drainage usg13/12/2015
Left kidney not seen in left renal fossa s/o agenesis
Bicornuate uterus is noted.

Air foci noted in cervix
Haematosalpinx is noted in left side
Minimal free fluid with internal septation is noted in left adnexa
Right cornu measures approx 60*20 mm and shows no collection no collection in vagina et is 4.5mm
Left cornu 7*3cm et 6mm
Both ovaries normal
Minimal free fluid in peritoneal cavity.

Diagnostic laproscopy done on 21/12/2015
Dye test performed no spillage on left tube.

Few adhesions present between left ovary and left tube. Dissected with sharp scissor.

Per op diagnosis
Uterus diadelphys right horn well developed with obstructed left hemivagina with left tube blockage with usg finding suggestive of left renal dysgenesis.

Patient had given injectable antibiotics after procedure for 7 days and then patient discharged with no complaits.

Discussion

Mullerian (paramesonephric) duct anomalies are congenital anomalies of the female genital tract which result from non-development or non-fusion of the mullerian ducts or failed resorption of the uterine septum during the sixth to ninth weeks of fetal life causing a wide-ranging series of reproductive ducts malformations.[56]

The paramesonephric ducts of the genetically female embryo fuse together in the midline and form the uterus, cervix and the upper four-fifths of the vagina. The lower 20% of the vagina are formed from sinovaginal bulbs which are protrusions of the urogenital sinus.[7] The urinary and genital systems arise from a common ridge of mesoderm arising along the dorsal body wall and rely on normal development of the mesonephric system. Hence, abnormal differentiation of the mesonephric and paramesonephric ducts may also be associated with anomalies of the kidneys.[7] Renal agenesis is the most common anomaly although horseshoe or pelvic kidney, cystic renal dysplasia, duplication of the collecting system and ectopic ureters have all been described.[7 8] Renal agenesis is predictive of an ipsilateral obstructive Mullerian anomaly greater than 50% of the time.8 These anomalies have a right-sided dominance, twice as often as on the left side.[9 10] Such relationship between female genital and urogenital anomalies should lead us to examine the urogenital system when a genital anomaly is identified and vice-versa.[4]

Typically, HWW syndrome presents with acute or chronic pelvic pain shortly following menarche.[2] These patients menstruate normally and may have no specific symptoms, except dismenorrhea.[4] A progressively enlarging pelvic mass has also been described.[5] If treatment is delayed, complications may develop, such as endometriosis caused by retrograde menstruation, infections and pelvic adhesions, which in turn might cause obstruction of the genital organs. Clinical suspicion and awareness of the syndrome are therefore imperative to making a timely diagnosis and preventing these complications.[11] In one study, it was demonstrated that the delay in diagnosis was due to several factors. As the patient menstruates regularly from the non-obstructed horn, the diagnosis of outflow obstruction is more difficult. Second, it is an uncommon condition and therefore not often thought of as a diagnostic possibility. Third, when these adolescents present to their paediatrician or family physician with symptoms of cyclic dysmenorrhoea, they are usually given anti-inflammatory drugs and oral contraceptives. These treatments inadvertently cause a delay in diagnosis as they diminish or eliminate menses.[2]

CT and ultrasound are the most widely used diagnostic tools.[11] However, MRI is considered to be more sensitive for imaging soft-tissue anatomy and delineating subtle findings seen in congenital anomalies. Hence, it should be obtained before any surgical intervention.[2] Laparoscopy is not mandatory but could be helpful in confirming the diagnosis when radiologic imaging is inconclusive, especially in those cases with endometriomas warranting resection.[3] As obstructive genital lesions may be associated with other anomalies such as coarctation of the aorta, atrialseptal defects and abnormalities of the lumbar spine, a complete physical examination and abdominal tests may be indicated.[2]

Resection of the vaginal septum is the treatment of choice of obstructed hemivagina.[5]

Women with uterus didelphys have a reasonable chance of getting pregnant, but the abortion rate is high (74%) and premature delivery is common (22%).[12] A caesarean section is required in 82%.[10]

Evaluation of the genital tract by means of MRI scanning is recommended in all girls with known renal abnormalities detected antenatally or thereafter, before the onset of menstruation. This enable us to diagnose some patients before menarche and carry out a surgical correction of the obstruction before any damage has occurred because of haematocolpos, haematometra and retrograde menstruation.

Conclusion:

HWW syndrome can present early or late, depending on the type. In patients with uterine and vaginal abnormalities, a work-up for associated renal anomalies should be performed. Early intervention is needed to reduce the risk of endometriosis and infertility.

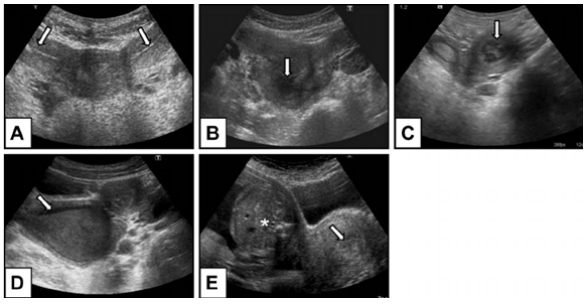

Sonographic imaging findings of patients with Herlyn-Werner-Wunderlich syndrome. (A) Double uterus and cervix with echogenicendometrium (arrows) indicating a uterus didelphys. (B) Uterus didelphys accompanied by hematometra with heterogeneous, mixed echogenic content (arrow). (C) Left-sided hematometra with mixed echogenic content (arrow). (D) Fluid- fl uid level of hematocolpos (arrow). (E) Didelphys uteri with single 25-week live pregnancy in right-sided uterine body (asterisk) and left-sided hematometra with heterogeneous, echogenic fl uid component (arrow).

REFERENCES

1. Purslow CE. A case of unilateral haematocolpos, haematometra and haematosalpinx. J Obstet Gyaecol Br Emp 1922;29:643
2. Zurawin RK, Dietrich JE, Heard MJ, et al. Didelphic uterus and obstructed hemivagina with renal agenesis: case report and review of the literature. J Pediatr Adolesc Gynecol 2004;17:137–41 [PubMed]
3. Smith NA, Laufer MR. Obstructed hemivagina and ipsilateral renal anomaly (OHVIRA) syndrome: management and follow-up. Fertil Steril 2007;87:918–22 [PubMed]
4. Jeong J-H, Kin Y-J, Chang C-H, et al. A case of Herlyn–Werner–Wunderlich syndrome with recurrent hematopyometra. J Womens Med 2009;2:77–80
5. Jindal G, Kachhawa S, Meena GL, et al. Uterus didelphys with unilateral obstructed hemivagina with hematometrocolpos and hematosalpinx with ipsilateral renal agenesis. J Hum Reprod Sci 2009;2:87–9 [PMC free article] [PubMed]
6. Ballesio L, Andreoli C, De Cicco ML, et al. Hematocolpos in double vagina associated with uterus didelphus: US and MR findings. Eur J Radiol 2003;45:150–3 [PubMed]
7. Troiano RN. Magnetic resonance imaging of mullerian duct anomalies of the uterus. Top Magn Reson Imaging 2003;14:269–79 [PubMed]
8. Shavell VI, Montgomery SE, Johnson SC, et al. Complete septate uterus, obstructed hemivagina, and ipsilateral renal anomaly: pregnancy course complicated by a rare urogenital anomaly. Arch Gynecol Obstet 2009;280:449–52 [PubMed]
9. Vercellini P, Daguati R, Somigliana E, et al. Asymmetric lateral distribution of obstructed hemivagina and renal agenesis in women with uterus didelphys: institutional case series and a systematic literature review. Fertil Steril 2007;87:719–24 [PubMed]