ORIGINAL RESEARCH PAPER

Volume-8 | Issue-1 | January-2019 | PRINT ISSN No 2277 - 8179

INTERNATIONAL JOURNAL OF SCIENTIFIC RESEARCH

A CASE OF BILATERAL CYTOMEGALOVIRUS ANTERIOR UVEITIS WITH SECONDARY GLAUCOMA IN A IMMUNOCOMPETENT PATIENT

Ophthalmology

Dr. Meena Gopinath Menon MS, DNB, FRCS, Sankara Eye Hospital, Bengaluru.

Dr. Vijaya L Alle* MS, Sankara Eye Hospital, Bengaluru. *Corresponding Author

ABSTRACT

Background: Cytomegalovirus associated anterior uveitis is an uncommon form of anterior uveitis associated with long term sequelae and vision threatening complication like secondary glaucoma and endothelial decompensation.

Case: This report describes an unusual case of 52 year old female patient with bilateral CMV anterior hypertensive uveitis with intractable glaucoma with maximum anti glaucoma medications requiring early filteration surgery in both eyes.

Clinical significance: Human TM cells effectively support active CMV replication. CMV induced increased expression of TGF-β1 is responsible for outflow resistance, leading to elevation of intraocular pressure (IOP). The use of antiviral agent alone cannot lower the IOP nor change the course of the disease. Secondary glaucoma management is very important in such patients to prevent vision threatening sequelae.

KEYWORDS

Cytomegalovirus, uveitis, glaucoma

Background: Cytomegalovirus(CMV) has been recognized as a cause of morbidity and mortality, mostly in immunocompromised individuals. Recent reports have shown that CMV infection is an emerging cause of anterior uveitis associated with ocular hypertension in immunocompetent subjects[1, 2, 5, 6]. CMV is also an important cause of corneal endothelitis, particularly in Asian populations [7–12].The pathogenesis of CMV-induced anterior uveitis in immunocompetent patients and the systemic and ocular characteristics of the disease are not well understood.

In this article we report a challenging case of CMV anterior uveitis with secondary glaucoma and its management. The importance of management of intractable high intraocular pressure (IOP) to prevent further optic nerve damage is discussed in this case.

Report of the case: In March 2013, a52-year-old female patient diagnosed with CMV associated chronic anterior uveitis was referred to our hospital, by an ophthalmologist for further management of constantly high intraocular pressure.The diagnosis of CMV uveitis was done after Xcyton SES on aqueous tap sample came positive for CMV.

The patient had complaints of light sensitivity, irritation, ocular pain, redness in both eyes. Patient was already on bromonidine(0.1%) + timolol(0.5%) eyedrops twice daily in both eyes. On examination, Patient had BCVA of 20/20 in both eyes. IOP was 56 mm Hg OD and 24 mm Hg OS. On slit lamp examination, RE had circumcorneal congestion, corneal edema, flare grade 3+, cells 3+, fine keratic precipitates on endothelium and clear lens. In LE, cornea was clear and AC was quiet.In both eyes, fundus showed cup disc ratio of 0.5 with healthy neuroreinal rim .The specular microscopy showed normal endothelial count with mild polymegathism in both eyes. Complete blood count and ESR was within normal limits. Other serological investigations were negative. Serum CMV-IgG was positive (107µ/mL) CMV-IgM was negative.Patient was started on additional tablet acetazolamide twice daily for 3 days and brinzolamide eyedrops thrice daily in both eyes. The patient had been on regular follow-up for three years, since then. During this period, she had recurrent attacks of anterior uveitis and raised intra-ocular pressure in either eye, which had been controlled by topical and systemic anti-glaucoma medication and topical steroids.She was also started on a course of Valgancyclovir, topical(0.15% gel 5 times daily) and oral 900mg twice daily for 6 weeks then once daily for 6 weeks, which was not very fruitful in controlling the attacks of inflammation. However, over the last six months, the intraocular pressure in both her eyes continued to be intractably high in spite of maximum systemic and topical anti-glaucoma medication. A real time polymerase chain reaction (PCR) was done in January 2016 which did not show evidence of any active viral replication. Hence a decision was made to defer oral antiviral medications and opt for filtration surgery.

The right eye Trabeculectomy with Mitomycin C (0.2 mg/ml) was first undertaken in March 2016, the intraocular pressure being 40 mm Hg pre-operatively. Following surgery the IOP was 16 mm Hg OD without any anti-glaucoma medication(figure1).Three months following which, the left eye IOP was also noted be consistently high, not resolving with maximum anti-glaucoma medication, thus the left eye surgery was also under taken. The pre-operative IOP was 52 mm Hg in the left eye; hence a Pars-plana vitrectomy along with a Trabeculectomy with Mitomycin C (0.2 mg/ml) was done May 2016 (figure-2), to avoid any unexpected vision threatening complications intra-operatively. Following surgery the left eye IOP was also well controlled at 14 mm Hg. The patient has maintained BCVA of 20/20 with good IOP control without anti glaucoma medications and stable fundi in both the eyes 6 months postoperatively. Patient developed posterior subcapsular cataract for which phacoemulsification with foldable IOL implantation was done in April 2017. Serial specular microscopy shows good endothelial count with mild polymegathisim in both eyes(table 1). Thereafter patient has been under close follow-up and has not developed any acute attack of uveitis and maintains a stable vision of 20/20 both eyes with well controlled IOP.

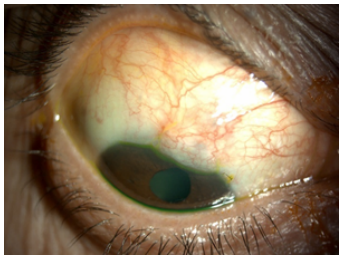

Figure1: right eye post trabeculectomy- bleb well formed, cornea clear, AC quiet & maintained

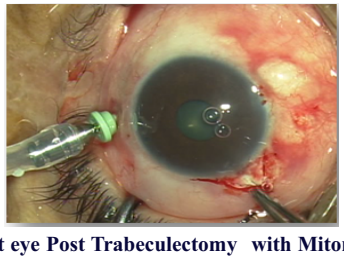

Figure 2 :Left eye Post Trabeculectomy with Mitomycin C with Pars Plana Vitrectomy

Table1- serial endothelial counts on specular microscopy ,

	Right eye	Left eye
Oct. 2013	2572/mm^2	2605/mm^2
Nov 2015	2731/mm^2	2624/mm^2
Mar 2016	2492/mm^2	2422/mm^2

Discussion:

CMV anterior uveitis can result in significant visual morbidity due to its recurrent or chronic disease course [9]. The main complications include cataract formation, corneal decompensation, secondary open angle and steroid induced glaucoma [14]. This entity affects the anterior segment of the eye only. Posterior segment involvement is not typically reported with CMV anterior uveitis.

Cytomegalovirus (CMV)belongs to family Herpes viridae (subfamily Betaherpesvirinae). Humans and monkeys serve as natural hosts. It's thought that 50-80% of adults are infected with CMV. All herpesviruses share a characteristic ability to remain latent within the body over long periods. Site of CMV latency is in bone marrow resident CD34+ myeloid progenitor cells as well as in their derivative CD14+ monocytes present in peripheral blood. CMV can be reactivated when circulating monocytes with latent CMV are recruited to sites of inflammation. For this reactivation, inflammatory cytokines, such as tumor necrosis factor and interferon, are known to play a role. It is suggested that chronic inflammation in the anterior chamber may trigger CMV reactivation, which in turn, aggravates the inflammatory condition.Local immunosuppression by topical steroid use increases the risk of CMV infection in immunocompetent patients.[14,15,16]

Choi et al. demonstrated that human TM cells effectively support active CMV replication. CMV infection resulted in significantly elevated expression of TGF-β1 in human TM cells. TGF-β1 is an upstream cytokine that regulates outflow facility by inducing characteristic structural changes of TM cells. TGF-β1 and TGF-β2 increase extracellular matrix (ECM) production and inhibit the degradation of presenting ECM8. TGF-β1 increases the contraction of TM cell and TGF-β2 decreases the population of TM cell by inhibition of cell proliferation. These changes contributes to outflow resistance, leading to elevation of intraocular pressure (IOP), which eventually, leads to glaucomatous optic neuropathy. In CMV viral anterior uveitis, virus produces high amount of TGF-β1 as an early event, which may increase the concentration of TGF-β1 in the anterior chamber. With the repeated recurrence, the decreased cellularity of TM cells induced by CMV infection may cause the elevation of IOP and poor prognosis of the patients.[17]

Studies also proved that treatment with viral DNA polymerase inhibitor ganciclovir did not affect the TGF-β1 production, although it decreased viral DNA replication. The use of antiviral agent alone cannot lower the IOP nor change the course of the disease. It may be associated with the fact that TGF-β production cannot be inhibited by antiviral agent.No specific drug regime is described to prevent relapse and high relapse rates have been observed once the medication is stopped.[17]

Thus secondary glaucoma is an important vision threatening sequelae of CMV anterior uveitis. Although our case did not have glaucomatous optic neuropathy at the time of diagnosis,it is likely that she might have developed optic nerve head changes with time with such high intractable intraocular pressure. Early filtration surgery has helped to control IOP before development of any significant optic nerve head damage.This case is unique because it signifies the importance of early surgical intervention to control the intractable high IOP in view of failure of medical management.

Conclusions:CMV is significant etiological factor in hypertensive anterior uveitis patients. Valgancyclovir therapy alone is not effective to stop the irreversible trabecular changes or alter the course of glaucoma development in such patients. Secondary glaucoma management is very important in such patients to prevent vision threatening sequelae.

REFERENCES :

1. Chee SP, Bacsal K, Jap A, Se-Thoe SY, Cheng CL, Tan BH (2008) Clinicalfeatures of cytomegalovirus anterior uveitis in immunocompetent patients. Am J Ophthalmol 145:834-840
2. Van Boxtel LA, Van der Lelij A, van der Meer J, Los LI (2007) Cytomegalovirusas a cause of anterior uveitis in immunocompetent patients.Ophthalmology 114:1358–1362
3. Jap A, Chee SP (2010) Emerging forms of viral uveitis in the developing world. IntOphthalmolClin 50:155–171
4. Jap A, Chee SP (2011) Viral anterior uveitis. CurrOpinOphthalmol 22:483–488
5. Park SW, Yu HG (2013) Association of cytomegalovirus with idiopathicchronic anterior uveitis with ocular hypertension in Korean patients. OculImmunolInflamm 21:192–196
6. Knox DL (2008) Clinical features of cytomegalovirus anterior uveitis inimmunocompetent patients. Am J Ophthalmol 146:625, author reply 625-626
7. Koizumi N, Inatomi T, Suzuki T et al (2015) Clinical features andmanagement of cytomegalovirus corneal endotheliitis: analysis of 106 casesfrom the Japan corneal endotheliitis study. Br J Ophthalmol 99:54–58
8. Kobayashi A, Yokogawa H, Higashide T, Nitta K, Sugiyama K (2012) Clinicalsignificance of owl eye morphologic features by in vivo laser confocalmicroscopy in patients with cytomegalovirus corneal endotheliitis. Am JOphthalmol 153:445–453
9. Chee SP, Bacsal K, Jap A, Se-Thoe SY, Cheng CL, Tan BH (2007) Cornealendotheliitis associated with evidence of cytomegalovirus infection.Ophthalmology 114:798–803
10. Sungur GK, Hazirolan D, Yalvac IS, Ozer PA, Aslan BS, Duman S (2010)Incidence and prognosis of ocular hypertension secondary to viral uveitis.IntOphthalmol 30:191–194
11. Kandori M, Miyazaki D, Yakura K, Komatsu N, Touge C, Ishikura R, Inoue Y(2013) Relationship between the number of cytomegalovirus in anteriorchamber and severity of anterior segment inflammation. Jpn J Ophthalmol57(6):497–502
12. Lewkowicz D, Willermain F, Relvas LJ et al (2015) Clinical outcome ofhypertensive uveitis. J Ophthalmol 2015:974870
13. Chee SP, Jap A (2011) Immune ring formation associated with cytomegalovirus endotheliitis. Am J Ophthalmol 152:449–453, e441
14. Taylor-Wiedeman J, Sissons JG, Borysiewicz LK, Sinclair JH (1991) Monocytesare a major site of persistence of human cytomegalovirus in peripheralblood mononuclear cells. J Gen Virol 72:2059–2064
15. Smith MS, Bentz GL, Alexander JS, Yurochko AD (2004) Humancytomegalovirus induces monocyte differentiation and migration as astrategy for dissemination and persistence. J Virol 78:4444–4453
16. Wikby A, Johansson B, Olsson J, Löfgren S, Nilsson BO, Ferguson F (2002)Expansions of peripheral blood CD8 T-lymphocyte subpopulations and anassociation with cytomegalovirus seropositivityin the elderly: the SwedishNONA immune study. ExpGerontol 37:445–453
17. Jin A Choi, Ju-Eun Kim, Seung-Jun Noh, EunKyoung Kim et al. Enhanced cytomegalovirus infection in human trabecular meshwork cells and its implication in glaucoma pathogenesis. Sci Rep. 2017; 7: 43349.