ORIGINAL RESEARCH PAPER
VOLUME-6 | ISSUE-6 | JUNE-2017 | ISSN No 2277 - 8179 | IF : 4.176 | IC Value : 78.46
INTERNATIONAL JOURNAL OF SCIENTIFIC RESEARCH

'A Case of Discoid Lupus Erythematosus treated with homoeopathic medication'

Homoeopathy

Dr. Manas Ranjan Sarangi Research Officer (H)/Scientist, Central Council for Research in Homoeopathy, Govt. of India. 61-65, Institutional Area, Opp. D-Block, Janakpuri, New Delhi, Delhi 110058.

ABSTRACT

Discoid Lupus Erythematosus (DLE) is an autoimmune, inflammatory, disfiguring skin disease. It is a severe form of skin inflammation which occurs particularly on sun-exposed skin. A 30-year-old female presented with four years' history of erythematous patches on face and oral cavity. A skin biopsy specimen was diagnostic of discoid lupus erythematosus. This case showed improvement with homoeopathic therapy.

KEYWORDS:

Discoid Lupus Erythematosus, Homoeopathy, Histopathology, Natrum muriaticum.

Introduction

Lupus erythematosus (LE) is an autoimmune disease. Within the spectrum of diseases included in LE, at one end is a disease confined mainly to the skin and referred to as Discoid lupus erythematosus (DLE) and at the other end is a florid disease with systemic involvement of heart, lungs, brain, kidneys and other organs called Systemic lupus erythematosus (SLE). In between the two ends of the spectrum are disorders like subacute cutaneous lupus erythematosus (SCLE). 1% to 5% of patients with DLE may develop SLE and 25% of patients with SLE may develop typical chronic discoid lesions at some time during their illness[1].

Genetically predisposed individuals are stimulated by a variety of factors including UV rays, usually UVA, occasionally UVB or both, but also stress, infections and even temperature changes. These exogenous forces lead to epidermal cell death and the exposure or revealing of normally intracellular antigens, such as nucleoprotein RO, La SnRNP double-stranded DNA, which then trigger an auto-immune response characterized in the laboratory by the presence of ANA[2].

There have been no accurate studies on the prevalence of DLE, although all forms of lupus erythematosus are particularly common in women of childbearing age[3]. But, DLE occurs at all ages, among all ethnic groups. It commonly presents with erythematous, scaly papules and plaques on sun-exposed parts. Lesions are common on the face. Involvement of the scalp produces a scarring alopecia. Early effective treatment may lead to total clearing of the skin lesions, but failure of treatment results in permanent scarring[3]. DLE should also be viewed as a precancerous condition. Squamous cell carcinoma may develop in chronic lesions of DLE[4,5]. The diagnosis of Discoid lupus erythematosus is generally made based on clinical features. Histology may be required to confirm the diagnosis. It is important to recognize DLE at an early stage because it is a potentially scarring disease. No medications have been approved specifically for the treatment of DLE[6]. Topical steroids and anti-malarial are used as conventional treatment. Patients are sensitized towards avoidance of exposure to sun and use of protective clothing.

Homoeopathy is a system of medicine discovered by Dr Samuel Hahnemann, in 1796, which is based on the law of 'Similia Similibus Curanter' which means 'like cures like'[7]. There has been no documented case of DLE, treated with homoeopathic medication, but there are many drugs in the literature of homoeopathy which can treat conditions with similar presentations.

Case Summary

A female aged 30 yrs. presented at Homoeopathic Treatment Centre, SJ Hospital, New Delhi (a unit of CCRH, New Delhi) complaining of red patchy lesions on face and mouth for 4 yrs. The lesions of the face were localized on cheeks, chin, above left eye and near right ear. Mild itching was present in the lesions on face and there was white scaling off and on. The lesions used to appear in summer only, but when the patient reported, it was present throughout the year. Burning pain was present in the lesions in the mouth which was aggravated from hot food and spicy food.

Patient was taking conventional treatment for 4 years without any positive results. She was prescribed *Mometasone Furoate* cream for local application, *Levocetrizine Dihydrochloride* 1 Tab O.D, *Triamcinalone acetonide* oral paste, *Clobetasol propionate* cream for local application and *Hydroxychloroquine Sulphate* 1 Tab. O.D, which she took for one and half years and there was no relief.

The patient is married and a housewife. She preferred cold weather and her complaints were aggravated on exposure to warmth. She had increased thirst. Her bowel movements were unsatisfactory with hard stool. She had a desire for salty food and spicy food, but even mild spicy food caused burning in mouth, which was earlier tolerable before her complaints started. There were no specific aversions to any specific food. Her menses were irregular, with 2-3 days' cycle and profuse bleeding. Her sleep was sound, refreshing without any specific dreams. Since her complaints started, she has become irritable, depressed, tendency to cry and when consoled by somebody, it was aggravated.

General Physical Examination

The patient was lean built weighing 45 kgs. There were no signs of cyanosis, jaundice, pallor, clubbing or oedema. Her pulse rate was regular and 80/min and her B.P was 110/72 mm of hg. Tongue was moist and clear.

Systemic Examination

Skin - Red patchy lesions on cheeks, chin, above left eye and near right ear. *GI system* - Red patchy lesions on hard palate. No organomegaly. *Cardiovascular system* - S_1 and S_2 normal, no added sounds. *Respiratory system* - Normal breath sounds, no added sounds. *Nervous system* – Conscious and cooperative. Oriented to time, place & person. Higher mental functions–normal, Cranial nerves–intact. Motor functions–normal. Sensory functions–normal. Reflexes–normal.

Investigations done

Histopathology report – Material submitted for Skin Biopsy. Section shows epidermis with follicular plugging and focal basal layer damage. Dermis shows scattered melanophages, superficial and deep perivascular and perifollicular lymphohistocytic infiltrate and some foamy histocytes. Fite stain did not show AFB. Sarcoidosis and LP excluded.

Impression: Features compatible with DLE.

Prescription and Follow-up

The case was repertorized using the software HOMPATH and Kent's repertory was selected.

Table 1: Repertorization table

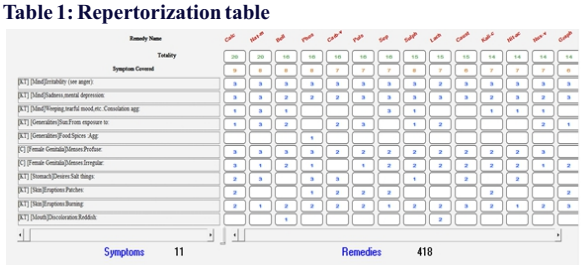

Calcarea carb, Natrum muriaticum, Belladonna, Phosphorus and Carbo veg covered more number of symptoms, but, *Natrum muriaticum* was selected for the case as it covered the important mental generals, desires for salty things and complaints were aggravated when exposed to sun.

Table 2: Follow-up

	04.07.2008	31.10.2008	05.01.2009	30.06.2009	15.09.2009
Symptoms	• Red patchy eruptions in face. • Red patchy eruptions in oral cavity. • Burning sensation in oral cavity. • Burning of eruptions of skin < heat exposure to kitchen stove • Irritableness • Depressed. • Weeping tendency. Aggravated by consolation.	• Red patchy eruptions in face same as before. • Red patchy eruptions in oral cavity. • Burning sensation in oral cavity initially decreased 10 days after taking medication, then increased after 12-15 days relief. • Burning of eruptions of skin < heat exposure to kitchen present.	• Red patchy eruptions in face same as before. • Red patchy eruptions in oral cavity slightly decreased. • Burning sensation in oral cavity decreased. • Burning of eruptions of skin < heat exposure to kitchen stove absent.	• Red patchy eruptions in face decreased. • Red patchy eruptions in oral cavity decreased. • Burning sensation in oral cavity absent.	• Red patchy eruptions in face decreased. • Red patchy eruptions in oral cavity decreased. • Patient was cheerful. • Weeping tendency was less as reported by husband.
Medicine with dosage	*Natrum muriaticum* 200C, six globules, thrice daily for one day followed by placebo twice daily for 15 days.	*Natrum muriaticum* 200C, six globules, thrice daily for one day followed by placebo twice daily for 15 days.	Placebo twice daily for 15 days	Placebo twice daily for 15 days	Placebo twice daily for 15 days

Discussion and conclusion

Discoid lupus erythematosus (DLE) is the most common form of chronic cutaneous lupus erythematosus (CCLE) and is mostly seen in women between 20-40 years of age. Delay or failure of treatment results in permanent scarring. The depressed scars, hair loss, and pigmentary changes are often extremely disfiguring. Permanent scarring is the rule if treatment is delayed or inadequate. Great emotional distress, social isolation, and difficulty obtaining work are problems frequently suffered by these patients. This patient was prescribed antimalarials, anti allergic and topical steroids for one and half years but there was no palpable relief. She was anxious about her disease and was getting irritated over minor issues. So, she discontinued the use of conventional therapy and started taking homoeopathic treatment and got symptomatic relief. The progression of eruptions on her body were less. She was not having any complaints till she was followed-up for 4 years. This is a case which shows the effect of homoeopathic medication in a disease which could have had serious psychological impact in the patient's life.

Acknowledgement

The author would like to thank Dr R K Manchanda, Director General, CCRH, New Delhi and Dr C Nayak, Ex-Director General, CCRH, New Delhi for their advice and constant encouragement. The author also acknowledges Dr Rita Bagai and Dr V K Paul, Retd. Scientists, HTC, Safdarjung Hospital (unit of CCRH, New Delhi) and Dr B S Arya, Asstt. Director, Central Research Institute, Noida for their valuable suggestions and support. The author also thanks Dr D Nayak, Research Officer (H), CCRH, New Delhi for his suggestions.

Conflict of interest None

References

1. Panjwani Suresh. Early diagnosis and treatment of discoid lupus erythematosus. JABFM, Vol. 22 No. 2; March-April 2009: 206-212.
2. Braun-Falco O, Plewig G, Wolff H H, Burgdorf W H C, Dermatology, Springer - Vertag, Berlin, Heidelberg, New York, 2000: 797
3. Jessop S, Whitelaw DA, Delamere FM, Drugs for discoid lupus erythematosus. Cochrane Library, Issue 4, 2009: 2
4. Fernandes et al, Discoid lupus erythematosus with squamous cell carcinoma: a case report and review of the literature in Indian patients. Lupus. 2016 Dec; (14): 1562-6.
5. Gnonhagen C M, Nyberg F, Cutaneous lupus erythematosus: An update. Indian Dermatology Online Journal. 2014 Jan-Mar; 5(1): 7-13
6. Garza Mayers AC, McClurkin, Smith GP, Review of treatment for discoid lupus erythematosus. Dermatologic Therapy. 2016 Jul:29(4):274-83.
7. Sarkar B K, Organon of medicine by Samuel Hahnemann (Fifth & Sixth edition). M Bhattacharya & Co. (P) Ltd 1984. 75-83, 519.
8. Boericke W. Pocket manual of homoeopathic materia medica. New Delhi: B. Jain Publishers (P) Ltd 2000: 459-462.
9. Allen H. C. Keynotes and characteristics with comparisons of some of the leading remedies of the materia medica with nosodes. New Delhi: B. Jain Publishers (P) Ltd 1997: 199-202.
10. Shah J, HOMPATH Classic Version 8.0.
11. Kent J T, Repertory of the Homoeopathic materia medica. Jain pulishing Co 1978. 57-58, 75, 92, 400, 486, 725, 726, 1309-1310, 1313, 1364, 1404.