ORIGINAL RESEARCH PAPER
Volume-6 | Issue-10 | October-2017 | ISSN No 2277 - 8179 | IF : 4.176 | IC Value : 78.46
INTERNATIONAL JOURNAL OF SCIENTIFIC RESEARCH

# A CASE OF MULTI-SITE INTRAOCULAR CYSTICERCOSIS WITH ASSOCIATED NEUROCYSTICERCOSIS: A RARE ENTITY.

Ophthalmology

**Sheela P Kerkar** — Additional Professor and Head of Department, Department of Ophthalmology, Seth G. S. Medical College and K.E.M. Hospital, Mumbai.

**Samruddhi Dani** — Junior Resident, Department of Ophthalmology, Seth G.S. Medical College and K.E.M. Hospital.

**Priyarthi Pradhan** — Junior Resident, Department of Ophthalmology, Seth G.S. Medical College and K.E.M. Hospital.

**Vikram Nakhate** — Visiting Retina Consultant, Department of Ophthalmology, Seth G.S. Medical College and K.E.M. Hospital.

## ABSTRACT

Ocular cysticercosis occurs as a result of development of Taenia solium larvae, Cysticercus cellulosae, in the eye. This condition is prevalent worldwide, but is particularly common in developing countries. The eye is one of the common locations for parasitic development because of its rich vascularization. Intraorbital cysticercosis accounts for 75 to 85% of the cases and if not treated, can lead to blindness. [1] Intravitreal involvement is the most common form, followed by subretinal involvement. Involvement of other structures such as the anterior chamber, iris and lens is rare. [1]

We report a case study showing intraocular cysticercosis including subretinal as well as intracameral involvement, with associated neurocysticercosis, which is a very rare entity.

## KEYWORDS

Intraocular cysticercosis, Subretinal cysticercosis, intracameral cysticercosis

**Introduction:**

Human cysticercosis is caused by Cysticercus cellulosae, the larval form of the cestode Taenia solium. It occurs by ingestion of eggs of the parasite via faecal-oral transmission from a tapeworm host. Humans then become an accidental intermediate host. The primary larvae penetrate the intestinal mucosa and enter the bloodstream. Hematogenous spread to various tissues occurs. Within these tissues, the primary larvae develop into secondary larvae (i.e., the cysticerci). The eye, like the nervous system and muscle tissue, is a prime location for parasite development due to its rich vascular supply. Radiological diagnosis can be made using ultrasonography, CT and MRI. Cysticercosis is easily diagnosed by orbital imaging by its highly specific appearance. CT and MR imaging not only confirm the diagnosis but also help to rule out neurocysticercosis. Intraocular cysticercosis is rare and can be highly destructive because the cyst gradually increases in size and leads to progressive loss of vision. Associated neurological involvement is rare. Medical treatment of intraocular cysticercosis should be avoided because the death of the organism can release toxic substances, which can lead to intense inflammation with resultant phthisis bulbi. Early surgical removal of the parasite and complete cyst excision is the treatment of choice.

**Case Report:**

A 7 year old girl came to the hospital with the history of gradual, painless, progressive diminution of vision, associated with redness of the left eye since 1 month. There was no history of trauma or any major systemic illness. The patient was a non-vegetarian by diet. On ophthalmic examination, her visual acuity was 6/6 in the right eye and perception of light with projection of rays positive in all quadrants in the left eye. On anterior segment and funduscopic examination, the right eye was within normal limits. Slit lamp examination showed a scolex in the anterior chamber of the left eye with associated anterior chamber reaction and a cataractous lens [Figure 1]. Fundoscopic examination showed a poor glow. Hematological studies showed anaemia and an elevated ESR. Stools were negative for any helminthiasis. On B-scan, multiple septations of low to moderate amplitude with good after movements suggestive of vitreous membranes were seen, a subretinal sonolucent ring with well-defined margins was seen nasal to optic nerve measuring about 5*6mm with the presence of an intracystic eccentric hyperechoic lesion measuring about 1mm, suggestive of cysticercosis with scolex within [Figure 2]. MRI of the brain showed a FLAIR hypointense lesion in the superior and nasal aspect of the left globe, 7*6mm in size, without restricted diffusion and susceptibility on SWI, with no post contrast enhancement, suggestive of intraocular cysticercosis. There was also 5*4*4mm T2/FLAIR hypointense lesion in the right temporal region, with susceptibility on SWI without restricted diffusion, with intense enhancement on post contrast study, likely to be neurocysticercosis [Figure 3a, 3b]. Medical treatment was contraindicated in this case as it leads to death of the parasite which could incite a severe inflammatory reaction eventually leading to phthisis bulbi. The anterior chamber scolex was surgically removed by anterior chamber paracentesis and sent for microbiological examination, which confirmed it to be scolex of Taenia [Figure 4]. The patient underwent a lensectomy with pars plana vitrectomy with subretinal cyst removal.



**Figure 1: Anterior chamber of the left eye showing scolex of the cysticercus inferiorly.**

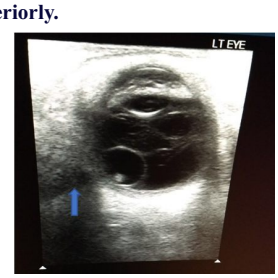


**Figure 2: B-scan of the left eye showing multiple septations of low to moderate amplitude with good after movements suggestive of**

**vitreous membranes, a subretinal sonolucent ring with well-defined margins seen nasal to optic nerve (arrowhead) measuring about 5*6mm with the presence of an intracystic eccentric hyperechoic lesion measuring about 1mm, suggestive of cysticercosis with a scolex within.**

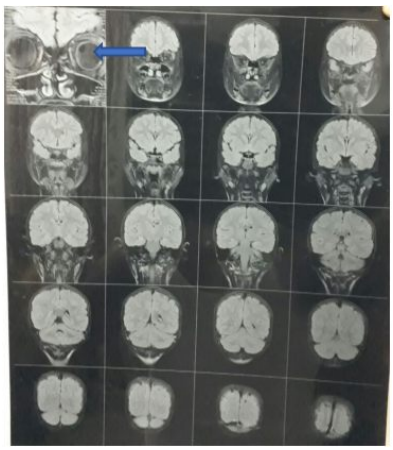

**Figure 3a: MRI showing FLAIR hypointense lesion in the superior and nasal aspect of the left globe, 7*6mm in size, without restricted diffusion and susceptibility on SWI, with no post contrast enhancement, suggestive of intraocular cysticercosis.**

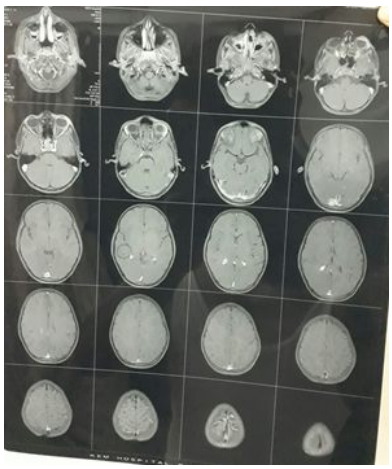

**Figure 3b: MRI showing 5*4*4mm T2/FLAIR hypointense lesion in the right temporal region, with susceptibility on SWI without restricted diffusion, with intense enhancement on post contrast study, likely to be neurocysticercosis.**

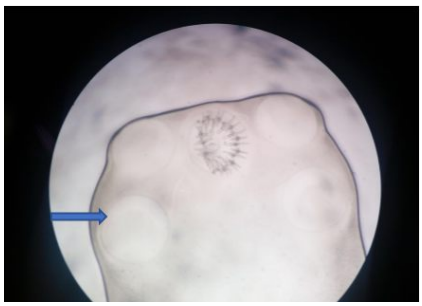

**Figure 4: Microscopic examination of the anterior chamber paracentesis fluid showing scolex of Taenia with suckers.**

**Discussion:**

Cysticercosis affects an estimated 50 million people across the world. [2] Ocular cysticercosis is endemic in tropical regions, such as Sub-Saharan Africa, India, East Asia, Mexico and Latin America.[2] In India, both intraocular and extraocular cysticercosis are seen to be equally prevalent. The incidence of ocular involvement in patients with cysticercosis, in endemic areas, ranges from 10 to 30%.[2] Some European studies have reported a higher incidence of ocular cysticercosis than neurocysticercosis. In Western countries, the most common site of involvement of ocular cysticercosis is the sub-retinal space.[3] However, several other studies have shown that vitreous cysts are more common than retinal or subretinal cysts, and the inferotemporal subretinal cyst is the most commonly affected quadrant in the retina.[9] This patient had a sub-retinal cyst in the superonasal quadrant, which is an uncommon location as compared to intravitreal cysts. The parasite enters the retina through the high flow choroidal circulation and subsequently migrates to the subretinal space, and from there into the vitreous.

Human cysticercosis is a parasitic infection caused by cysticercus cellulosae, the larval form of Taenia solium. Cysticercosis is caused by the haematogenous spread of the larvae. [4] The adult worm in the human intestine sheds proglottids containing the eggs, which are passed in the faeces. The eggs, after ingestion by pigs, lead to development of cysticerci in their muscles. However, humans may accidentally act as intermediate hosts. Food habits, poor hygienic conditions and autoinfection may predispose to the condition. Cysticercosis in humans may involve the CNS, subcutaneous tissue, eye or other viscera. Ocular cysticercosis includes cysts in eyelids, adnexa, extraocular muscles, orbit, conjunctiva, anterior chamber, uvea, retina, vitreous or the optic nerve.[5] In literature, there are only a few reports of cysticercosis involving the eye as well as the brain.[6]

Cysticercosis, due to its highly specific appearance, can be well diagnosed by orbital imaging techniques. CT and MRI imaging additionally also help to rule out associated brain involvement. The characteristic radiological findings of cysticercosis include a cystic lesion with a central nodule that represents the scolex. On MRI, cysticerci appear hyperintense, with well-defined edges, which show a hypointense eccentric nodule within, representing the scolex. The presence of a scolex in a cystic lesion is usually highly suggestive of cysticercosis.[8],[9] The differential diagnosis of ocular cysticercosis is a hydatid cyst, which rarely involves the eye. Ocular hydatid cysts of the eye are larger in size and require surgical removal. Another important differential diagnosis is an orbital pseudotumor.

For management of subretinal cysts positioned anterior to the equator, trans-scleral approaches are used for cyst removal, whereas for intravitreal cyst and subretinal cyst located posterior to the equator, a pars plana vitrectomy or a transvitreal approach is used.[10] Histopathological examination of the paracentesis fluid in this case showed a scolex of Taenia with its suckers.

In cases where there is both intraocular and CNS involvement, the complete intraocular cyst must be surgically excised, followed by antiparasitic treatment such as albendazole with corticosteroids. The live parasite is not killed initially because it induces severe intraocular reactions which would thereby lead to blindness.[7] Surgical removal of the intracameral as well as intravitreal cyst and subsequent medical treatment for CNS parasitosis was safe and effective.

**References:**


1. Ocular cysticercosis. Auzemery A, Andriantsimahavandy A, Esterre P, Boitte JP, Huquet P. Med Trop (Mars) 1995; 55 (4 Pt 2): 429-33.
2. Ocular cysticercosis: A review. Dinesh Patel, Hemkala Trivedi, Sujit Murade, Sujata Tank. Bombay Hospital Journal 2011; Vol 53; Special Issue:420-425.
3. Subretinal cysticercosis. Bartholomew RS. American Journal of Ophthalmology. 1975;79:670-673.
4. Hoberg EP. Taenia tapeworms: Their biology, evolution and socioeconomic significance. Microbes Infect 2002;4:859-66.
5. Sharma T, Sinha S, Shah N, Gopal L, Shanmugam MP, Bhende P, et al. Intraocular cysticercosis: Clinical characteristics and visual outcome after vitreoretinal surgery. Ophthalmology 2003;110:996-1004
6. Das D, Deka S, Islam S, Deuri N, Deka P, Deka AC, et al. Neuro and intraocular cysticercosis: A clinicopathological case report. Eye and Brain 2010;2:39 – 42.
7. Rao KM, Vargiya SV, Kohli N. Rapid onset unilateral vision loss by intra-ocular cysticercosis-Demonstrated by MRI. Ind J Radiol Imag 1999;9:3.
8. Del Brutto OH, Rajshekhar V, White AC Jr, Tsang VC, Nash TE, Takaya- nagui OM, et al. Proposed diagnostic criteria for neurocysticercosis. Neurology 2001;57:177-83.
9. Nijjar I, Singh JP, Arora V, Abrol R, Sandhu PS, Chopra R, et al. MRI in intraocular cysticercosis - A case report. Indian J Radiol Imag 2005;15:309-10.
10. Parashari UC, Khanduri S, Qayyum FA, Bhadury S. A radiological case report on intraocular cysticercosis with associated vitreous detachment and neurocysticercosis. Ann Trop Med Public Health 2012;5:367-9