Volume : 4 | Issue : 6 | June 2015 • ISSN No 2277 - 8179

Research Paper

Medical Science

KEYWORDS :

A Case of Superior Mesenteric Artery Syndrome

DR AJAY H PATEL	GENERAL SURGEON, PROFESSOR OF SURGERY, Smt. N.H.L. MUNICIPAL MEDICAL COLLEGE AND SHETH K. M. SCHOOL OF POSTGRADUATE MEDICINE AND RESEARCH, ELLISEBRIDGE, AHMEDABAD-6. INDIA
DR AMIT H JOSHI	ASSISTANT PROFESSOR OF SURGERY, Smt. N.H.L. MUNICIPAL MEDICAL COLLEGE AND SHETH K. M. SCHOOL OF POSTGRADUATE MEDICINE AND RESEARCH, ELLISEBRIDGE, AHMEDABAD-6. INDIA
DR NILAY SHAH	1ST YEAR RECIDENT,DEPARTMENT OF GEN. SURGERY,Smt. N.H.L. MUNICIPAL MEDICAL COLLEGE AND SHETH K. M. SCHOOL OF POSTGRADUATE MEDICINE AND RESEARCH, ELLISEBRIDGE, AHMEDABAD-6, INDIA

ABSTRACT

Superior mesenteric artery syndrome (SMAS) is a rare condition caused by compression of the third part of the duodenum between the superior mesenteric artery (SMA) and the aorta, causing symptoms of duodenal outflow obstruction.We report a case of superior mesenteric artery syndrome in a 22-year-old male associated with severe dehydration and vomiting and resulting from duodenal compression that necessitated surgical treatment.

Introduction

Superior mesenteric artery syndrome is a rare condition first described by Rokitansky in1861. The condition results from a reduced angle between the artery at its origin from the abdominal aorta and the transverse third part of the duodenum causing duodenal obstruction. Diagnosis of the syndrome depends on high index of suspicion, augmented by the radiological features of the syndrome. Treatment can either be conservative or operative, depending on the severity of the condition.

Case report

A 22-year-old male presented to the emergency department of VS hospital with history of abdominal pain associated with feeling of fullness and bilious vomiting since 5 days. On examination, he was emaciated with a body weight of 45kg.

His vitals are within normal limits.

On examination abdomen was mildly distended in epigastric region and tenderness was present over it.

Laboratory investigations on admission

Hb-18.13Tc-15000Plt-6.8Urea-60Creat-2.30

Trial of conservative management given.

After correction of hydration and normalization of s.creatine

Patient undergone ct scan with angio.

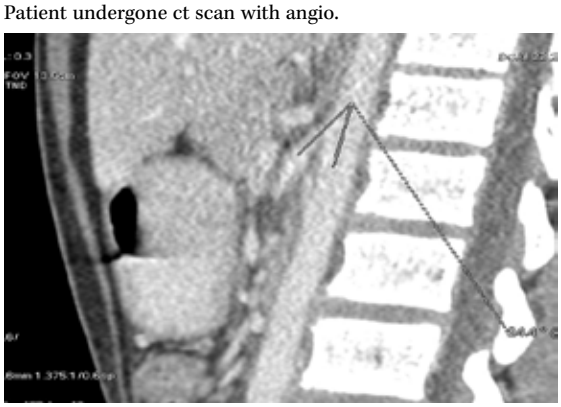

Figure:ct showing narrow angle of SMA

CT angio showing narrow angle of superior mesenteric artery

After failure of conservative management of 4days,the patient was taken for a laparotomy through a midline incision .The stomach was found to be atonic, grossly dilated and reaching down into the pelvis.

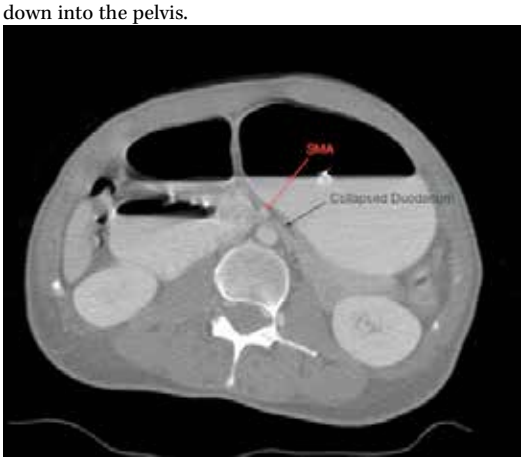

The first and the second parts of the duodenum were also dilated with abrupt narrowing of the duodenum distal to the origin of the superior mesenteric artery.

The duodenum was completely mobilized taking care not to injure the artery. The ligament of Treitz and all adhesions aroundthe arewere divided.

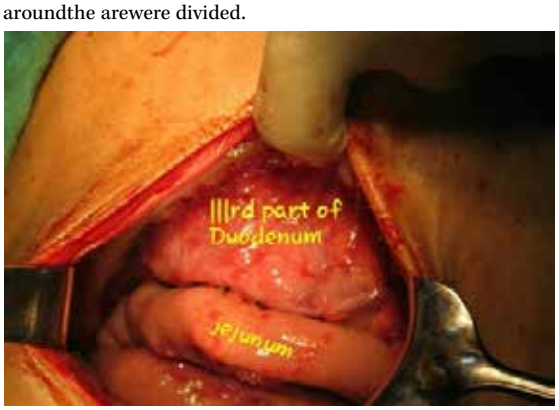

After dissecting 3rd part of duodenum through mesocolon side-

to-side duodenojejunostomy was done.

The patient did well in the post-operative period. A barium meal done on the 7th post-operative day showed no evidence of obstruction or leakage. The patient was discharged in good heath on the 10th postoperative day with a follow-up appointment in the outpatient clinic.

Discussion

The superior mesenteric artery (SMA) arises from the anterior surface of the abdominal aorta, just inferior to the origin of the celiac trunk, and supplies the intestine from the lower part of the duodenum through two-thirds of the transverse colon, as well as the pancreas.

Superior mesenteric artery (SMA) syndrome is a rare cause of upper gastrointestinal obstruction (1). Only 400 cases have been reported in the medical literature (2).

The SMA usually forms an angle of approximately 45° (range, 38-56°) with the abdominal aorta, and the third part of the duodenum crosses caudal to the origin of the SMA, coursing between the SMA and aorta. Any factor that sharply narrows the aortomesenteric angle to approximately 6-25° can cause entrapment and compression of the third part of the duodenum as it passes between the SMA and aorta, resulting in SMA syndrome. There are several factors that can decrease the acuity of the angle between the aorta and SMA; the most common is significant weight loss leading to loss of the mesenteric fat pad. As a result, SMA syndrome has most often been described in patients with severe, debilitating illnesses, such as malignancy or malabsorption syndromes. It has also been described in a variety of other disorders associated with extreme weight loss including anorexia nervosa, trauma or burns, spinal cord injury and paraplegia, and after prolonged bed rest (3-4). Other causes include high insertion of the duodenum at the ligament of Treitz, a congenitally low origin of the SMA and compression of the duodenum caused by peritoneal adhesions, due to duodenal malrotation (5-6).

The syndrome was first described by Von Rokitansky in 1861. He defined it as "a syndrome characterized by intermittent emesis with copious bile-stained material in asthenic people resulting from compression of the duodenum between the aorta and the superior mesenteric artery" (7). It is also known as cast syndrome and arteriomesenteric duodenal compression (8).

Diagnosis depends on high index of suspicion since symptoms can be non-specific. The syndrome usually affects young females (10 to 39 years). The symptomatology is commonly chronic, with epigastric pain, bloating after meals, and vomiting. An acute presentation is uncommon.

The clinical diagnosis can be confirmed by radiologic studies in 95% of cases. Historically, barium meal and arteriography were used as diagnostic tools but more recently, CT, CT-angiography and magnetic resonance imaging (MRI) have been used and shown higher diagnostic sensitivity .

Criteria were established for the diagnosis of SMAS. These criteria include dilatation of the first and second portions of the duodenum, abrupt vertical and oblique compression of the mucosal folds, antiperistaltic flow of barium proximal to the obstruction producing to-and-fro movements, and delay in transit of 4 to 6 hours through the gastroduodenal region.

Arteriographic criteria include a significantly decreased aorto-SMA angle of 6° to 25° (NL=45°) and a shortened aortomesenteric distance of 2 to 8mm (NL=10 to 20mm) (9).

Conservative management is the rule for acute cases . Conservative treatment includes adequate nutrition, G.I. decompression and proper positioning after eating. Prokinetic drugs like metoclopramide or cisapride may be helpful. Surgery is indicated for chronic cases and failure of conservative management. Historically, a gastrojejunostomy was used to treat SMAS. This procedure has largely been abandoned due to associated complications including dumping syndrome, blind loop syndrome, and marginal ulceration. Cleavage of the ligament of Treitz, first described by Strong in 1958 , is another option, enabling the duodenum to drop away from the apex of the sharpened aorto-mesenteric angle and it has been used successfully in many cases. In 1961.

The major advantage of the procedure is the avoidance of a gastrointestinal anastomosis.

The most common operation for SMA syndrome, duodenojejunostomy, was first proposed in 1907 by Bloodgood(10). This open surgery involves the creation of an alternate route between the duodenum and the jejunum, bypassing the compression caused by the AA and the SMA.

Laparoscopic duodenojejunostomy for the management of SMA has also been described in the literature. On July 30, 2008, the world's first robotically-assisted intestinal bypass surgery for a patient with superior mesenteric artery (SMA) syndrome was announced by the London Health Sciences Centre in a 16-year-old girl(11).

Gastroparesis after correction surgery is a frequently encountered problem related to gastric and duodenal atony.

Conclusion

Superior mesenteric artery syndrome (SMAS) is a rare condition caused by compression of the transverse portion of the duodenum between the superior mesenteric artery (SMA) and the aorta. Symptoms are non-specific and the diagnosis depends on high index of suspicion. MRA, being not invasive, is rapidly replacing the arteriogram in confirming the diagnosis. Conservative management may be sufficient in early cases. Duodenojejunostomy is the surgical treatment of choice.

REFERENCE

. Palanivelu C, Rangarajan M, Senthilkumar R, Parthasarathi R, Jani K. Laparoscopic duodenojejunostomy for superior mesenteric artery syndrome. J SocLaparoendoscopic Surgeon 2006; 10: 531-4. | 2. Roy A, Gisel JJ, Roy V, Bouras EP. Superior mesenteric artery (Wilkie's) syndrome as a result of cardiac cachexia. J Gen Intern Med 2005; 20: 3-4. | 3. Pentlow BD, Dent RG. Acute vascular compression of the duodenum in anorexia nervosa. Br J Surg 1981; 68: 665. | 4. Laffont I, Bensmail D, Rech C, et al. Late superior mesenteric artery syndrome in paraplegia: case report and review. Spinal Cord 2002; 40: 88. | 5. Wilkie DPD. Chronic duodenal ileus. Am J Med Sci 1927; 173: 643-649. | 6. Ortiz C, Cleveland RH, Blickman JG, et al. Familial superior mesenteric artery syndrome. PediatrRadiol 1990; 20: 588-589 | 7. Bermas H, Fenoglio ME. Laparoscopic management of superior mesenteric artery syndrome. SLS 2003; 7: 151-153 | 8. Muhammad IA, Jonathan GF. Prolonged gastroparesis after corrective surgery for Wilkie's syndrome: a case report. J Med Case Reports 2008; 2: 109. | 9. Baltazar U, Dunn J, Floresguerra C, Schmidt L, Browder W. Superior mesenteric artery syndrome: An uncommon cause of intestinal obstruction. South Med J 2000; 93: 606-608. | 10. Baltazar U, Dunn J, Floresguerra C, Schmidt L, Browder W. Superior mesenteric artery syndrome: an uncommon cause of intestinal obstruction. South Med J 2000; 93: 606-8. PMID 10881780. | 11. London Health Sciences Center. World's first robotically-assisted intestinal bypass surgery for a patient with superior mesenteric artery syndrome (SMA) syndrome |