ORIGINAL RESEARCH PAPER

Volume-6 | Issue-11 | November-2017 | ISSN No 2277 - 8179 | IF : 4.176 | IC Value : 78.46

INTERNATIONAL JOURNAL OF SCIENTIFIC RESEARCH

A CASE REPORT OF -NON-KETOTIC HYPERGLYCAEMIC HEMIBALLISMUS-HEMICHOREA SYNDROME

Radiodiagnosis

Dr. Zoya M. Patni* Junior Resident III, Department of Radio-diagnosis, Dr. Vasantrao Pawar Medical College Hospital & Research Centre, Nashik, Maharashtra, India, *Corresponding Author

Dr. Rounak R. Bagga Junior Resident III, Department of Radio-diagnosis, Dr. Vasantrao Pawar Medical College Hospital & Research Centre, Nashik, Maharashtra, India

ABSTRACT

Hemichorea-hemiballism (HCHB) is a spectrum of involuntary, continuous non-patterned movement involving single side of the body. We present a case report of a 60 year old male with poorly controlled diabetes showing classical MRI presenting features of Non-ketotic hyperglycaemic hemichorea hemiballismus syndrome. Although it is known to be predominantly seen in the female population we here give a report of these findings in a male patient.

KEYWORDS

Hemichorea hemiballismus (HCHB), Non-ketotic hyperglycaemic (NKH), basal ganglia.

Introduction:

HCHB is a rare manifestation seen in poorly controlled diabetic patients. It is a seldom seen cause of T1 bright signal in basal ganglia and is one of the neurological complications of NKH. The most common cause of HCHB is hemorrhagic or ischemic stroke. Most of the reported cases are seen in people of Asian origin.

Case Report:

The patient came with presenting complaints of abnormal movements of right upper and lower limb with weakness in the right side of the body since 10 days showing progressive worsening of symptoms for 3 days. These movements would increase with actions, decrease with relaxation and disappear during sleep. The patients past medical history revealed that the patient was a known case of type II diabetes mellitus with hypertension. No history of Parkinsonism or other neurologic disorders were reported. Physical examination revealed that the muscle tone and strength was normal on left side with weakness in the right limbs. There was no evidence of sensory impairment and cranial nerve examination was normal. Laboratory tests revealed poorly controlled diabetes mellitus, with a fasting blood glucose level of 420 mg/dL and a hemoglobin A1C level of 17.0%. The urine examination was negative for ketones.

Magnetic resonance (MR) imaging of the brain was performed which revealed on T1weighted imaging a hyperintense signal in the lentiform nucleus (putamen) of the left basal ganglia. T2 weighted imaging showed an isointense signal in the same region and on DWI imaging diffusion restriction was seen.

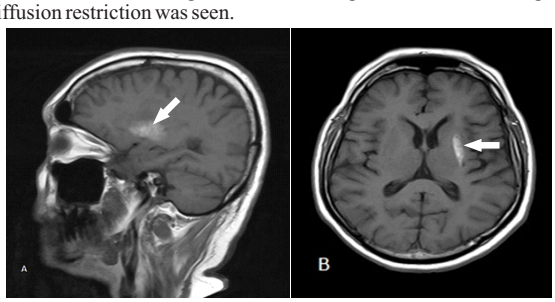

Figure 1: T1 Sagittal (A) and Axial (B) images show T1 hyperintense signal in the lentiform nucleus (putamen) of left basal ganglia (arrows).

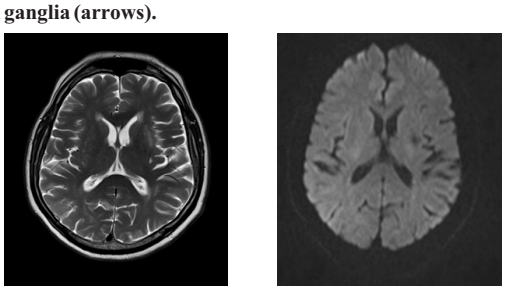

Figure 2 & 3: T2 Axial images (Figure2) shows isointense signal in the lentiform nucleus (putamen) of left basal ganglia (arrows) and DWI (Figure3) shows no diffusion restriction.

Based on these imaging findings the main differential diagnosis which were considered were lenticulostriatre ischemic stroke and Non-ketotic hyperglycaemic hemichorea .

Correlation of the imaging findings was done with the patient's clinical profile, presentation and lab findings. A diagnosis of Non-ketotic hyperglycaemic hemiballismus-hemichorea syndrome was made.

DISCUSSION:

Nonketotic hyperglycemia (NKH) is defined as elevated blood glucose levels in the absence of ketone formation and associated with hyperosmolarity [(1)]. Hemiballism-hemichorea refers to an involuntary, non-rhythmic and poorly patterned movement disorder that involves one side of the body [(2&3)]. The causes of HCHB include hemorrhagic or ischemic stroke, neoplasm, systemic lupus erythematosus, Hyperosmolar hyperglycemic non-ketotic, Wilson's disease, and thyrotoxicosis [(4)]. People of Asian origin seem to be particularly susceptible to hemichoreahemiballism, which suggests a possible genetic predisposition to the disorder [(5)].

In radiology literature, nonketotic hyperglycemia has been associated with a characteristic appearance of unilateral or asymmetric lesions of the basal ganglia which are typically contralateral to the side of the patient's presenting symptoms [(6)].The most commonly described MRI findings associated with nonketotic hyperglycemia include high signal intensity basal ganglia lesions on T1-weighted brain MRI on the side contralateral to patient symptoms [(7)]. MR imaging may also reveal abnormal putaminal signal with or without involvement of the caudate and globus pallidus [(8)]. The T2-weighted findings are much more variable with the majority of BG lesions described as either hypointense or iso-intense to background normal BG [(7)]. Relatively little has been published regarding nonketotic hyperglycemia and findings on DWI and SWI. A small case series and case report have demonstrated mild to moderate restricted diffusion corresponding to the T1-weighted hyperintense BG lesions [(2,9&10)].

The mainstay of treatment is aggressive glycemic control with either partial or complete resolution of hemichorea-hemiballism [(11)]. The basal ganglia hyperintensity generally resolves within a few months, although there has been a case report of persisting striatal hyperintensity on T1-weighted MRI for up to 6 years [(12)]. Case reports in the current medical literature have shown that most patients have dramatically recovered from their hyperkinesia after control of the hyperglycemia was achieved; showing that hemiballism hemichorea caused by hyperglycemia is a treatable disorder with a good prognosis [(13)].

REFRENCES:

1. Rector, W. et al. Nonketotic hyperglycemia appearing as choreoathetosis or ballism. Arch Intern Med 1982; 142: 154-155. 5.

2. Cherian A, Thomas B, Baheti NN, et al. Concepts and controversies in nonketotic hyperglycemia-induced hemichorea: further evidence from susceptibility weighted MR imaging. J Magn Reson Imaging 2009; 29:699–703.
3. Kim H-J, Moon WJ, Oh J, et al. Subthalamic lesion on MR imaging in a patient with non ketotic hyperglycemia-induced hemiballism. AJNR Am J Neuroradiol 2008;29:526–27
4. Padmanabhan S, Zagami AS, Poynten AM: A case of hemichorea-hemiballismus due to nonketotic hyperglycemia. Diabetes Care, 2013; 36(4): e55–e56.
5. Lin JJ, Lin GY, Shih C. Presentation of striatal hyperintensity on T1-weighted MRI in patients with hemiballism-hemichorea caused by non-ketotic hyperglycaemia: report of seven new cases and a review of literature. J Neurol 2001; 248:750-755.
6. Lai PH, Tien RD, Chang MH, et al. Chorea-ballismus with nonketotic hyperglycemia in primary diabetes mellitus. AJNR Am J Neuroradiol 1996; 17:1057-64. PMID: 8791916.
7. Oh SH, Lee KY, Im JH, Lee MS. Chorea associated with non-ketotic hyperglycemia and hyperintensity basal ganglia lesion on T1-weighted brain MRI study: a meta-analysis of 53 cases including four present cases. J Neurol Sci 2002; 200:57-62. PMID: 12127677.
8. Jagota P, Bhidayasiri R, Lang AE. Movement disorders in patients with diabetes mellitus. J Neurol Sci 2012; 314:5–11.
9. Wintermark M, Fischbein NJ, Mukherjee P, Yuh EL, Dillon WP. Unilateral putaminal CT, MR, and diffusion abnormalities secondary to nonketotic hyperglycemia in the setting of acute neurologic symptoms mimicking stroke. AJNR Am J Neuroradiol 2004; 25:975-76. PMID: 15205134.
10. Lee EJ, Choi JY, Lee SH, Song SY, Lee YS. Hemichorea hemiballism in primary diabetic patients: MR Correlation. J Comput Assist Tomogr 2002; 26:905-11. PMID: 12488734.
11. Hwang KJ, Hong IK, Ahn TB et al: Cortical hemichorea-hemiballism. J Neurol, 2013; 260(12): 2986–92.
12. Shan DE, Ho DM, Chang C, Pan HC, Teng MM. Hemichorea hemiballism: an explanation for MR signal changes. Am J Neuroradiol 1998; 19:863-70.
13. Lin JJ, Chang MK: Hemiballism-hemichorea and non-ketotic hyperglycemia. J Neurol Neurosurg Psychiatry, 1994; 57(6): 748–50. Hwang KJ, Hong IK, Ahn TB et al: Cortical hemichorea-hemiballism. J Neurol, 2013; 260(12): 2986–92.