ORIGINAL RESEARCH PAPER

Volume-6 | Issue-9 | September-2017 | ISSN No 2277 - 8179 | IF : 4.176 | IC Value : 78.46

INTERNATIONAL JOURNAL OF SCIENTIFIC RESEARCH

A CASE REPORT ON PULMONARY HYPERTENSION AND PULMONARY FIBROSIS IN A PATIENT WITH SYSTEMIC SCLEROSIS.

Pulmonary Medicine

Ahmar Javed Junior Resident Department of Pulmonary Medicine, Dr. D. Y Patil Medical College Pune(Corresponding Author)

Vinay Dharmadhikari Associate Professor Department of Pulmonary Medicine, Dr. D. Y Patil Medical College Pune

Ela Sharma Junior Resident Department Radio-Diagnosis, Dr D. Y. Patil Medical College Pune

ABSTRACT

Background: Systemic sclerosis is an inflammatory fibrotic disease that results in deposition of excessive extracellular matrix in the skin and several visceral organs including the lungs, heart, kidneys, and gastrointestinal tract. The peak incidence is between the ages of 20 and 60 and is about three times more common in women than men. Pulmonary hypertension and pulmonary fibrosis can be idiopathic or may be due to other diseases, systemic sclerosis can also lead to development of both.

Case Presentation: A 50 years old female presented with progressive breathlessness, chest pain, easy fatigability, dysphagia, short mouth opening and lower limb swelling. On examination patient had sinus tachycardia, raised JVP, pedal odema , loud P2 with pan systolic murmur and bilateral velcro crepitations.

Conclusion: This case illustrates the presentation of pulmonary hypertension and pulmonary fibrosis in systemic sclerosis.

KEYWORDS

Systemic Sclerosis, pulmonary hypertension, pulmonary fibrosis.

INTRODUCTION

Systemic sclerosis is a multisystem disease characterized by fibrosis of the epidermis and dermis (scleroderma), Raynaud's phenomenon and fibrosis of other organs including the kidneys, lungs, heart, gastrointestinal tract and skeletal muscles. It occurs in 5–20 people per million per annum and is about three times more common in women than men. The peak incidence is between the ages of 20 and 60.[1]

Most patients with systemic sclerosis and the CREST variant ultimately develop lung involvement [2,3]. Pulmonary fibrosis presents as gradually increasing dyspnoea. Cough is rarely an important symptom. Bilateral inspiratory crackles are often present but their absence is not inconsistent with the diagnosis. The radiograph shows fine irregular, predominantly basal, fibrosis. As in idiopathic fibrosis, CT allows estimation of the extent and to some degree the stage of the disease[4,5].

In contrast to pulmonary fibrosis, pulmonary hypertension is a very serious and progressive complication of systemic sclerosis particularly in CREST syndrome . The patient presents with breathlessness, but this tends to be rapidly progressive. There may be crackles in the lungs, although often there are no signs. Evidence of pulmonary hypertension, such as right ventricular heave and gallop rhythm and large jugular a waves, may be present.

The lungs may look normal or avascular and the main pulmonary arteries may be dilated. The ECG shows evidence of right ventricular preponderance. Lung function testing shows a lowered DLCO. Such patients are very likely to have the antinuclear antibody anti-Scl 70, perhaps indicative of a general tendency towards vascular damage. Pulmonary hypertension in systemic sclerosis portends a particularly bad prognosis. The patients develop cor pulmonale and most are dead within 3 years[6,7].

CASE.PRESENTATION

A 50 years old female with recurrent admissions presented with complaints of progressive breathlessness grade III MMRC, chest pain, easy fatigability since two years. Patient also had complaints of dysphagia, short mouth opening and lower limb swelling since one year(Figure 1).



Figure1: Short mouth opening with pinched nose.

On examination- Her skin appeared tight, had sinus tachycardia, respiratory rate was 24/min, JVP was raised with pedal odema present. Peripheral oxygen saturation assessed by pulse oximetry 88% during rest, without oxygen supply.

Cardiac auscultation-loud P2 with pan systolic murmur over tricuspid region.
On Respiratory auscultation- bilateral Velcro crepitations over infra scapular region. Other systemic examination was normal.

Electrocardiogram (ECG) showed sinus tachycardia, right axis deviation with right ventricular hypertrophy and P pulmonale with global T wave inversion. (Figure 2)

2D Echo showed inferior wall hypokinesia ,
LVEF- 40%, early diastolic dysfunction, dilated RA and RV, mild tricuspid regurgitation, dilated pulmonary artery with severe pulmonary hypertension (RSVP=78mmHg).

Spirometery showed restrictive pattern with reduced DLCO.

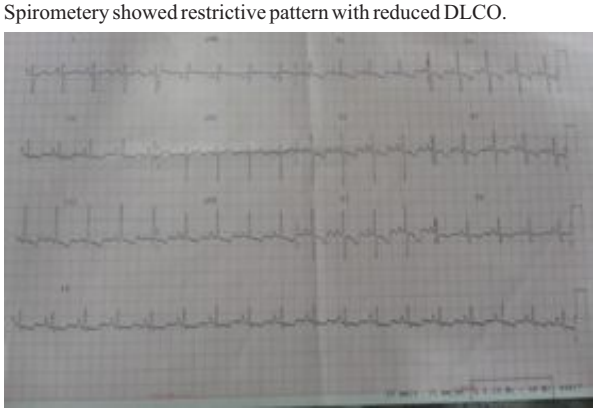

Figure 2: ECG showing right ventricular hypertrophy with P pulmonale and global T wave inversion.

Chest radiograph was normal. HRCT showing showing bibasilar,sub pleural septal thickening with traction bronchiectasis. Suggestive of Non Specific Interstitial pneumonia(NSIP) and dilated pulmonary artery(Figure3).

Immune serology was positive for IgE & anti-nuclear antibodies

(ANA) with increased levels of ant-SCL-70 levels and ant- RNP antibodies.

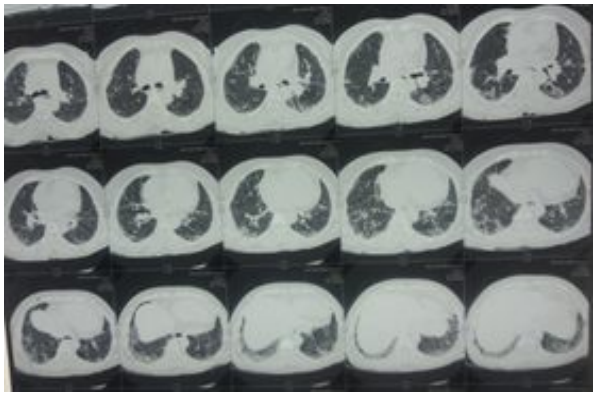

Figure 3 : HRCT showing bibasilar,sub pleural septal thickening with traction bronchiectasis. Suggestive of Non Specific Interstitial pneumonia (NSIP) .

She was commenced on intermittent oxygen at 2L/min, diuretics (torsemide 10 mg bd), endothelin receptor antagonist (bosentan 62.5 mg bd), phospodiesterase inhibitors (sildenafil 20 mg tds), cyclophosphamide 50mg bd and median dose oral steroids (prednisone 30mg od) and has symptomatically improved.

DISCUSSION

Systemic sclerosis is a chronic connective tissue

disease that typically affects skin and internal organs by widespread micro vascular damage and excessive deposition of collagen[8]

Interstitial lung disease, pulmonary hypertension, pleuritis, pleural effusion and aspiration pneumonia are the pulmonary manifestations of systemic sclerosis[9]

In terms of race/ethnicity, African-Americans have been reported to have earlier onset and more severe disease[10].In north India it is reported the prevalence of antinuclear antibody (ANA) positive autoimmune disorders. They reviewed ANA-positive files from 1996 to 2006 and did a retrospective analysis of the cases, including both adults and children. They reported a prevalence of systemic sclerosis at 120 cases per million. They included another subgroup of cases as connective tissue disease overlap as 70 cases per million and Raynaud's disease as 50 cases per million[11].

Although survival rates have improved over time, pulmonary fibrosis and pulmonary hypertension continue to be the leading causes of systemic sclerosis related deaths.New classification criteria for systemic sclerosis, jointly drafted by the American College of Rheumatology (ACR) and the European League Against Rheumatism (EULAR), are not only more sensitive than older ACR criteria but will also enable faster and more accurate diagnosis of scleroderma, a collaborative study finds.

Criteria that are more specific will allow for earlier identification and better treatment for those with systemic sclerosis.

Validation testing of the new classification criteria finds that skin thickening of the fingers (extending proximal to the metacarpophalangeal joints) alone is sufficient for a patient to be classified as having scleroderma.

- If that single key sign is absent, seven other factors should be assessed to make a classification of scleroderma, according to the criteria:
- General skin thickening of the fingers
- Raynaud's phenomenon
- Fingertip lesions
- Telangiectasia
- Abnormal nailfold capillaries
- Interstitial lung disease or pulmonary arterial hypertension
- The presence of Systemic sclerosis related autoantibodies[12].

CONCLUSION

This case report assert the fact that pulmonary complications in systemic sclerosis may have severe clinical implications. Certainly HRCT, 2D- echo & immune serology have huge role in the diagnosis but a careful physical examination is of prime importance also.

Despite the fact there is no absolute cure but early diagnosis and treatment can reduce the morbidity & mortality.

REFERENCES:

[1] Rocco VK, Hurd ER. Scleroderma and scleroderma-like syndromes. Semin Arthritis Rheum1986;16:22.
[2] Steen V, Owens G, Fino G et al. Pulmonary involvement in systemic sclerosis (scleroderma).Arthritis Rheum1985;28:759.
[3] D'Angelo WA, Fries JF, Masi AT, ShulmanLE. Pathologic observations in systemicsclerosis (scleroderma). Am J Med 1969; 46:428.
[4] Wells AU, Hansell DM, Rubens MB et al.Fibrosing alveolitis in systemic sclerosis:indices of lung function in relation to extentof disease on computed tomography. ArthritisRheum 1997; 40: 1229 .
[5] Chan TW, Hansell DM, Rubens MB, du BoisRM, Wells AU. Cryptogenic fibrosing alveolitis and fibrosing alveolitis of systemic sclerosis: morphological differences on computed tomographic scans. Thorax 1997; 52:265 .
[6] Stupi A, Steen V, Owens G et al. Pulmonaryhypertension in the CREST syndromevariant of systemic sclerosis. Arthritis Rheum1986; 29: 515.
[7] Steckel RJ, Bein ME, Kelly PM. Pulmonaryarterial hypertension in progressive systemicsclerosis. Am J Roentgenol 1975; 124:461.
[8] HinchcliffM, Varga J Systemic sclerosis/scleroderma: a treatablemultisystem disease. Am Fam Physician 2008;78:961-8.
[9] Owens GR, Follansbee WP. Cardiopulmonary manifestations of systemic sclerosis. Chest 1987; 91: 118-127.
[10] Nashid M, Khanna PP, Furst DE,et al.; investigators of the D-penicillamine, human recombinant relaxin and oral bovine type I collagen clinical trials. Gender and ethnicity differences in patients with diffuse systemic sclerosis: analysis from three large randomized clinical trials. Rheumatology (Oxford) 2011; 50: 335–342.
[11] Minz RW, Kumar Y, Amand S, et al. Antinuclear antibody positive antibody disorders in North India: an appraisal. Rheumatol Int 2011. PMID: 21898056 [Epub ahead of print].
[12] Van den Hoogen F, Khanna D, Fransen F, et al. 2013 Classification Criteria for Systemic Sclerosis: An American College of Rheumatology/ European League Against Rheumatism, Arthritis & Rheumatism (2013) doi: 1002/art.38098 First published online: October 3, 2013.