ORIGINAL RESEARCH PAPER

Volume-7 | Issue-1 | January-2018 | PRINT ISSN No 2277 - 8179

INTERNATIONAL JOURNAL OF SCIENTIFIC RESEARCH

A CASE SERIES ON SECONDARY AMENORRHEA DUE TO PITUITARY ADENOMAS AND ITS MANAGEMENT

Gynaecology

Dr. Nimrata Paul* Post Graduate in MS OBG *Corresponding Author

Dr. Jameela C Professor OBG

Dr. Joylene D' Almeida Assistant Professor OBG

ABSTRACT

INTRODUCTION: There are many potential causes of pituitary-associated amenorrhea. Pituitary causes of amenorrhea constitute 18% of cases of secondary amenorrhea and 7% of cases of primary amenorrhea.

BACKGROUND:

CASE 1: 28 years old nulligravid female came with secondary amenorrhea, galactorrhea, headache and disturbed vision with acromegaloid facies. Hormonal Workup revealed prolactin level of 65 ng/ml and MRI brain shows 1.9 x 1.1 x1.9 cm lesion in the sellar and suprasellar area.

CASE 2: 22 years old nulligravid female presented with secondary amenorrhea with h/o generalized weakness, headache, and diabetes mellitus, with acromegaloid facies. Work up reveals normal serum prolactin (14 ng/ ml), MRI brain revealed 2.4 x 2 x 2.3 cm lesion causing widening of sella, extending into suprasellar region with extension into ICA.

CASE 3: 27 years old nulligravid female presented with irregular menstrual cycles, galactorrhea with headache and diplopia. Work up reveals prolactin level of 157 ng/ml and MRI brain showed 6x4 mm lesion in the right half of pituitary gland with pituitary stalk displaced to the left.

CASE 4: 28 year old woman, gym trainer, oligomenorrheic until the age of 18 years, when she was started on oral contraceptives. At the age of 28 years, she stopped the OCPs in order to attempt to become pregnant.3 months after discontinuing the OCPs, she remained amenorrheic. Work-up revealed prolactin 45 ng/ml, low-normal FSH and LH, low estradiol level of 30 pg/ml. Pituitary-protocol MRI demonstrated a 3mm hypodense lesion on the right side of the pituitary gland, consistent with a pituitary adenoma.

CASE 5: 24 years old nulligravid female presented with h/o oligomenorrhea since 5 years. Work up reveals serum prolactin 120 ng/ml, normal LH, FSH. MRI brain revealed 5mm area of persistent delayed enhancement right side of the pituitary gland, suggestive of microadenoma.

CASE 6: 35 years old female presented with secondary infertility with h/o oligomenorrhea since 5 years. Work up reveals serum prolactin 150 ng/ml, low normal LH, FSH. MRI brain revealed 8mm lesion in the right side of the pituitary gland, consistent with microadenoma.

MATERIAL AND METHODS: Patients who presented with secondary amenorrhea and diagnosed with pituitary adenomas, at FMMCH, Mangalore, and treated for the same as either outpatients or inpatients.

RESULTS: Based on clinical examination, lab reports and MRI findings, diagnosis of growth hormone secreting pituitary macroadenoma was made for CASE 1 AND 2, and non functional pituitary microadenomas was made for CASE 3,4,5,6. One of the Macroadenomas was successfully operated and symptoms subsided, whereas other one was lost to follow up. All microadenomas were successfully managed medically, with return of menstrual cycles with anti-prolactin therapy.

CONCLUSION: Pituitary causes of amenorrhea should be considered in women with low or normal gonadotrophin levels. Therapy for pituitary adenomas depends on the specific type of tumour, and should be managed with a team approach to include endocrinology and neurosurgery when indicated.

KEYWORDS

Secondary amenorrhea, growth hormone secreting adenoma, non functional pituitary adenoma

INTRODUCTION:

Pituitary causes of amenorrhea constitute 18% of cases of secondary amenorrhea and 7% of cases of primary amenorrhea(1). Pituitary causes of amenorrhea should be considered in women with low or normal gonadotropin levels. Hyperprolactinemia is the most common cause of pituitary amenorrhea, comprising 15% of all cases of secondary amenorrhea and 80% of pituitary cases of secondary amenorrhea(2). Various causes for pituitary associated amenorrhea are hyperprolactinemia - which can be physiological or pathophysiological-- prolactinomas being the most common, other causes like non-lactotroph adenomas and sellar masses, sheehan's syndrome, infiltrative and infectious causes, iatrogenic causes, genetic causes.

MATERIAL AND METHODS: Patients who presented with secondary amenorrhea and diagnosed with pituitary adenomas, at FMMCH, Mangalore, and treated for the same as either outpatients or inpatients.

OBJECTIVES:

- To evaluate secondary amenorrhea and how to diagnose pituitary associated amenorrhea.
- To initiate appropriate treatment depending on the type of pituitary adenoma

CASE STUDIES

	CASE 1	CASE 2	CASE 3	CASE 4	CASE 5	CASE 6
AGE years	28	22	27	28	24	35
PARITY	unmarried	nulliparous	unmarried	nulliparous	nulliparous	Para 1
CHIEF COMPLAINT						
➢Galactorrhea	X 1 year	x 4 months	x 2 years	---	---	---
➢Irregular cycles	+	+	+	+	+	+
➢Secondary amenorrhea	X6 months	x 2 years	x6months	X 3months	X 3 months	X5 months
➢ Headache	+	+	+	--	--	--
➢Disturbed vision	+	+	+	--	--	--
➢Hoarseness of voice	--	+	--	--	--	--
➢Primary infertility		+		+	+	secondary infertility
MENARCHE	13 years	15 years	13 years	15 years	12 years	13 years

ON EXAMINATION

	CASE 1	CASE 2	CASE 3	CASE 4	CASE 5	CASE 6
BP mm/Hg	160/100	140/100	110/80	120/80	110/70	110/80
ACROMEGALOID FACIES	+	+	--	--	--	--
VISUAL FIELD	Bitemporal hemianopia +	Intact to confrontation	Intact	Intact	Intact	Intact
FUNDUS EXAM	Left eye : superior NRR thinning	Normal	Normal	Normal	Normal	Normal

INVESTIGATIONS

	CASE 1	CASE 2	CASE 3	CASE 4	CASE 5	CASE 6
S. PROLACTIN ng/ml	79	13.7	157.4	45	120	150
S. HCG	--	--	--	--	--	--
LH mIU/L	0.4	0.10	4.7	5	6.8	0.5
FSH mIU/mL	2.34	0.39	5.6	3	7.78	1.45
S. TSH	1.09	1.37	1.51	1.3	1.6	2.4
S. fT4 ng/dl	0.99	1.6	1.04	1.2	1.2	1.67
GROWTH HORMONE (ng/ml)	6.31	12	--	--	--	--
S. CORTISOL (nmol/L)	185	158	109	--	--	--
IGF-1 (ng/ml)	667	690	--	--	--	--
FBS mg/dl	134	300	98	--	96	98
AMH	-	5	--	--	--	--

CASE 1:



ACROMEGALOID FACIES



ACRAL CHANGES



Large lips and nose, pronounced jaw and underbite.

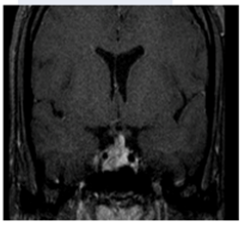

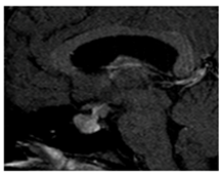

Sellar and suprasellar lesion 1.9 x 1.1 x 1.9 cm ; superiorly, abutting optic chiasm

S/O PITUITARY MACROADENOMA

CASE 2:

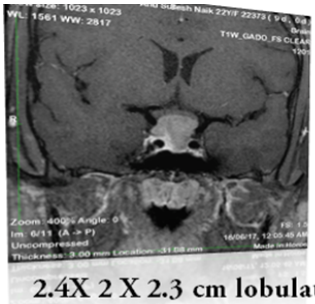



2.4X 2 X 2.3 cm lobulated lesion in sellar and suprasellar region with extension into ICA :

PITUITARY MACROADENOMA

CASE 3

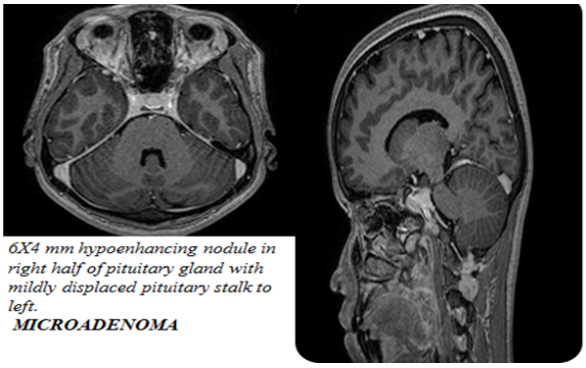

6X4 mm hypoenhancing nodule in right half of pituitary gland with mildly displaced pituitary stalk to left.

MICROADENOMA

RESULTS:

Case1: Diagnosis of Growth hormone secreting MACROADENOMA was made. She was started on OHAs, insulin and antihypertensives for hyperglycemia and hypertension, respectively. She was adviced surgery-- *trans-sphenoidal resection of pituitary adenoma*, but did not follow up.

Case 2: Diagnosed as Growth hormone secreting MACROADENOMA. She was adviced surgery and mean time she was started on Tab. Progynova 2 mg OD X 30 days + Tab Primolut N 5mg BD X 10 days. Hypothyroidism was corrected with Tab Thyronorm 50 mcg OD. She was started on OHAs, insulin and antihypertensives for hyperglycemia and hypertension, respectively.

Underwent trans nasal trans-sphenoidal resection of pituitary adenoma. Post-operatively her menses resumed and eye symptoms improved.

Case 3: Diagnosed as non functional pituitary adenoma. She was started on low dose anti prolactin therapy--Tab Cabergoline 0.25 mg/ biweekly. Periods resumed within 2 months, headache, galactorrhea and eye symptoms subsided.

Case 4: Diagnosed as non functional pituitary adenoma. This patient illustrates the importance of checking a prolactin level and performing pituitary imaging even when many aspects of the initial presentation are suggestive of hypothalamic amenorrhea due to exercise. She was started on Tab. Cabergoline 0.25 mg/ biweekly. Prolactin level rapidly normalized after 2 months and she conceived after 3 months.

Case 5: Diagnosed as non functional pituitary adenoma. She was started on Tab. Cabergoline 0.25 mg/ biweekly. Cycles resumed after 2 months of medication and prolactin level normalized. She conceieved after 3 months.

Case 6: Diagnosed as non functional pituitary adenoma. She was started on Tab. Cabergoline 0.25 mg/ biweekly. Prolactin level normalized after 1 month of treatment and cycles resumed after 3 months. Repeat MRI done after 3 months showed decrease in size of tumour by 6mm. She conceived with 2 cycles of ovulation induction with clomiphene citrate.

DISCUSSION:

Pituitary adenomas can be non-functioning or hyperfunctioning i.e., prolactinomas, corticotroph adenomas (Cushing's disease), somatotroph adenomas (acromegaly), somatomammotroph adenomas (adenoma which co-secretes prolactin and growth hormone), thyrotroph adenomas (excess TSH secretion) and pleurihormonal adenomas (rare). Microadenomas are pituitary tumours less than 10 mm in size and may cause focal bulging while macroadenomas are more than 10 mm, cause problems due to mass effect. Amenorrhea is a common finding in Cushing's disease, usually due to increased circulating androgens made by the adrenal gland. In acromegaly, amenorrhea may result from hyperprolactinemia, either due to concomitant production of prolactin by the tumor or stalk compression, compression of the pituitary gonadotrophs, or hyperandrogenism.

DIAGNOSIS:

Clinical Findings:

- ***Reproductive Dysfunction—***

Hyperprolactinemia causes hypogonadotropic hypogonadism. In ovulatory cycles with hyperprolactinemia, infertility is due to a shortened luteal phase [3,4].Trial of treatment for hyperprolactinemia should be given prior to initiating more aggressive treatments for infertility.

Galactorrhea

- ***Bone Loss due to hypo-estrogenemia.***
- ***CNS Disturbances: May indicate a rapidly expanding tumour or a tumour which is impinging on the optic chiasm. Visual field testing should be done immediately and dopamine agonist therapy should be initiated.***

LAB STUDIES:

In the absence of symptoms or signs suggesting excess of specific hormones, the most cost-effective strategy is simply measurement of the prolactin level. If clinical suspicion of cushing syndrome, acromegaly, or other hormone excess exists, order appropriate tests. Because excess growth hormone secretion may not produce the clinical phenotype in all cases, especially if early in the course, a serum insulin like growth factor-1 (IGF-1) level is recommended in all cases.

Screening tests for Cushing syndrome, such as overnight dexamethasone suppression test, 24-hour urinary free cortisol, or midnight salivary cortisol are usually not routinely performed unless there is clinical suspicion for this disorder. Autonomous secretion by a tumour usually shows an inappropriate relationship between the level of the hormone secreted by the peripheral gland (thyroid, adrenal, gonadal) and the stimulating pituitary hormone (thyroid-stimulating hormone [TSH], corticotropin, gonadotropins).

IMAGING:

MRI studies have shown sensitivity and specificity of about 90% for secretory tumors. Enhancement with gadolinium diethylenetriaminepentaacetic acid (DTPA) improves the detection rate. Sensitivity for detection of corticotropin-secreting adenomas is much less (60-75%); diagnosis may require specialized tests such as petrosal sinus sampling. MRI showing a non enhancing area in the pituitary: Consistent with a microadenoma in a patient with hyperprolactinemia. Computed tomography (CT) scans are not very specific or sensitive for microadenomas.

OTHER TESTS:

Other tests are dictated by the clinical picture of hormonal excess or, very rarely, hormonal deficiency. For larger functional microadenomas, especially those located in an area where upward pressure on the optic chiasm may exist, assessment of visual fields may be useful in monitoring therapy. Computer-assisted perimetry may be more sensitive than Goldman perimetry. In contrast to pituitary macroadenomas, microadenomas rarely cause any visual-field defects.

MANAGEMENT : Microprolactinomas

Not associated with hypogonadism, menstrual irregularity, infertility, or disruptive galactorrhea	DONT require treatment but should be observed with a pituitary-protocol MRI and serum PRL levels every 1 to 2 years, as the risk of progression to a macroadenoma is less than 10 percent
Treatment should be initiated if tumour growth occurs	Dopamine agonists. Cabergoline has been shown to achieve normal prolactin levels and ovulatory cycles, fewer side effects than bromocriptine therapy[5].

FOLLOW UP:

- Further Outpatient Care: Natural history for nonfunctioning microadenomas appears to be benign.Follow-up MRI scans can be performed at 12 months to assess progression, but generally they are not needed for most microadenomas. For nonsecreting adenomas, follow-up is usually not needed unless clinical symptoms arise. If the tumour enlarges, full endocrine testing and therapy are justified. There is tumour enlargement in 10%, decreased size in 10%, and no change in 80% of microadenomas[6]
- Inpatient & Outpatient Medication: Required if the tumour is secreting excess hormone. Appropriate medical therapy has to be initiated for hyperprolactenemia, acromegaly and cushing's disease.

Complications : Caused by the rare enlargement of the tumour to a macroadenoma or by excessive hormone secretion(7). Inactive microadenomas rarely cause complications unless they are pressing on the pituitary stalk.

Prognosis: Depends on the hormonal activity of the adenoma. A meta-analysis showed that microadenomas rarely enlarge (3.3 per 100 patient-years (8)

CONCLUSION:

A thorough history and physical examination are invaluable in trimming down the differential diagnosis when evaluating a woman with amenorrhea. It is recommended to do serum prolactin level as part of the work-up in any woman with primary or secondary amenorrhea. If the value is <50 ng/ml but is elevated above the normal range, repeat the measurement to ensure that the elevation is chronic and not due to a transient cause. In amenorrhea of unknown cause, where serum FSH is not elevated, a pituitary-protocol MRI should be part of the initial diagnostic work-up. Therapy for pituitary adenomas depends on the specific type of tumour, and should be managed with a team approach to include endocrinology and neurosurgery when indicated. Dopamine agonists are the primary treatment for prolactinomas. Small non-functioning adenomas and prolactinomas in asymptomatic patients do not require immediate intervention and can be observed. Secretory tumors are best removed by the transsphenoidal approach.

REFERENCES:

1. Reindollar RH, et al. Am J Obstet Gynecol. 1981; 140:371-80.
2. Clayton RN, et al. J Clin Endocrinol Metab. 2011; 96(3):632-42.
3. Corenblum B, Pairaudeau N, Shewchuk AB (1976) Prolactin hypersecretion and short luteal phase defects. Obstet Gynecol 47:486–488
4. Seppala M, Ranta T, Hirvonen E (1976) Hyperprolactinaemia and luteal insufficiency. Lancet 1:229–230
5. Webster J, Piscitelli G, Polli A, Ferrari CI, Ismail I, Scanlon MF (1994) A comparison of cabergoline and bromocriptine in the treatment of hyperprolactinemic amenorrhea. Cabergoline Comparative Study Group. N Engl J Med 331:904–909
6. Molitch ME. Management of incidentally found nonfunctional pituitary tumors. Neurosurg Clin N Am. 2012 Oct. 23(4):543-53.
7. Sherlock M, Ayuk J, Tomlinson JW, Toogood AA, Aragon-Alonso A, Sheppard MC. Mortality in patients with pituitary disease. Endocr Rev. 2010 Jun. 31(3):301-42.
8. Fernandez-Balsells MM, Murad MH, Barwise A, et al. Natural history of nonfunctioning pituitary adenomas and incidentalomas: a systematic review and metaanalysis. J Clin Endocrinol Metab. 2011 Apr. 96(4):905-12.