Volume : 2 | Issue : 7 | July 2013 • ISSN No 2277 - 8179

Research Paper

Medical Science

KEYWORDS : Sirus nail, morbidity, unstable, diaphyseal fractures

A Clinical Study of Sirus Nail in Femoral Diaphyseal Fractures

Dr Chandra Prakash Pal	Assistant Professor and head, Department of orthopaedics, S.N. Medical College Agra
Dr Awak Varun Mittal	Lecturer, Department of orthopaedics, S.N. Medical College Agra
Dr Karuna Shankar Dinkar	Senior Resident, Department of orthopaedics, S.N. Medical College Agra

ABSTRACT

Fractures of the shaft of the femur are a major cause of morbidity and mortality in patients with lower extremity injuries. Interlocking intramedullary nailing is currently considered to be the treatment of choice for most femoral shaft fractures. 14 patients of unstable femoral shaft fractures were treated by Sirus nail to evaluate the long term pain, mobility and stability after implantation of Sirus nail in femoral diaphyseal fractures along with it's functional outcome, morbidity and complications. Out of 14 cases 13 were male and 1 female. 85% of patients were operated within 10 days of injury. According to Ray sanders et al (1991) criteria 12 cases were in excellent category and 2 had good results. We can conclude that the Sirus nail has emerged recently as a miracle third generation intramedullary locking implant, particularly for unstable displaced diaphyseal femoral fracture.

Introduction

Fractures of the shaft of the femur are a major cause of morbidity and mortality in patients with lower extremity injuries. With the exception of fractures through pathologic bone, violent forces are needed to create these fractures. Disability usually results from fracture shortening, fracture malalignment, or prolonged immobilization of the extremity. Even minor degrees of shortening and malalignment can eventuate in a limp and post-traumatic arthritis. Therefore, the art of femoral fracture care is a constant balancing of the often conflicting goals of anatomical alignment and early functional rehabilitation of the limb. Since 50 years ago and Kuntscher's pioneering work on IM fixation, many refinements have been made in nailing techniques and the implants used. However, the basic concepts of Kuntscher's description remain unchanged. Interlocking intramedullary nailing is currently considered to be the treatment of choice for most femoral shaft fractures. Regardless of the method of treatment chosen, the following principles are agreed upon: restoration of alignment, rotation, and length; preservation of the blood supply to aid union and prevent infection; and rehabilitation of the extremity.

Sirus Nail , the ingenious comprehensive system is designed for variety of indications for reamed and unreamed intramedullary femoral and tibial surgical techniques. Femoral and tibial instrumentation is provided in a single, easily accessible tray. The sirus femoral intramedullary nails stands out for it's anatomically optimized design. The antecurvature of nail differs depending on the length of the femur. Minimally invasive introduction of the implant over the greater trochanter is possible.

The dynamic and static locking options in proximal regional as well as additional possibility of insertion of upto three cervical screws facilitates the stabilization of complex fractures and fracture close to the joint as well as treatment of femoral shaft fracture combined with femoral neck fracture. The present study was aimed to evaluate the long term pain, mobility and stability after implantation of Sirus nail in femoral diaphyseal fractures it's functional outcome, morbidity and complications

Material & Methods

The cases for this study have been selected from the patients attending the out patient, department of Orthopaedics and from those arriving at the emergency department of S.N. Medical College, Agra. Each patient was subjected to clinical and radiological examination along with routine pathological investigations.

CRITERIA FOR SELECTION OF CASES

All patients above the age of 18 years with fractures of diaphyseal femur were selected for the study regardless of age except for:

(a) Those with inability to walk (recumbent position)
(b) Compound fractures
(c) Unstable neighbouring skin, infected abrasions, blebs, burns or bedsores.
(d) Very poor anesthetic and general risk patients.

Sirus Cap Screw:

These are cannulated screw for their easier placement, available in six different sizes ranging from 0 to 25 mm in length and if required they can be used to extend the length of femoral intramedullary nail.

Operative technique

After giving appropriate anaesthesia, the patient is positioned on the fracture table and the fracture is reduced with the leg adducted. About 3 cm long incision is made just proximal to the tip of greater trochanter. The entry point was made at the tip of greater trochanter with bone awl. A guide wire is introduced into femoral shaft through entry point. Proximal reaming was done by cannulated hand reamer. Open reduction was performed only in cases where closed reduction failed or grossly unacceptable. Nail and zig was assembled and inserted into femur by hand. A guide wire was passed into the neck and the position was checked. The two proximal dynamic and static locking is done with the help of zig using drill bit with sleeve. In case of ipsilateral fracture neck of femur targeting module for cervical screws are added to the zig and three screws are placed in the head with the help of zig under image guidance. In case of sub-trochantric fractures two cervical screws are placed in the neck and static proximal locking is done. Finally the fracture site is compressed and locking of distal dynamic or static holes was done with the free hand technique to maintain rotational stability. In case of supracondylar fracture additional locking besides these locking screws, is done through the additional holes provided at the distal end of the nail.

Post operative management:

- Intra venous antibiotics were given for 4 - 5 days and then oral antibiotics were given.
- The limb was kept in 15 degree flexion and 20 degree abduction with the aid of a pillow.
- Patient was encouraged to sit on next postoperative day.
- Quadriceps exercise was encouraged as soon as patient was in a position to tolerate it.
- Partial weight bearing with the help of walker was started after 5 -6 days.
- Skin stitches were removed at the 12th postoperative day.
- After removal of stitches the patient was discharged, with instruction to keep the limb in the explained position.

Follow up study:

This was done at regular intervals of one month for first six

Volume : 2 | Issue : 7 | July 2013 • ISSN No 2277 - 8179

months and then at 3 monthly intervals till the union is achieved clinically and radiologically.

Clinical assessment :
- Presence or absence of pain.
- Movement at the hip and knee joint .
- Limb length discrepancy
- Deformity
- Gait and weight bearing

RADIOLOGICAL EXAMINATION:
- Union at fracture site.
- Migration of proximal screws
- Any change in neck-shaft angle.
- Shortening.

Results were assessed according to Ray sanders et al criteria (1991). They are divided in four grades

Excellent	-	36-40 points
Good	-	26-35 points
Fair	-	16-25 points
Poor	-	0-15 points

These points in the grades are sum of digits allotted to various functional components mentioned below:

	Results	Points
Range of motion at knee joint:		
Flexion (degrees)		
>125	Excellent	6
100-124	Good	4
90-99	Fair	2
<90	Poor	0
Extension Lag (degree)		
0	Excellent	3
< up to 5	Good	2
6-10	Fair	1
>10	Poor	0
Pain		
None	Excellent	10
Occasional or with change in weather or both	Good	7
With fatigue	Fair	5
Constant	Poor	0
Deformity		
Angulation (degrees)		
0	Excellent	3
<10	Good	2
10-15	Fair	1
>15	Poor	0
Shortening (cms)		
0	Excellent	3
<1.5	Good	2
1.5-2.5	Fair	1
>2.5	Poor	0
Walking abilities (minutes)		
Walking Unrestricted	Excellent	6
>30 min to <60 min	Good	4
<30 min	Fair	2
Walk at home, is confined to wheel chair or is bed ridden	Poor	0
Stair Climbing		
No limitation	Excellent	3
Hold rails	Good	2
One stair at a time	Fair	1
Elevator only	Poor	0
Return to work (either A or B)		
A. Employed before injury		
• Returned to pre injury job	Excellent	6
• Returned to pre injury job **with difficulty**	Good	4
• Altered full time job	Fair	2
• Part time job or unemployed	Poor	0
B. Retired before injury		
• Returned to pre injury life style	Excellent	6
• Needs occasional help with shopping or laundry	Good	4
• Need assistance at home with activities of daily living	Fair	2
• Moved in family or moved for nursing home	Poor	0

Discussion

Medullary nailing is the treatment of choice for all femoral fractures from lesser trochanter to10 centimeters above the knee joint. Concepts of management of trauma in orthopaedics are very rapidly changing to keep pace with the increasing severity and complexities of the fractures. The management of unstable femoral shaft fracture is always a challenging problem to a orthopaedic surgeons, as they are very frequently associated with high grade soft tissue injury, leading to complications like shortening, malunion, problems of soft tissue healing, infection, delayed union, non union and joint stiffness. Proximal-third, distal-third and unstable fractures are at higher risk for malangulations.

The aim of treatment in these fractures is to achieve length and alignment and produce favorable environment for bone and soft tissue healing. Stambough JL et al in 1991 showed results of 99 cases of stable and unstable fractures by interlocking nail .He showed that despite minor complications and technical problems, the procedures resulted in union with acceptable alignment in 98% of case. Bucholz RW et al in 1987 showed in their study that for distal third femoral fractures, where there is not effective contact between the cortex and the nail, two cross-locking screws are necessary for adequate stability

In our series average age was 36.8 yrs. Most of the patients (35.71%) were between 20-30 yrs age. This is because persons of this age group are more exposed to road traffic accident and other mode of trauma which are the commonest cause of femoral shaft fracture. Out of 14 cases, 5 (35.71%) cases were oblique, 1(7.14%) were spiral and 8 (57.14%) cases were that of comminuted fractures. Intramedullary nailing allows early mobilization with minimal scaring of thigh musculature, and early functional recovery can be expected. In our study out of 14 cases in 11 cases partial weight bearing was allowed within 24 hours after operation. While in 3 cases weight bearing was allowed 2 months after operation because of bicortical comminution

Full weight bearing was however started only after clinical and radiological evidence of union. Physiotherapy of hip and knee joints was encouraged throughout the entire post operative period. This rapid mobilization and speedy healing leads to obvious economic benefits for the patient

Conclusion

We can conclude from study that the Sirus nail has emerged recently as a miracle third generation intramedullary locking implant, particularly for unstable displaced diaphyseal femoral fracture. The rapid mobilization and speedy healing leads to obvious economic benefits for the patient



Figure 2



Figure 3

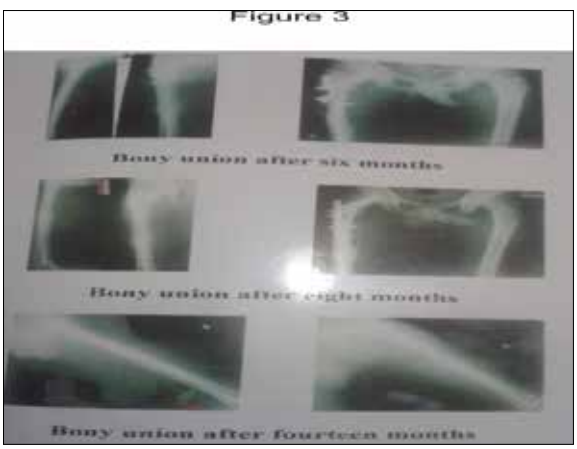

Figure 4



REFERENCE

1-Benirschke SK, Melder I, Henley MB, et al; Closed interlocking nailing of femoral shaft fractures: assessment of technical complications and functional outcomes by comparison of a prospective data¬base with retrospective review, J Orthop Trauma 7:118, 1993. | 2 -Stambough JL, Hopson CN, Cheeks ML- Stable and unstable fractures of the femoral shaft.1991 Oct;20(10):855-61. | 3-Whittle AP, George W. Wood II , fractures of lower extremity. In: Canale T, editor. Campbell's Operative Orthopaedics.Philadelphia: Mosby; 2003. 2725-2872. | 4 Bucholz RW, Ross SE, Lawrence KL.- Fatigue fracture of the interlocking nail in the treatment of fractures of the distal part of the femoral shaft. J Bone Joint Surg Am 1987; 69(9):1391-1399 | 5- Wolinsky PR, McCarty E, Shyr Y, Johnson K. -Reamed intramedullary nailing of the femur: 551 cases. J Trauma 1999; 46(3):392-399. | 6 -Sanders R, Swiontkowski M, Rosen H, Helfet D.- Double-plating of comminuted, unstable fractures of the distal part of the femur. J Bone Joint Surg Am. 1991;73(3):341–346. [PubMed] |