ORIGINAL RESEARCH PAPER

Volume-8 | Issue-1 | January-2019 | PRINT ISSN No 2277 - 8179

INTERNATIONAL JOURNAL OF SCIENTIFIC RESEARCH

A CLINICOPATHOLOGICAL STUDY OF SINONASAL MASSES WITH MAST CELL DENSITY- A SERIES OF 130 CASES

Pathology

Dr.abhishek Sharma Assistant Professor, Deptt of Pathology, College of medicine & Sagore Dutta hospital;Kolkata -58.

Dr.ranu Roy Biswas* Associate Professor, Deptt Of Pathology, College Of Medicine & Sagore Dutta Hospital;kolkata-58. *corresponding Author

Dr Chhanda Datta Prof & Head, Deptt Of Pathology, Ipgme&r,kolkata-20.

Dr.manotosh Dutta Dept. Of Ent, Burdwan Medical College,wb.

ABSTRACT

Although the nasal cavity and paranasal sinuses occupy a relatively small anatomical space, they are the site of origin of some of the more complex, histologically diverse group of tumors in the entire human body. Inflammatory polyps are the commonest lesions. 130 cases of sinonasal mass for a period of two years were studied. 1% Toluidine blue stain for mast cell was done and the same was counted and expressed both in sqmm and per HPF.

We found that Mast cell density was more in benign lesions (61.9±17.9/sq mm) than malignant lesions (6.3/sq mm). Among the malignant lesion more aggressive tumors like alveolar rhabdomyosarcoma and small cell CA had lower mast cell density than that of PLGA. Inflammatory nasal polyp having history of allergy had severe eosinophilic infiltration.

KEYWORDS

Sinonasal mass, nasal polyp, mast cell.

INTRODUCTION:

Polyps of the nasal cavity and paranasal sinuses are non-neoplastic stromal and epithelial proliferations of uncertain pathogenesis. Inflammatory polyps are, by far, the most common of these lesions. Nasal polyps are not true neoplasm. Their formation is associated with inflammation, allergy, or mucoviscidosis. [1] Clinically, they appear as soft polypoid masses that extend laterally from the mucosa into the anterior part of the middle meatus. [2] They are almost invariably multiple and typically bilateral, and they involve both the nasal cavity and the paranasal sinuses. The etiology of nasal polyps is still unclear.

The two most frequently mentioned etiologies are based on allergic & infectious causes.There is an increased number of epithelial mast cells in nasal polyps.[3] Electron microscopic studies have shown marked & widespread mast cell degranulation in all polyps studied.[1] It is in accordance with the ultra-structural changes that total histamine levels in polyps are far higher than any other tissues.[4]But there are hardly any details in the literature regarding the distribution & abundance of mast cells in nasal polyp tissues (Figure 03 & 04).

AIMS & OBJECTIVES OF THIS STUDY:-

1. To correlate the histopathological diagnosis with the clinical diagnosis.
2. To quantitate & study the localization of mast cells in sinonasal lesions.
3. To assess the degree of eosinophilic infiltration in the cases of inflammatory polyps.

MATERIALS AND METHODS:

The study was carried out at the Department of Pathology and the Department of ENT, of a tertiary Medical College for a period of two years. Total of 130 cases were studied.

The histology section were stained with routine H & E stain and 1% toluidine blue for mast cells, the number of mast cell was counted under high power field. For each slide stained in 1% toluidine blue, mast cell was counted in 10 HPF and the mean of it was taken for the expression of mast cell density.

The area of the HPF of Lawrence & Mayo microscope bearing no.001099, model XSZ-N207 was calculated with the help of occulometer by measuring the diameter of the field. This area was further confirmed by calculating the field of view by applying the following formula:[5]

$$\text{Diameter of HPF/Field of view (in mm)} = \frac{\text{Field of view number of eye piece}}{\text{Magnification of the objective}}$$

After this the mast cell density was expressed in sq mm.

RESULT & ANALYSIS:

From the study it was found that sinonasal masses were most commonly seen between 10 and 20 yrs age group (36.9%) and the masses were least common in 0 -10 yrs age group. Males were more commonly affected (57.7% of cases) than females (42.3% of cases). Nasal cavity was the most common anatomical location of all the sinonasal masses (78.5%), while nasal obstruction was the most common presenting symptom (53.1%). Non-neoplastic lesion was the most common type of lesion in the sinonasal area accounting for 65.4% of all cases. Among the neoplastic lesion, benign lesions were more common than the malignant lesion accounting for 20.8% and 13.8% of all cases respectively. Inflammatory nasal polyp (63.5%) was the predominant non-neoplastic sinonasal lesion followed by Rhinosporidiosis,(Figure 01) which accounted for 23.6% of all non-neoplastic cases. Among the benign sinonasal masses angiofibroma (37%) was the commonest followed by haemangioma (22%) and inverted papilloma (22%). Squamous cell carcinoma was the most common malignancy followed by nasopharyngeal carcinoma, while adenoid cystic carcinoma and small round cell carcinoma jointly occupies third position of all the sinonasal masses. Eosinophil count was high (>50/sqmm) only in 37.5% cases of inflammatory nasal polyp showing that allergy is one but not the sole etiological factor in the development of inflammatory nasal polyp (Diagram 1). hus we can also conclude that allergic nasal polyp was less common than non-allergic polyp in our study. Among all the cases of sinonasal masses studied in the present study it was seen that angiomatous polyp had highest number of mast cell density of 61.9±17.9/sq mm (Diagram 2) followed by haemangioma and angiofibroma which had mast cell density of 52.4±3.2 and 52.2±7.3/sq mm.

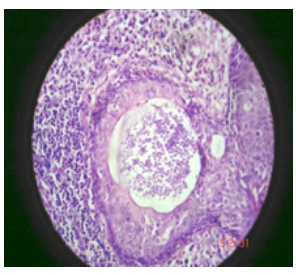

(a)

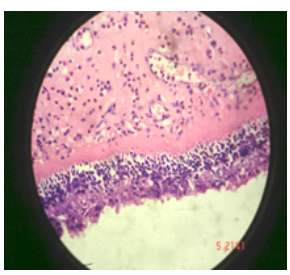

(b)

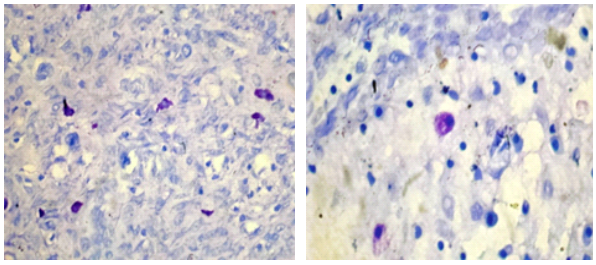

(C) (d)

FIG.1

(a). H & E Stained section of Rhinosporiodosis, 400X.
(b). H & E Stained section of Allergic inflammatory nasal polyp with severe degree of eosinophilic infiltration, 400X.
(c) 1%Toluidine blue stain of inflammatory nasal polyp showing mast cells, 400X.
(d) 1%Toluidine blue stain of inflammatory nasal polyp showing mast cells, 1000X.

While lowest number of mast cell density was seen in alveolar rhabdomyosarcoma, small cell carcinoma, and adenoid cystic carcinoma each having mast cell density of 6.3/sq mm (Diagram 3). Among the non-neoplastic lesions angiomatous polyp had highest number of mast cell density while rhinosporidiosis had lowest number of mast cell density (Diag 2 &3). The p value of mast cell density of sinonasal masses for benign versus malignant lesions were found to be statistically significant ($p<0.05$), it was found to be 0.0234.

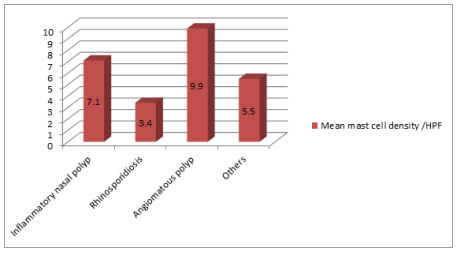

Diag. 1. Bar Diagram Showing The Distribution Of Mean Mast Cell Density/ Hpf In Non-neoplastic Sino Nasal Masses (n=85).

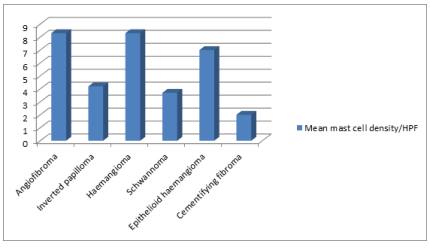

.Diag.2.Bar diagram showing the distribution of mast cell density /HPF in Neoplastic benign sinonasal masses (N=27).

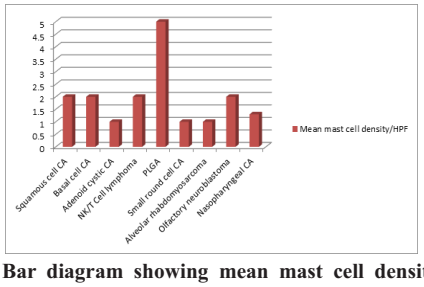

Diag.3. Bar diagram showing mean mast cell density/HPF in Neoplastic malignant sinonasal masses (N=18).

Nasal polyps and ethmoid sinus mucosa in patients with asthma showed a higher positivity of eosinophils than in those without asthma. The positivity of eosinophils differed significantly between small and large nasal polyps. [8] 21 inflammatory nasal polyp showed high eosinophil count(Figure 02), (>50/sqmm) while 35 cases showed low eosinophil count (<50/sqmm).Most of the cases with high eosinophil count had allergic history.

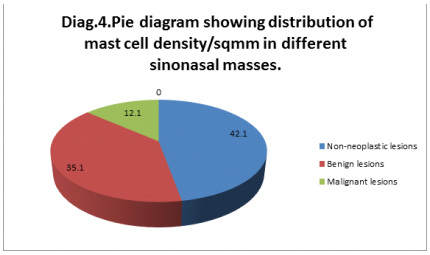

DISCUSSION

Nasal polyps are benign lesions which arise from the nasal mucosa commonly at the outflow tract of one or more of the sinuses. Most of the have unknown etiology with a tendency to recur, they represent a challenging diagnosis for the physician to treat. Nasal polyposis is typically associated with other respiratory diseases such as asthma,aspirin sensitivity, and idiopathic bronchiectasis.[8]Mast cells are multifunctional effector cells of the immune system, which contribute both to innate and acquired immunity. It is seen that mast cells migrate toward the hypersensitive airway smooth muscle bundle in asthma. [7]Highest number of mast cell in angiomatous polyp may be due to the fact that mast cell are increased in lesions having increased vascular proliferation which is also supports by the work of Nishijima Koji et al.[6]

There was a single case of ossifying fibroma in our study which on microscopy showed irregular laminar bone rimmed by osteoblast which helped to distinguish from fibrous dysplasia. In our study, the lesion was in the maxilla of an 11 year old girl. The most striking feature of this lesion on microscopy was the presence of large, sharply defined, irregularly shaped, calcified spherules set in a densely fibrous stroma.

Single case of Angiolymphoid hyperplasia with eosinophilia in a 41 year old male presented with nasal mass along with epistaxis .The diagnosis was confirmed by histological examination which showed characteristic histological features of ALH which included proliferation of thick-walled blood vessels lined by prominent plumed endothelial cells protruding into the lumen, infiltration of the interstitium by chronic inflammatory cells (mainly eosinophils), and presence of lymphoid follicles with germinal centres.

In our study we found a single case of inflammatory nasal polyp with large bizarre atypical cells in the stroma simulating sarcoma but after reviewing the literature we found that such atypical cells in the stroma are common in inflammatory nasal polyp and are seen as reactive changes.

CONCLUSION:

The present series found that mast cell density was more in benign lesions than that of malignant lesions (Diagram 4). Among the malignant lesion more aggressive tumors like alveolar rhabdomyosarcoma and small cell carcinoma had lower mast cell density than that of PLGA. Thus we can conclude that mast cell density can be used as an indicator to determine the aggressiveness of the tumor. However larger study involving different anatomical sites must be done to establish this hypothesis.

REFERENCES:

1. Larsen PL, Tos M. Origin of nasal polyps. Laryngoscope.1991; 101:305-312,
2. Yazbak PA, Phillips JM, Ball PA, Rhodes CH. Benign nasal polyposis presenting as an intracranial mass. Case report. Surg Neurol. 1991;36:380-383.
3. Drake-leeA,price J. Mast cell ultrastructure in the inferior turbinate +stroma of nasal polyp. Journal of laryngoscopy & otology 1997, 111; 390-5.
4. Walike JW. Anatomy of the nasal cavities. OtolaryngolmClin North Am 1973; 6:609-621.
5. WebPath: Internet Pathology Laboratory http://www-medlib.med.utah.edu/WebPath/webpath.html
6. Nishijima Koji, Nishumura Gen'ichi, ota Tetsuo, Inokuchi Masashi, HaYashi Tomohiko, Yasui Toshiaki ,Ninomiya Itaru ,Fushida Sachio, Miwa Koichi. Clinicopathological Evaluation of Mast Cell Infiltrations in Human Colorectal Cancer Tissues. Correlation Between the Degree of Mast Cell Infiltration and Tumor Angiogenesis, Journal of the Japan Society of Colo-Proctology. 2001;54(1); 18-23.
7. Sutcliffe A, Kaur D, Page S, Woodman L, Armour CL, Baraket M, Bradding P, Hughes JM,Brightling CE. 2006. Mast cell migration to Th2 stimulated airway smooth muscle from asthmatics. Thorax61: 657–662.
8. Guilemany JM, Angrill J, Alobid I, et al. United airways: The impact of chronic rhinosinusitis and nasal polyps in bronchiectasic patient's quality of life. Allergy . 2009: 64:1524–1529.