Volume : 2 | Issue : 3 | Mar 2013 • ISSN No 2277 - 8179

Research Paper

Medical Science

KEYWORDS: Reactive hyperplasia, Pyogenic granuloma, lower lip.

A Common Oral Lesion in an Unusual Site - Pyogenic Granuloma Of Lip.

Dr. Hina Mathur	Postgraduate Student, Dept of Oral Medicine and Radiology, KLE VK Institute of dental sciences, Belgaum, Karnataka
Dr. Arvind Shetti	Professor and Head, Dept of Oral Medicine and Radiology, KLE VK Institute of dental sciences, Belgaum, Karnataka
Dr. Shivyogi Charantimath	Reader, Dept of Oral Medicine and Radiology, KLE VK Institute of dental sciences, Belgaum, Karnataka

ABSTRACT

Pyogenic granuloma is a benign non-neoplastic mucocutaneous lesion that occurs as a reactive inflammatory response to constant minor trauma and might be related to hormonal changes. Gingiva is its most common site of occurrence. When present extra-gingivally, it may mimic more serious lesions such as malignancies.
Here we report a rare presentation of Pyogenic granuloma of lower lip with a discussion on the possible differential diagnosis that should be considered in such an unusual case and treatment modalities available for treatment of such lesions.

Introduction
Pyogenic granuloma is a hyperplastic, reactive lesion of the mucocutaneous tissues. Clinically, it manifests as a smooth or lobulated, erythematous, hemorrhagic, exophytic lesion on a pedunculated or sessile base .The term "Pyogenic Granuloma" was first introduced by Hartzell in 1904[1] is considered a misnomer as the lesion does not contain pus or resemble a granuloma histologically. The granulation tissue in oral pyogenic granuloma may become contaminated by flora of oral cavity and its surface may often become covered by fibrin which may mimic pus.2

While some investigators regard Pyogenic Granuloma as a benign neoplasm, it is usually considered to be a reactive tumour like lesion that arises in response to chronic low grade irritation from factors like calculus, restoration overhang, margins of crown, foreign body implantation or chronic biting of soft tissues.3

It shows obvious histopathological findings of prominent capillary growth in hyperplastic granulation tissue suggesting a strong activity of angiogenesis.4 There are two kinds of Pyogenic granuloma namely Lobular capillary hemangioma and Non- lobulated capillary hemangioma which differ in their histologic and clinical features. 5

Case Report
A 45 year old female, farmer by occupation, reported to the department of Oral Medicine and Radiology with a complaint of a growth on the right side of lower lip since three months. Patient gave history of fever and fluid filled vesicles in the same region preceding the growth. She gave history of repeated self inflicted trauma to the vesicles after which the growth appeared. The growth had gradually increased in size after the patient had traumatized it. The past medical history was unremarkable.

Inspectory examination revealed a solitary, exophytic, sessile, well defined oval shaped growth measuring 1.5 cm × 1cm × 0.5 cm on the right side of the lower lip below the vermillion border, 5 mm mesial to the right commissure of the lip (fig 1). Mucosa over the growth was erythematous with yellowish crusted areas on nodular surface. The growth was firm in consistency, tender, non-pulsatile and slightly febrile on palpation. Slight manipulation of the growth elicited bleeding.

On the basis of the history and clinical features it was provisionally diagnosed as Pyogenic Granuloma of lip. Excisional biopsy for histo-pathological evaluation was indicated.

Differential Diagnosis:
The clinical differential diagnosis included cutaneous horn, squamous papilloma, keratoacanthoma, amelanotic melanoma and squamous cell carcinoma.

Cutaneous horn is a conical hyperkeratotic projection of the skin composed of compact keratin.6

Squamous papilloma is a benign proliferation of stratified squamous epithelium of viral etiology resulting in a papillary, exophytic, cauliflower like mass either white or of normal mucosal colour. Keratoacanthoma or "self healing carcinoma" is an epithelial proliferation with a central crater that has a strong clinical and histopathological similarity to well differentiated squamous cell carcinoma. It occurs on sun exposed tissues of the face.7 Amelanotic melanoma is a flesh coloured dome shaped or polypoid mass occurring on sun exposed surfaces.8 The vermillion border of the lower lip is a common location of Squamous cell carcinoma which typically develops in pre-existing actinic chaelitis.7

Histopathology:
Stratified squamous, hyperkeratinised epithelium showing pseudoepitheliomatous hyperplasia was seen. The underlying connective tissue was highly vascular and made up of a number of budding capillaries and endothelium lined blood vessels with red blood cells. The endothelial cells were seen proliferating in the form of lobules throughout the connective tissue. The stroma was made of dense bundles of collagen fibers with plump spindle shaped fibroblast. Large areas of fibrin and extravasated red blood cells were seen in areas devoid of epithelium with diffuse inflammatory infiltrate indicating Lobular capillary hemangioma.

Figure :Clinical (A) and Histopthological picture 40X (B)



Volume : 2 | Issue : 3 | Mar 2013 • ISSN No 2277 - 8179

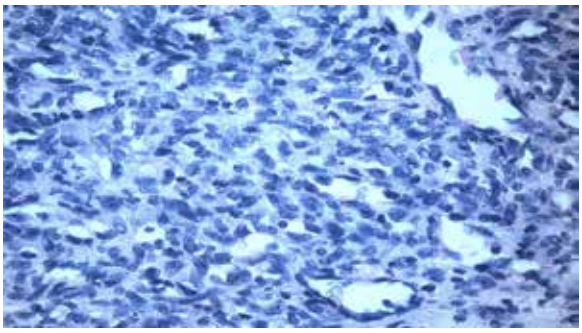

Discussion

Pyogenic granuloma is a reactive lesion formed in response to minor trauma or chronic irritation with reports of its occurrence after low intensity traumatic injuries.9Approximately one third of the lesions occur after trauma.10 The history of fluid filled vesicles on the lower lip accompanied with fever indicates that prior to the development of growth, herpetic vesicles may have developed on the lip. The history of repeated self inflicted trauma by the patient evidently points to the cause of development of the lesion. A similar case has been reported by Goncales et al9 where chemical injury to a probable herpetic vesicle resulted in the formation of pyogenic granuloma of the upper lip. Ainamo suggested that trauma can cause release of various endogenous substances including angiogenic factors from the tumor cells and causing disturbances in the vascular system of the affected area.11 Though a close resembling lesion that has been called as "Kaposi's sarcoma like pyogenic granuloma" has been observed to occur in patients with HHV-8 infection and its presence confirmed in the lesions by DNA testing, but whether or not herpes virus infection had a role in initiating the pyogenic granuloma is not clear.12 The patient was occupationally exposed to sun for prolonged hours, which led us to consider lesions like keratoacanthoma and squamous cell carcinoma in differential diagnosis.

Treatment of pyogenic granuloma consists of conservative surgical excision which is usually curative. There is a relatively high rate of recurrence (about 16%) after simple excision. Recurrence is believed to result from incomplete excision, failure to remove etiologic factors or re-injury of the area.13 Other unconventional methods for treatment include use of Nd- YAG lasers,14flash lamp pulsed dye Laser 15 cryosurgery16 injections of absolute ethanol17 sodium tetradecyl sulphate 18 and intralesional corticosteroid injections. 19

Conclusion

Pyogenic Granuloma is not only a lesion with multiple etiologies and clinical presentations but it can also occur in various sites. A careful history and examination is essential in cases where unusual site of occurrence is seen. A complete removal of the lesion as well as the local irritating factors is absolutely essential to avoid recurrence.

REFERENCE

1. Hartzell M.B.Granuloma pyogenicum.J Cutan Dis Syph1904;22:520-25. | 2. Peter A. Reichart, Hans Peter Philipsen. Color Atlas of Dental Medicine Oral Pathology. Stuttgart: Thieme. 2000:163 | 3. Wood NK, Goaz PW, Sawyer DR. In: Wood NK, Goaz PW, editors. Peripheral oral exophytic lesions. Differential diagnosis of oral and maxillofacial regions. 5 th ed. St. Louis: Elsevier:2006. 138. | 4. Regezi JA, Sciubba JJ, Jordan RC. Oral pathology: Clinical pathologic considerations. 4th ed. Philadelphia: WB Saunders; 2003;115–6. | 5. EpivatianosA,AntoniadesD,Zaraboukas T et al. Pyogenic granuloma of the oral cavity: comparative study of its clinico-pathological and immunohistochemicalfeatures.Pathol Int.2005 Jul;55(7):391-7 | 6. Souza LN, Martins CR, de Paula AM. Cutaneous horn occurring on the lip of a child. Int J Paediatr Dent. 2003 Sep;13(5):365-7. | 7. Neville BW, Damm DD, Allen CM, Bouquot JE: Oral and maxillofacial pathology, 2nd ed. Elsevier, Philadelphia,2002 : 316-356. | 8. Marx RE, Sterm D: Oral and maxillofacial pathology-A rationale for diagnosis and treatment. In: Pigmented lesions of mucosa and skin. Quintessence publishing co. inc.Chicago, 2003; 727-728. | 9. Gonçales E.S., Damante J.H., Fischer R.C.M., Taveira L.A. Pyogenic granuloma on the upper lip: an unusual location. J Appl Oral Sci. 2010 Sep-Oct; 18(5):538-41. | 10. Pilch B Z. Head and neck surgical pathology 2001. Lippincott Williams and Wilkins, Philadelphia.389-390. | 11. Ainamo J. The effect of habitual tooth cleaning on the occurrence of periodontal disease and dental caries. Suom Hammaslaak Toim. 1971;67:63. | 12. Ryan P, Aarons S, Murray D et al. Human herpesvirus 8 (HHV-8) detected in two patients with Kaposi's sarcoma-like pyogenic granuloma.. J Clin Pathol. 2002; 55(8): 619–622. | 13. Jafarzadeh H, Sanatkhani M, Mohtasham N. Oral pyogenic granuloma: a review. J Oral Sci. 2006 Dec;48(4):167-75. | 14. Powell J L, Baily C L, Coopland A T, Otis C N, Frank J L, Meyer I. Nd:YAG Laser excision of a giant gingival Pyogenic granuloma of pregnancy. Lasers Surg Med 1994;14:178-183. | 15. Meffert JJ, Kagna D R , Meffert R M. Treatment of oral granulation tissue with flashlamp pulsed dye laser. Dermatol Surg 1998 ; 24:845-848. | 16. Ishida C E, Ramos E Silva M. Cryosurgery in oral lesion. Int J Dermatol 1998 ; 37:283-5. | 17. Ichimaya M, Yoshikawa Y, Hamamoto Yet al. Successful treatment of Pyogenic granuloma with injections of absolute ethanol. J Dermatol 2004;31:342-44. | 18. Moon S E, Hwang E J, Cho K H. Treatment of Pyogenic granuloma by sodium tetradecyl sulphate sclerotherapy. Arch dermatol2005 ;141:644-46. | 19. Parisi E, Glick P H, Flick M. Recurrent intra oral Pyogenic granuloma with satellitosis treated with corticosteroids. Oral Dis 2006; 12: 70-72. | | |