Volume : 3 | Issue : 6 | June 2014 • ISSN No 2277 - 8179

Research Paper

A Comparative Study of Placenta in Normal and Pregnancy Induced Hypertension

Medical Science

KEYWORDS : Placenta, Pregnancy, Pregnancy Induced Hypertension (PIH).

Mr. Prakash Manae	Assistant Lecturer, Department of Anatomy, MGM Medical College, Sector-1, Kamothe, Navi Mumbai-410209
Dr. Nazmeen Silotry	Associate Professor, Department of Anatomy, MGM Medical College, Sector-1, Kamothe, Navi Mumbai-410209
Dr. Aruna Mukherjee	Professor and Head, Department of Anatomy, MGM Medical College, Sector-1, Kamothe, Navi Mumbai-410209
Mr. Kishwor Bhandari	Ph.D. Scholar, Department of Anatomy, MGM Medical College, Sector-1, Kamothe, Navi Mumbai-410209.
Mrs. Sanju Acharya	Post Graduate Student, Department of Physiology, MGM Medical College, Sector-1, Kamothe, Navi Mumbai-410209

ABSTRACT

Placenta is derived from two separate individuals, the mother and the foetus. The growth of the foetus is intricately linked with that of placenta because of transfer of nutrients and oxygen through placenta. Pregnancy induced hypertension is a common pathological condition related to pregnancy. The objective was to assess the morphology of placenta in normotensive and hypertensive pregnancies and to compare them. A total of fifty placentae were collected from Department of Gynecology MGM Hospital, CBD Belapur, Navi Mumbai. Out of fifty placentae, twenty five were from PIH group and remaining twenty five were from normal group. The placental shape, size, diameter, area, thickness, weight, volume, number of cotyledons and weight of the foetus were compared between PIH and normal group. Most of the evaluated parameters were decrease in PIH group than in normal group. There were no any differences in the shape of the placentae between the two groups. The adverse effects of hypertension in pregnancy are reflected on placenta as well as on the foetus.

Introduction:

The human placenta is a discoid chorio decudate organ which connects foetus with the uterine wall of mother. It is the functional centre of the maternal-foetal system. It is responsible for respiratory, nutritional, excretory, hormonal and immunological functions.[1] The growth and survival of the foetus depends on the formation, development and functions of the placenta. Now there is recognition that placental examination often yields valuable informations as the placenta has many clues to events, occurring throughout the gestation. Maternal diseases in pregnancy attribute to the great degree of morbidity and mortality of foetus as well as mother. Placenta itself is a reflection of maternal diseases.[2] So the study of placenta gives valuable clue in cases of adverse foetal outcome.

The full-term placenta is a discoid-shaped organ. It is 3 cm thick and about 15 to 25 centimeter in diameter. The weight of the placenta is about 500 gm. It is made up of a foetal and a maternal component.[3] The foetal component is derived from a tissue that arises from the conceptus called the chorion. The foetal side of the placenta is shiny because of apposed amniotic membrane. In the foetal side of the placenta, there is the attachment of umbilical cord to the chorionic plate and the large placental branches of the umbilical arteries and vein radiating from it are evident. The placenta features the 'leafy' region of the chorion, known as the chorion frondosom. The chorion frondosom comprises a chorionic plate and finger-like projections called chorionic villi. The chorionic villi are the basic structures for exchange between foetal and maternal blood in the placenta.

The maternal part of the placenta is the decidua basalis. It is derived from the decidua, which is the transformed uterine lining (endometrium) during pregnancy. The maternal side of the placenta is dull and subdivided into as many as 25 lobes. The grooves between lobes are occupied by placental septa, which arise from decidua basalis and extend towards the basal plate. Within a placental lobe are several cotyledons each of which consists of main stem villus and its branches. The intervillus space in each lobe represents a nearly isolated compartment of the maternal circulation to the placenta.[4]

Pregnancy induced hypertension (PIH) is one of the leading cause of death of mothers and foetuses. Hypertension in pregnancy intensifies the morphological changes in pregnancy including foetal distress and foetal death.[5]Pregnancy complicated by hypertension is commonly associated with placental insufficiency.[6] It is associated with macroscopic and microscopic changes in the placental structure. Maternal hypertension affects the uterine blood vessels and decreases the lumen which leads to reduced blood flow between the intervillous spaces.

Hypertensive disorders complicating pregnancy are common and form one of the deadly triad along with haemorrhage and infection, that results in large number of maternal deaths and there off foetal deaths. Since all anabolites needed for foetal metabolism come from the mother's blood and foetal catabolites are passed back into the mother's circulation through the placenta.

Just by mere observation and touch to the placenta, it gives us much information regarding gestational events. The results are often helpful in caring the neonate and to plan the healthy baby outcome in future. The present study was done to record the data on morphology and morphometry of placenta and its correlation of baby weight with the placental weight in PIH and normal patients.

Materials and Methods:

The morphological study of placenta of normal and those of pregnancy induced hypertension (PIH) patients were conducted. A total of fifty placentae were collected for the study from the Department of Gynecology MGM Hospital, CBD Belapur, Navi Mumbai. Out of fifty cases, twenty five cases belonged to normal pregnancy and twenty five belong to PIH. Medical history of all mothers was noted. Mothers having history of pre gestational HTN, DM, babies with congenital anomalies were not included in this study. In normal group, only those cases with normal BP (SBP<140 mmHg and DBP<90 mmHg) without edema or proteinuria were taken. In PIH only those cases having BP (SBP>140 mmHg and DBP>90 mmHg) irrespective of edema and proteinemia were taken. Placenta with membranes were collected immediately after the delivery and washed thoroughly

Volume : 3 | Issue : 6 | June 2014 • ISSN No 2277 - 8179

under running tap water. Blood clots were removed and it was kept in 10% formalin. The shape, diameter, surface area, weight, volume, cotyledon, thickness of the placentae were noted. The weight of the babies was measured after the delivery. All the parameters were noted, tabulated and statistically analyzed.

Observations and Results:
Following tables and figures show the findings of the different parameters of the study on normal and PIH placentae.

Figure 1: Comparison of shape of placenta between normal and PIH group.

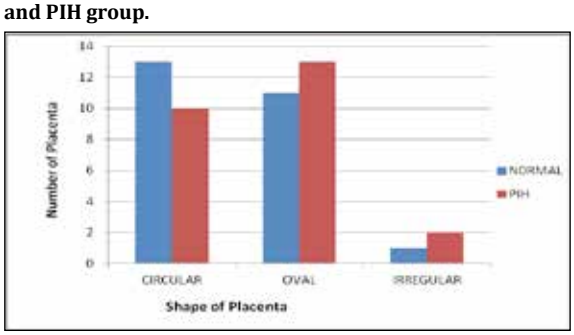

Table1: Comparison of diameter of placenta in normal and PIH group.

S.N.	Measurements	Normal	PIH
1.	Mean diameter	17.88 cm	14.52 cm
2.	Standard deviation	1.96 cm	2.78 cm
3.	Coefficient of variation	10.99	19.19

Figure: 2 Comparison of thickness of placenta in normal and PIH group.

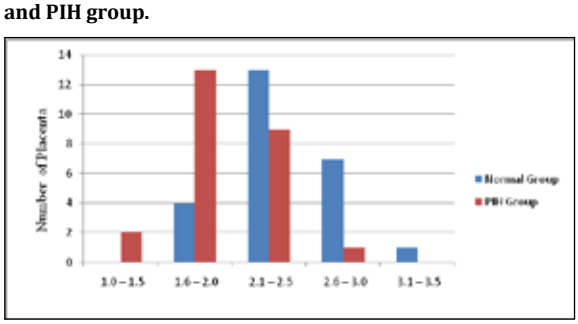

Table 2: Comparison of surface area of placenta in normal and PIH group.

S.N.	Measurements	Normal Group	PIH Group
1.	Minimum surface area	140.955 cm^2	94.985 cm^2
2.	Maximum surface area	369.649 cm^2	346.185 cm^2
3.	Mean surface area	251.52 cm^2	169.63 cm^2
4.	Standard deviation	55.195 cm^2	69.62 cm^2
5.	Coefficient variation	21.94	41.044

Table 3: Comparison of volume of placenta in normal and PIH group

S.N	Measurements	Normal Group	PIH Group
1.	Minimum volume of placenta	270 ml	175 ml
2.	Maximum volume of placenta	580 ml	490 ml
3.	Mean volume of placenta	414 ml	282 ml
4.	Standard deviation	84.28 ml	83.52 ml
5.	Coefficient of variation	20.36	29.52

Table 4: Comparison of weight of placenta in normal and PIH group

S.N.	Measurements	Normal	PIH
1.	Minimum weight	380 g	285 g
2.	Maximum weight	720 g	530 g
3.	Mean weight	530 g	390 g
4.	Standard deviation	93.808 g	89.443 g
5.	Coefficient variation	17.699	22.934

Fig 3: Distribution graph of number of cotyledons in normal and PIH group.

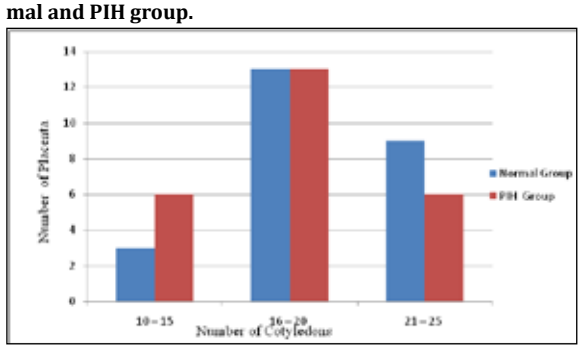

Table 5: Numbers of cotyledons in normal and PIH Group.

S.N.	Measurements	Normal	PIH
1.	Minimum cotyledons	10	11
2.	Maximum cotyledons	25	22
3.	Mean of cotyledons	18.7	17.5
4.	Standard deviation	3.25	3.46
5.	Coefficient variation	17.38	19.79

Table 6: Weight of new born baby in normal and PIH group.

S.N.	Wight in grams	Normal group	Percentage (%)	PIH group	Percentage (%)
1	1001 – 1500	1	4%	2	8%
2	1501 – 2000	2	8%	11	44%
3	2001 – 2500	4	16%	7	28%
4	2501 – 3000	8	32%	4	16%
5	3001 - 3500	9	36%	1	4%
6	3501 – 4000	1	4%	NA	NA
Total		25	100%	25	100%

Table 7: Comparison of weight of baby in normal and PIH Group

S.N.	Measurements	Normal	PIH
1.	Mean	2750 g	2070 g
2.	Standard Deviation.	583.095 g	487.442 g
3.	Coefficient of variance	21.20345	23.54794

Discussion:
In India, the number of pregnancy induced hypertension cases are increasing due to the stress, increased maternal age and change in the lifestyle of Indian women. The incidence is high in backward countries with malnutrition, hypoproteinemia and poor obstetric facilities. One of the common methods of investigation of the factors endangering the foetus and new born during the prenatal period is the examination of placenta.[2] Therefore, it is the most accurate record of infant's prenatal experiences. This study was designed to compare the morphological and morphometrical changes in placenta in normal and PIH group. The results of this study were compared with the result of other researcher.

In this study there were no significant changes in the shape of

placenta in normal and PIH group. In normal group, circular shape of placentae was found in 52 % cases and oval shape placentae in 44 % cases. In PIH group, circular shape of placentae was found to be 40 % cases and oval shape placentae in 52 % cases. There was no statistically difference in shape of placenta in normal and PIH group.

Fox in 1975, has stressed the importance of analyzing the placental pathology quantitatively and stated that the importance of the lesions could be realized only when assessed in relation to foetal growth and maturation. Fox stated that placenta of preeclamptic group tend to be smaller than placentae of normal group.[7] In the present study, the diameter of placenta in PIH group was less compared to the diameter of normal group. The mean diameter of placenta in normal group was found to be 17.88 cm and in PIH group, it was found 14.52 cm. And these findings were conformed to the fox study.

In the present study the mean thickness of placenta in PIH group was found to be 1.93_+0.34 cm and in normal group the mean thickness was found to be 2.35_+0.37 cm. The decrease in placental thickness in PIH group was statistically significant ($p < 0.05$).

Udania (2004) found the mean surface area of placenta in normal group was 242.56 cm^2 and in PIH group it was 187.56 cm^2.[8] These findings are similar to our study in which the mean surface area of normal group was 251.52_+ 55.19$cm^2$and in PIH group it was 169.63 _+ 62.69 cm^2. The significant decrease in the surface area of placenta in PIH group was in conformity with Rath (2000) who stated that the mean surface area of placenta of PIH group was less than normal group.[9]

The volume of placenta was decreased in PIH group in the present study. The mean volume of placenta in normal group was found to be 414_+ 84.28 ml and in PIH group it was found to be 282_+83.52 ml. It was similar with Majumdar 14 who stated that the mean volume of placenta of PIH group was less than the normal group.

Normally the weight of the placenta is 400-800 grams. In this study the weight of placenta in hypertensive disorder was decreased. In normal group, the mean weight of placenta was 530 grams and in PIH group it was 390 grams. These findings are similar to Hosemann (1949)[10], Singhs,[11] William P.L. [12] Chakravorty (1967) in his study of pregnancy induced hypertension found the mean placental weight was 410 grams in mild hypertension and 350 grams in severe hypertension.[13]

In this study the mean number of cotyledons in the normal group was 18.7 and in PIH group was 17.5. Number of cotyledons was found to be significantly less in PIH group which was similar to the findings of the study by Sultana S. et.al. (2000) and Pradip londhe. Pradip londhe found the mean number of cotyledons in PIH group was 11.61_+2.42 and in normal group 15.28_+1.53 which was significantly more as compared to the PIH group.[14]

Chakravorty (1967) found the mean foetal birth weight was 2805 grams in the normal term pregnancy, 2724 grams in mild hypertension and 1759 grams in severe hypertension.[13] In the present study, the foetal weight in normal pregnancy patients is found to be range between 3001 – 3500 in 36 % cases and between 2501 – 3000 in 32 % cases. In PIH group the foetal weight was found in the range between 1501- 2000 in 44 % cases. The mean foetal birth weight is 2070 grams in hypertensive patients and in the normal group mean foetal weight is 2750 grams. Therefore, in the present study, mean foetal birth weight is lower than the findings of the above author.

The reduction in placental and foetal weight in pregnancy induced hypertension was shown by Armitage P, [15] Chakravorty,13 Thomson A.M.[16] Also Sinclair [17] and Hamilton 18 have shown that there is a linear correlation between placental weight and foetal weight. This is also confirmed by the present study.

Conclusion:

From the present study, we concluded that there is no differences in the shape of placenta of normal and PIH group. The placental size, diameter, surface area, thickness, weight, volume and cotyledons are significantly less in PIH group when compared to the normal group. The weight of foetus is also significantly less in PIH groups than normal groups.

The maternal hypertensive disorders have definite adverse influences on the morphology of placenta. It is also seen that the placenta has a great potential to provide valuable information in the case of an adverse foetal outcome.

Abbrebiations:

HTN: Hypertension.
DM: Diabetes Mellitus.
BP: Blood Pressure.
SBP: Systolic Blood Pressure
DBP: Diastolic Blood Pressure
PIH: Pregnancy Induced Hypertension.

REFERENCE

1. G.Priya , Raghunath ; A study on the morphology and the morphometry of the | human placenta and its clinical relevance in a population in tamilnadu. Indialant | J Pharma Bio science 2012 July ;(3): 471-475. | | 2. Keith moore textbook of : The Developing Human Clinically Oriented Embryology , eighth edition , 7 , 111-125 | | | 3. Majumdar s, Dasgupta H, Bhattacharya K,Bhattcharya A, (2005): A | study of placenta in normal and hypertensive pregnancies. Journal of anatomy | society of India 54 (2) 1-9 (2005) 35-38 | | 4. A. K. Datta Textbook of : Essentials Of Human Embryology , 6th Edition , 8 , 63 –65 | | | 5. Ashfaque M, Janjua MZ, Channa MA. Effect of gestational diabetes and maternal | hypertension on gross morphology of placenta. J Ayub Med Coll 2005:17(1): 44- | 47. | | 6. Emery SP. Hypertensive disorders of pregnancy: Overdiagnosis is appropriate. | Cleveland Clin J Med 2005: 72 (4): 21-28 | 7. Fox H. The morphological basis of placental insufficiency, Journal of obstetrics and gynaecology of India 1975 ; 25; 441-450. | 8. Udainia A. Relation between placental surface area, infarction and foetal distress | in pregnancy induced hypertension with its clinical relevance. J Anatomical Soc | India. 2004: 53(1): 27-30. | 9. Garg. K ; Rath, G. and Sharma, S. (1996): Association of birth weight,placental | weight and the site of umbilical cord insertion in hypertensive mothers Journal | of Anatomical Society of India. 44. 4. | 10. Hosemann, H. (1946) : Duration of pregnancy and weight of the placenta. Archives | of Gynaecology 176 : 453. | 11. Singh, S.; Padmanabhan, R.; Chinara, P. K; Negi, B. B. and Singh, U. K. (1979) : | Some observations on placentae from maternity hospitals in Varanasi. Journal of | Anatomical Society of India. 28 : 31 | 12. Williams, P.L.; Bannister, L. H.; Berry,M.; Collins, P.; Dyson; M.; Dussek, J. E. | and Ferguson, M. W. J. : Gray's Anatomy In: Early human Development, 38th | Edn; Churchill Livingstone Edinburgh. London.P. 166 (1995). | 13. Chakravorty, A. P. (1967) : Foetal and placental weight changes in normal | pregnancy and pre-eclampsia. Journal of Obstetrics and Gynaecology of British | Commonwealth. 74 : 247-253 | 14. Pradip londhe 1, Abhay Mane 2 , Morphometric study of placenta & its | correlation in normal & hypertensive pregnancies, article down loded , ipbs. net | – B-430-436 | 15. Armitage, P.; Boyd,J. D.; Hamilton W. J. and Rowe, B. C (1967) : A statistical | analysis of a series of birth-weights and placental weight. Human Biology. 39 : | 430. | 16. Thomson, A. M.; Billewicz, W. Z and Hytten, F. E. (1969) : The weight of the | placenta in relation of birth weight. Journal of Obstetrics and Gynaecology Commonwealth .76 : 865-872. | 17. Sinclair JG, Significance of placental & birth weight ratios. Anatomical society. Record 1948 (1): 14-18. | 18. 18. Hamilton, W. J. and Girmes, D. (1969) : A statistical analysis of the growth of the human placenta correlated with the foetus. Journal of Anatomy. 105 : 204. | | |