ORIGINAL RESEARCH PAPER
Volume-6 | Issue-12 | December-2017 | ISSN No 2277 - 8179 | IF : 4.176 | IC Value : 93.98
INTERNATIONAL JOURNAL OF SCIENTIFIC RESEARCH

A COMPARATIVE STUDY OF VARIOUS SURGICAL OPTIONS FOR INCOMPETENT PERFORATOR VEINS (IPVS):

General Surgery

Dr. K. Suhas Professor, Department Of General Surgery, Asrams Eluru, Andhra Pradesh, India. 534005.

Dr. Ayyar Srinivas Mahesh Assistant Professor, Department Of General Surgery, Asrams Eluru, Andhra Pradesh, India. 534005.

Dr. D. Mahesh Rahul Post Graduate, Department Of General Surgery, Asrams Eluru, Andhra Pradesh, India. 534005.

Dr.N.V.N. Praneeth Post Graduate, Department Of General Surgery, Asrams Eluru, Andhra Pradesh, India. 534005.

ABSTRACT

Perforating Veins are a rich network of veins that traverse the muscular fascia between the deep and superficial veins. These veins direct flow from the superficial to the deep systems for return to the heart via the calf muscle pump and a series of one-way valves.
Lower extremity has a series of large named perforators located at 6-cm intervals from the base of the heel to the upper part of the thigh.
This study compares four surgical options available for the treatment of INCOMPETENT PERFORATOR VEINS namely Linton procedure, Modification of Linton procedure, Subfascial ligation of perforators using a stab incision, Subfascial Endoscopic Perforator surgery (SEPS).

KEYWORDS

Perforating veins ,Incompetent perforators, Linton procedure,Modification of Linton procedure,Subfascial ligation of perforators using a stab incision,Subfascial Endoscopic Perforator surgery (SEPS).

I. INTRODUCTION:

- Perforating Veins are a rich network of veins that traverse the muscular fascia between the deep and superficial veins. These veins direct flow from the superficial to the deep systems for return to the heart via the calf muscle pump and a series of one-way valves.Lower extremity has a series of large named perforators located at 6-cm intervals from the base of the heel to the upper part of the thigh.

This is a prospective study in 120 patients done to compare various surgical options for incompetent perforator veins. Various surgical options used in this study are: LINTON method, Modification of LINTON method, Subfascial ligation of perforators using a stab incision, Subfascial Endoscopic Perforator Surgery (SEPS).

ii. AIMS & OBJECTIVES:

1. To compare various surgical options available for treatment of incompetent perforator veins of lower limb.
2. To compare ulcer healing time and post operative hospital stay between diabetics, non diabetics, smokers and non smokers.

iii. INCLUSION CRITERIA:

- All cases of lower limb varicose veins(clinical class more than or equal to C2 S) with incompetent perforators on venous Doppler study.

iv. PATIENTS AND METHODS:

- We conducted a prospective study in The Department of General Surgery, ASRAM, comparing four surgical techniques available for treatment of incompetent perforator veins in 120 patients between January 2016 and April2017.
- A sub study was also done to compare ulcer healing time and postoperative hospital stay between diabetics,non diabetics, smokers and non smokers..
- Pre anesthetic check-up was done for all the cases .
- Preoperative incompetent perforator vein marking was done in cases undergoing subfascial ligation of perforator veins and Ankle-Brachial Pressure Index (ABPI) was measured in all the cases .
- Consent was taken.
- One dose of preoperative antibiotic given for all the cases.
- Venous ulcers were mapped pre-operatively and postoperatively on graph paper and progress of the wound was recorded.
- All cases were done under spinal anesthesia.
- Postoperatively crepe bandage was applied for all the cases.
- Postoperative venous doppler was done in all cases to rule out missed perforators.

v. INDICATIONS TO TREAT AN INCOMPETENT PERFORATOR VEIN(IPV):

1. Promotion of ulcer healing in extremities with CEAP clinical class C6
2. Prevention of ulcer recurrence in extremities with clinical classes C5 and C6
3. Diminution of the severity of CVD and resolution of symptoms in C2S to C5S extremities
4. Prevention of progression to more advanced stages in C2 to C4 extremities.

- The presence of an IPV alone does not justify interruption.

vi. Various surgical options used in the study:

- Group I:LINTON method -30 cases
- Group II:Modification of LINTON method -30 cases
- Group III:Subfascial ligation of perforators using a stab incision-30 cases
- Group IV:Subfascial Endoscopic Perforator Surgery (SEPS)-30 cases

Linton method:

- As originally described by Linton, the procedure involves a medial lower limb incision placed over the site of clinically significant IPVs. Dissection proceeds down to the level of the fascia where the perforators are located and ligated with suture ligatures.

Modification of Linton:

- Under spinal anaesthesia flush ligation and strippng of GSV done till just below knee joint.
- 3 small 2-3 cms horizontal incisions are given along the course of GSV on the medial aspect of lower limb with the lowest incision 5cms above medial malleolus, upper incision 3-4cms below and medial to tibial tuberosity and the third incision placed between these two incisions.
- Incisions are deepened through subcutaneous tissue deep fascia is identified and incised and index finger is introduced into the deep fascial plane and all the perforators are slashed out bluntly by sweeping movements of the finger in all directions.
- Similar technique is followed at other incisions.
- Skin incisions are closed and compression bandaging done.



Figure showing 3 incisions and index finger in the subfascial plane of upper incision





Figure showing both index fingers in the subfascial plane and slashing of the perforators by sweeping movements.

Subfascial ligation of perforators using a stab incision:

- Pre-operative marking of perforators is done by duplex ultrasound.
- Multiple small incisions are given over the marked perforators, T junction is identified ligated and cut.
- Skin incisions are sutured and compression bandaging is done.

Subfascial Endoscopic Perforator Surgery (SEPS):

- First described by Hauer. SEPS uses endoscopic instrumentation to achieve interruption of incompetent perforators.
- Techniques:
- a)The two-port technique:Uses a 10-mm port for the camera and a 5-mm port for the instrumentation
- b)The three port technique: Uses a 10mm port for camera and two 5mm ports for instrumentation



Figure showing port placement in SEPS

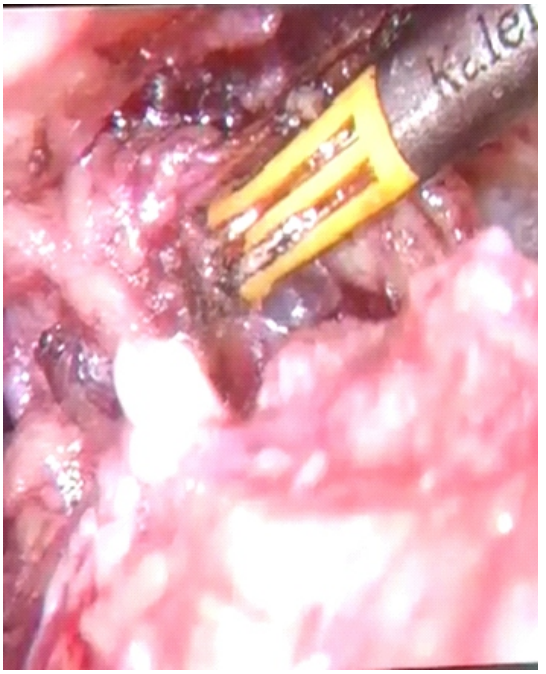

Figure showing Perforator being cauterized

vii. Results:

Serial number:	Method:	Chance of missing a perforator:	Post-operative pain(Plotted on Number pain scale):	Average Ulcer Healing time:	Incidence of wound infection(out of 30 cases):	Recovery and Post-operative stay:
1	Linton method:	None.	Moderate to severe pain, because of the large incision-6(require post-operative NSAIDs).	6-7 weeks	12cases.	7-10 days.
2	Modified Linton method:	Minimal.	Lesser than Linton method -4, Paracetamol suffices.	6-7 weeks	7cases.	4-6 days.
3	Subfascial ligation:	Depends on pre-operative venous Doppler study, which is highly operator dependant.	Almost similar to Modified Linton-4.	6 weeks	5cases.	3-4 days.
4	SEPS:	Very minimal	Minimal-2	4-6 weeks	1case.	1-2 days.

viii. Post operative complications:

Technique:	Post operative wound infections:	Missed perforator (found on Post-op venous doppler):	Ulcer recurrence:	Cutaneous discoloration around incision site:	DVT:
Linton:	12cases (40%)	----	----	19cases (63%)	1 case (3%)
Modification of Linton:	7 cases (23%)	2 cases (6%)	1 case (3 %)	4 cases (13%)	---
Subfascial ligation of IPVS:	5 cases (16%)	7 cases (23%)	1 case (3 %)	2 cases (6%)	---
SEPS:	----	----	-----	—	—

ix. Post operative hospital stay:

Technique:	Non diabetic, Non smokers:	Non diabetic, smokers:	Diabetic, Non smokers:	Diabetic, Smokers:
Linton	7 days	8 days	9 days	10 days
Modification of Linton	4 days	4 days	5 days	6 days
Subfascial Ligation	3 days	3 days	4 days	4 days
SEPS	1 day	1 day	2 days	2 days

x. Average ulcer healing time(in days):

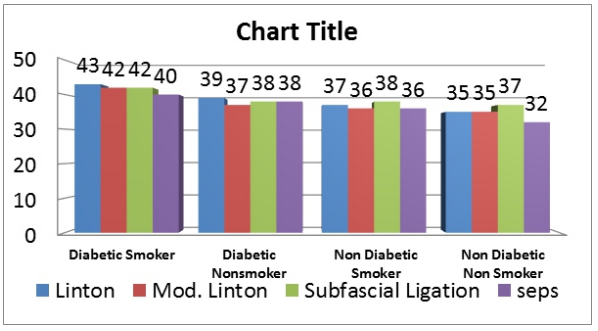

xi. DISCUSSION:

Varicose veins are abnormally enlarged and tortuous vessels that result when veins become incompetent, venous valve leaflets no longer meet in the midline, and this failure allows blood to flow in a retrograde direction (reflux). Varicose veins are most often noted on the back of the calf or on the inside of the leg between the groin and ankle, but can occur anywhere on the extremity. To prevent this retrograde flow of blood from the deep venous system of the leg into the superficial system, the incompetent perforators need to be interrupted.

The treatment of incompetent perforators has come a long way since R.R.Linton who first described the technique of open ligation of perforators through a subfascial long posterior leg incision through the skin in 1938[14]. Several modifications of this procedure have been proposed thereafter[15,16]. Though the procedure was effective for perforator incompetence it was abandoned due to high post-operative complications.

Later perforator ligation was done individually by marking the incompetent perforators by duplex ultrasound and ligating them. This procedure is widely accepted but has its own limitations like it is dependent on the radiologist. Errors by the radiologist and failure of identification of perforators can lead to recurrence.

Endoscopic subfascial ligation technique(SEPS) was first described in 1985 by the German surgeon Hauer[17], and popularized by Fischer.[18,19]

Several trials[20,21,22,23,24]have been conducted worldwide since then to compare the results of endoscopic and open procedures..

xii. CONCLUSIONS:

1) SEPS(Group IV) has shown better results in view of shorter post-operative hospital stay, lesser post-operative pain, minimal incidence of post-operative wound infection, when compared to other techniques.
2) Ulcer healing time was similar in all the techniques.
3) Smoking and diabetes delay ulcer healing, wound healing and post operative recovery, diabetes being a bigger risk factor than smoking, irrespective of the procedure used.
4) If laparoscopic setup is not available, Modified Linton method has shown almost similar results to SEPS

xii. References:

1. CEAP classification, American Venous Forum, 1994
2. Sabiston Textbook of surgery 20th edition.
3. Fischer's Mastery of Surgery 6th edition.
4. Rutherford vascular surgery 7th edition.
5. Large prospective randomized trial demonstrating the benefit of performing superficial venous surgery in addition to conservative Therapy.
6. Michaels J, Brazier J, Campbell W, MacIntyre J, Palfreyman S, Ratcliffe
7. J, Randomized clinical trial comparing surgery with conservativetreatment for uncomplicated varicose veins. Br J Surg. 2006;93:175-181.
8. Large prospective randomized trial demonstrating the clinical benefits of venous surgery.
9. Ricci SG, Goldman M. In: Shalita A, ed. Ambulatory Phlebectomy. 2nd ed.Boca Raton, FL: Taylor & Francis; 2005:335.
10. Delis K, Knaggs A, Hobbs J, Vandendriessche M. The nonsaphenous vein of the popliteal fossa: prevalence, patterns of reflux, hemodynamic quantification, and clinical significance. J Vasc Surg. 2006;44:611-619.
11. Cullum N, North EA, Fletcher AW, Sheldon TA. Compression forvenous leg ulcers. Cochrane Database Syst Rev. 2001;2:CD000265.Cochrane systematic review demonstrating benefit with the use of compression garments for chronic venous disease
12. Retrospective analysis of the data related to the role of IPV in ulcer healing and recurrence from the ESCHAR randomized controlled trial.
13. Gloviczki P, Bergan J, eds. Atlas of Endoscopic Perforator Vein Surgery.London: Springer-Verlag; 1998.Most comprehensive text on perforating vein surgery.
14 Linton RR. The operative treatment of varicose veins and ulcers, based upon a classification of these lesions. Ann Surg 1938; 107: 582–93.
15 DePalma RG. Surgical therapy for venous stasis: results of a modified Linton operation. Am J Surg 1979; 137: 810–13
16 Dodd H, Cockett FR (eds). The management of venous ulcers. In: The pathology and surgery of the veins of the lower limbs. New York: Churchill-Livingstone, 1976: 269–96.
17 Elias SM. Single port SEPS: less is more. In: Presented at the American Venous Forum Annual Meeting, February 2004.
18 Fischer R. Experience with endoscopic perforator interruption. (In German.)Phlebologie 1992; 21: 224–29.
19 Fischer R, Sattler G, Vanderpuye R. The current status of endoscopic treatment of perforators. (In French.) Phlebologie 1993; 46:701–707.
20. Gloviczki P, Bergan JJ, Menawat SS et al. Safety, feasibility, and early efficacy of subfascial endoscopic perforator surgery:a preliminary report from the North American registry. J Vasc Surg 1997; 25: 94–105.
21. Gloviczki P, Bergan JJ, Rhodes JM et al. Mid-term results of endoscopic perforator vein interruption for chronic venous insufficiency: lessons learned from the North American Subfascial Endoscopic Perforator Surgery (NASEPS) Registry. J Vasc Surg 1999; 29: 489–502.
22. MG Vashist et al. Role of Subfascial Endoscopic Perforator Surgery (SEPS) in Management of Perforator Incompetence in Varicose Veins: A Prospective Randomised Study. Indian J Surg (March-April 2014) 76(2): 117-123
23. Ali Jafarian MD et al. Subfascial Endoscopic Perforator Vein Surgery: The first report from Iran. Arch Iranian Med 2006; 9 (1): 16-19
24. Anjay Kumar et al. Evaluation of subfascial endoscopic perforator surgery (SEPS) using harmonic scalpel in varicose veins: An observational study. International Journal of Surgery 7 (2009) 253-256.