Volume : 2 | Issue : 7 | July 2013 • ISSN No 2277 - 8179

Research Paper

A Comparative Study to Assess Surgically Induced Corneal Astigmatism in Superior and Temporal Scleral Incision in Manual Small Incision Cataract Surgery

Medical Science

KEYWORDS : Cataract ,astigmatism , surgical procedures

Dr.R.S.Umadevi — Associate Professor ,Department of Ophthalmology, Kempegowda Institute Of Medical Sciences,K.R.Road,V. V.Puram, Bangalore- 560004, Karnataka, India

Dr.Kirthi Raj — P.G, Department of Ophthalmology, Kempegowda Institute Of Medical Sciences,V V Puram, Bangalore- 560004, Karnataka, India

ABSTRACT

Background and objectives: Cataract is a public health problem in many developing countries. Astigmatism forms a major cause of unsatisfactory visual results after cataract surgery using manual SICS (small incision cataract surgery) technique and is mainly of corneal origin. This study was taken up to assess the role of superior and temporal incision in surgically induced corneal astigmatism among patients undergoing manual small incision cataract surgery.

Materials and Methods: In our study, 30 cases were randomly assigned for temporal scleral group(Group1) and other 30 cases were allotted to superior scleral incision manual SICS with PCIOL (posterior chamber intraocular lens) implantation were performed through unsutured 6.5mm scleral incision(Group2). In all 60 patients were examined pre and post operatively 1st day, 2nd week, 4th week and 6th week after surgery SIA (surgically induced astigmatism) was calculated using SIA calculator 2.1.

Results: Post operatively after 6 weeks in superior incision group a drift of +26.7% was seen towards the ATR(against the rule) astigmatism and in the temporal incision group +33.3% of the patients drifted towards WTR(with the rule) astigmatism. The mean SIA centroid was found to be reduced in the temporal incision group (0.48x86) compared to superior incision group (1.11x1.78). After 6 weeks 33.3% of patients in superior had visual acuity better than 20/30 and in temporal group 80% of the patient had visual acuity better than 20/30.

Conclusion: The superior incision is likely to induce about 1.11D of astigmatism as suggested by the centroid (1.11x178o). Temporal scleral incision is recommended except in patients with pre-existing WTR astigmatism. Visual rehabilitation is better and early in temporal incision than superior.

Introduction:

In total estimated 38 million blind people in the world, 9-12 million are in India. Estimates report that 50-80% of these people are blind because of cataract[1]. In 1864, Franciscus Donders[2] noted that "to the very ordinary causes of altered and consequently irregular arching of the cornea belongs to the extraction of cataract".

Today the implantation of intraocular lenses (IOLs) is a successful procedure for cataract and aphakia. However, due to the advancements in the field of ophthalmic wave front sensing during the past few years, new questions and challenges have arisen that requires additional study[3]. Astigmatism is a visually disabling refractive error affecting the general population, especially those with cataract. 15% to 20% of cataract patients have 1.5 diopters (D) or more corneal of refractive astigmatism[4].

Two major milestones in cataract surgery in the past decade have contributed to reducing pre-existing astigmatism. One was with the shift to smaller incision which has reduced the need for suturing. Thus decreasing induced astigmatism and corneal abrasions. The second milestone is the emergence of surgical options to correct pre-existing astigmatism during cataract surgery[5]

The purpose of this study was to analyse the surgical induced corneal astigamatism by superior versus temporal incision in manual small incision cataract surgery and to record the visual outcome in small incision cataract surgery.

Materials and methods:

Methodology:

This prospective randomized study was conducted in our institution in the department of Ophthalmology between December 2010 to November 2011.

Source of data:

Patients who presented for elective cataract surgery to our outpatient department were evaluated as per inclusion criteria and a total of 60 patients were selected for the study.

The surgical procedure is a manual small incision cataract surgery(MSICS) with posterior chamber IOL implantation under local anaesthesia.

The site of scleral straight incision 30 cases received superior scleral straight incision and 30 cases received temporal scleral straight incision.

Inclusion criteria:

Patients who presented with visually significant cataracts were admitted for small incision cataract surgery. All patients admitted of age 40 years and above, either sex with senile mature and immature cataract.

Exclusion criteria:

Patients with congenital and developmental cataract, complicated cataract, pre-existing corneal opacity, degeneration, dystrophies, uveitis, glaucoma with independently cause limitation of vision, ocular surface disorder, posterior segment complications contributing in poor visual prognosis, pre-existing corneal ectasia, long standing systemic illness and conditions which effect the corneal hysteresis were excluded from the study.

Sampling size and methods:

With the stastical tool this study included 60 patients with above mentioned criteria who were divided randomly into two groups of 30 each based on type of scleral incision used for the surgery. Group I underwent temporal straight scleral incision and GroupII underwent superior straight scleral incision.

Surgical technique- All the patients were operated according to the generally accepted principles of cataract surgery. Peribulbar block was given with combined 2% lignocaine, 1:1000 adrenaline and hyaluronidase (7.5iu/ml).

Temporal scleral straight incision MSICS – (Fig.1) Fornix based conjunctival flap was taken from 10o'clock to 7o'clock. Gentle cautery was done, bridle suture was not used and 6.5mm scleral straight incision was placed around 1-1.5mm posterior to limbus and side port was made around 3o'clock hours away from the main port, rest of the steps used in this procedure were similar to the superior incision.

Surgically induced corneal astigmatism was calculated by vector analysis[6],[7]. The data was also analysed using Cartisan coordinates based analysis with Holladay's system[8].

Superior scleral straight incision SICS – (Fig.2) Fornix based conjunctival flap was taken at 10o' clock and 2o' clock down to bare sclera and gentle cautery was done. A straight scleral incision of about 6.5mm was placed 1.5mm behind the limbus using 11 no BP blade, dissection of sclerocorneal tunnel was undertaken with beveled up crescent blade up to 1-2mm inside the clear cornea, side port was made at 9o'clock position and anterior capsule was stained with trypan blue in case of mature cataract, viscoelastic was introduced into anterior chamber and continuous curvilinear capsulorrhexis was done through side port. Anterior chamber entry was done through the main port using 3.2mm keratome and incision was extended laterally. The internal opening was made 1-2mm larger than the external opening, through hydro dissection was done using 30gauge cannula and nucleus was prolapsed into the anterior chamber. Delivery of the nucleus was done with sandwich technique using vectis and sinskey hook. Anterior chamber was maintained throughout the procedure by injecting viscoelastic into the anterior chamber. After delivering the nucleus, remaining cortex was aspirated using simcoe1 and A cannula, subincisional cortex was aspirated through side port. A posterior chamber PMMA(polymethacrylate) single piece lens of 6mm (overall 12.5mm) optics was inserted in the bag and remaining viscoelastic was removed. Anterior chamber was reformed with BSS(balanced salt solution) through side entry and sealed by stromal hydration. Main wound was checked for any leakage then conjunctiva is closed using cautery. Subconjunctival injection of dexamethasone and gentamycin was given and eye was patched.

Results :

This prospective randomised study included 60 patients who came for an elective cataract surgery by dividing into two groups based on the location of the incision, 30 cases in group TI compared with 30 cases in group SI..

The study included 12 males and 18 females in TI group and 15 males and 15 females in SIgroup. Pre-operatively in the TI group 10(33.3%) had WTR, 18(60%) ATR and 2(6.7%) had no astigmatism.In SI group,15(50%) had WTR astigmatism, 13(43.3%) had ATR and 2(6.7%) had no astigmatism.The difference in the two groups was statistically not significant(p=0.432).

Post-op astigmatism was studied in both the groups using keratometric values on 1st post op day, 2nd week, 4th week and 6th week post operative period. The surgeries shared an ATR drift with superior incision and WTR drift with temporal incision which stabilized by 6 weeks. On the 6th post-op week, in the TI group 20(66.7%) had WTR, 8(26.7%) ATR and 2(6.7%) had no astigmatism. In the SI group 4(13.37%) had WTR, 21(70%) ATR and 5(16.7%) had no astigmatism. The change has been found to be statistically significant (p<0.001) (Table-1).

Analysis of the SIA centroids showed that 1.11D at 178 degree axis of horizontal steeping (or vertical flattening) was induced by making a SI whereas the TI induced a average horizontal flattening (or vertical steeping) of about 0.48D at 86 degrees. Surgically induced astigmatism was significantly higher with superior scleral incision compared to the temporal scleral incision.

The visual acuity on the 6th post-op week in TI group was 20/20 to 20/30 in 24(80%) patients, 20/40 to 20/60 in 5(16.7%), 20/80 to 20/120 in 1(3%) patients. In SI group, visual acuity was 20/20 to 20/30 in 10(33.3%), 20/40 to 20/60 in 17(56.7%), 20/80 to20/120 in 3 (10%) patients and the difference is statistically significant (p<0.001).

The percentage of change in the best uncorrected visual acuity being +80% (20/20-20/30) in TI group compared to +33.3% in SI group.

Discussion:

The patients in the study were of the mean age 60.88± 10.04 in group I(TI group) and 59.12 ± 9.56 in group II(SI group).Gender distribution was nearly equal with total of 27 males and 33 females with no significant preponderance within the two groups and were stastically similar.

Laterality showed no preference with 29 cases operated on right eye while 31 cases on the left eye and the distribution among the groups were statistically similar.

Cataracts were classified based on the hardness of the nucleus. Out of total 60 case: mature (28.30%), immature (70%) and post.subcapular type (1.7%). No significant difference was noted in the types of cataract among the two groups.

Preoperative, visual acuity was recorded and ranged. HMCF (hand movements close to face) was noted in only 6.7% and maximum in CF(counting finger-1-3mts) in 41.7%. It ranged from 20/200 or less in 36.7% and perception of light in 15%. An equal distribution among two groups were noted.

Corneal astigmatism derieved from keratometry readings have been found to correlate well with postoperative astigmatism refractive error according to the study by Maltzman[9].

Among 60 patients preoperatively, 25(41.6%) had WTR astigmatism, 31 (51.6%) had ATR astigmatism and 4(6.6%) had no astigmatism. In comparison, the study done by Vaithanathan V, Kumar A and Subalakshmi[10] of 147 cases showed pre operative predominance of ATR with 109 cases and 38 cases with WTR.

In the present study, there was significant difference in the amount of astigmatism- TI (1.17+/- 0.90) and SI(2.1+/- 0.78) on the 1STpost operative day. The astigmatism gradually reduced in both the groups and on 6th post operative week there was a reduction in the amount of astigmatism in both the groups-TI(0.59+/-0.63) and SI(1.20+/-0.88) and the differences was statistically significant (p<0.001). Similarly Brown SM, Hodges MR , Corona J[11] studied the relaxation of a 6.25 mm scleral wound after cataract surgery and found SIA to decay from 6.71D(day 1-15), 2.71D (day15-30) and 1.93D (day 31-45) also comparable with studies conducted at Department of Ophthalmology, Kushimoto Rehablitation centre , Japan[3]; at Edward S Markness Eye Institution College Of Physician and Surgeon , Columbia University ,Newyork[12].

In the present study, out of the total patients,pre-operatively,in TI group, 10(33.3%) had WTR astigmatism,18(60%) had ATR astigmatism and no astigmatism in 2 (6.7%). At 6th post operative week, TI group had shift to WTR astigmatism 20(66.7%), ATR astigmatism 8(26.7%) and no astigmatism 2 (6.7%). The percentage of change is +33.3% in WTR astigmatism. In SIgroup,pre-operative astigmatism was seen in WTR astigmatism 15(50%), ATR 13(43.3%) and no astigmatism in 2 patients(6.7%). At the 6th week post-operative astigmatism had shifted to 4 with WTR (13.3%0, 21 with ATR(70%) and 5 with no astigmatisim(16.7%). The percentage of change is +26.7% in ATR astigmatism. Similarly, in a study by Zheng L, Merriam J C, Zaider M[12], WTR astigmatism was seen to shift to ATR after 6mm superior linear incision and stabilized over 1.2 months.

In the present study, the mean SIA in TI group was 0.77+/- 0.54 and in SI group it was 1.38+/- 0.51. The difference was found to be statistically significant(p<0.001). Similar study done by Gokhale NS and Sawhney S [13], the mean SIA in superior group was 1.36+/- 1.03 and in temporal group it was 0.40+/-0.4. Kimura etal [14] have shown by vector analysis that SIA in superior incision was 1.41+/-0.72D.

Mean SIA centroids in TI group was 0.48x86 and SI group was 1.11x178 which was similar to study done by Gokhale.NS. and Sawhney.S[13].

In the present study, visual acuity on the first day was almost similar (20/200 or less) 43.3% in the T1 group and 46.7% in S1 group. This could be attributed to corneal edema or presence of air bubble in the anterior chamber or anterior segment reaction. In the 6th week post operative follow up 24(80%) in T1 group had visual acuity of 20/20 to 20/30 and 10 (33.3%) had 20/20 to 20/30 visual acuity in the S1 group . The results are

consistent with previous reports that temporal incision induces small amount of WTR astigmatism and gives early visual rehabilitation to the patients within 6 weeks.

We conclude that post operative astigmatism induced by surgery varied significantly with the location of incision used in MSICS.

Our results showed that a superior incision induces higher magnitude ATR astigmatism while the temporal incision induces lower magnitude WTR astigmatism.

The temporal scleral incision are to be preferred in patients with pre operative ATR astigmatism that develop mostly in old age. Also the visual rehabilitation is early and better uncorrected visual acuity in the temporal scleral incision.

Pre operative corneal astigmatism has a considerable role in the final refractive state of the patient and hence it would be extremely useful to plan the surgery based on preoperative reading in order to avoid worsening in some cases.

Due consideration to the above parameters will allow for minimal post operative astigmatism and good unaided vision comparable with other procedures for a patient undergoing MSICS.

Legends:

Astigmatism (type)	Pre operative	Post Op 1st Day
Temporal incision group (n=30)		
• WTR	10(33.3%)	19(63.3%)
• ATR	18(60%)	10(33.3%)
• Same	2(6.7%)	1(3.3%)
Superior incision group (n=30)		
• WTR	15(50%)	5(16.7%)
• ATR	13(43.3%)	25(83.3%)
• Same	2(6.7%)	0(0%)
P value	0.432	<0.001**

Post - Op Second Week	Post - Op Fourth week	Post - Op Sixth Week	% change
19(63.3%)	18(60%)	20(66.7%)	+33.3%
10(33.3%)	7(23.3%)	8(26.7%)	-33.3%
1(3.3%)	5(16.7%)	2(6.7%)	-
5(16.7%)	5(16.7%)	4(13.3%)	-36.7%
25(83.3%)	22(73.3%)	21(70%)	+26.7%
0(0%)	3(10%)	5(16.7%)	+10.0%
<0.001**	<0.001**	<0.001**	-

Table 1: Comparison of Astigmatism (type) in two groups of patients studied

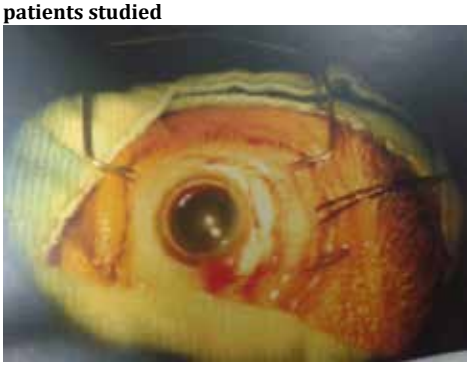

Fig.1- Temporal scleral incision.



Fig.2- Superior scleral incision.

REFERENCE

1. Venkatesh R, Muralikrishnan R, Balent LC, Prakash SK, Prtajna NV. Outcomes of high volume cataract surgeries in developing country. Br. J ophthalmology 2005; 89: 1079-1083. | 2. Merriam JC, Zheng L, Merriam JE, Zaider M, Lindstrom B. The effect of incisions for cataract on corneal curvature, ophthalmology. 2003; 110:1807-1813. | 3.Akura J , Kaneda S , Hatta S , Matsuara K. Controlling astigmatism in cataract surgery requiring relatively large self healing incisions. J cataract and refractive surgery. 2000;26:1650-59. | 4. Abrams D. Ophthalmic optics and refraction. In: Duke-Elder SS,ed.System of ophthalmology.St.Louis,MO:Mosby:1970:671-74. | 5. Alio JL, Agdeppa MCC, Pongo VC. Micro incision cataract surgery with toric intraocular lens implantation for correcting moderate and high astigmatism; pilot study . J cataract Refract surgery. 2010; 36: 44-52. | 6. Richard SC, Bradstein RS, Richard WL. Long term course of surgically induced astigmatism. J.cataract Refractive Surgery.1988;14:270-76. | 7. Cravy TV. Calculation of change in corneal astigmatism following cataract extraction. Ophthalmic surgery.1979;10:38-49. | 8. Holladay JT, Cravy TV ,Koch D. Calculating the surgically induced referactive changes following ocular surgery. J cataract refract surgery.1992;18:429-43. | 9. Maltzman BA, Cinnotti DJ , Horan CA, Rengel AM,posterior chamber implants and post operative refractive astigmatism.CLAOJ 1983;9:229-31. | 10. Vaithianathan V ,Kumar AM, Subalakshmi.Target emmetropia. All India conf.:2007. | 11. Brown SM , Hodges HR , Corona J. Relaxation of post op astigmatism in 6.25mm sclera wound in children . J cataract and referactive surgery. 2001;27(12): 2012-6. | 12. Zheng L, Merrian JC and Zaider M. Astigmatism and visual recovery after " large incision" extra capsular cataract surgery and "small incision" for phacoemulsification.Tr Am Ophth Soc 1997; 95:387-413. | 13. Gokhale NS, Sawhney S. Reduction in manual small incision cataract surgery through change of incision site. Indian J Ophthalmol.2005;53:201-03. | 14. Kimura H, Kuroda S, Mizoguch N, Terauchi M. Extra capsular cataract extraction with a suture less incision for dense cataract. J cataract refracts surg. 2001; 27: 25-30.