Volume : 3 | Issue : 9 | September 2014 • ISSN No 2277 - 8179

Research Paper

A Comparison of Laparoscopic Toupet Versus Nissen Fundoplication in Gerd and/ or Hiatal Hernia

Medical Science

KEYWORDS : Laparoscopic fundoplication; Nissen, Toupet; Gastroesophageal reflux disease; Anti-reflux surgery; Post Operative Bloating.

Dr. Manoranjan Kuswaha — Associate Professor, 3rd Year Resident, Department of General Surgery, Smt. N.H.L. Municipal Medical College, Sheth V.S.General Hospital, Ahmedabad, Gujarat 380007.

Dr. Kushal Shah — 3rd Year Resident, Department of General Surgery, Smt. N.H.L. Municipal Medical College, Sheth V.S.General Hospital, Ahmedabad, Gujarat 380007.

ABSTRACT

Laparoscopic Nissen fundoplication is used very frequently but may lead to postoperative bloating, inability to belch and dysphagia. Partial wrapping has been reported to be equally effective but associated with fewer unfavorable postoperative symptoms. The aim of this retrospective analysis was to compare the results of a 270° wrap (Toupet) and a 360° wrap (Nissen) in patients with gastroesophageal reflux disease (GERD) and/or hiatal hernia.

Introduction : Gastro-oesophageal reflux disease (GORD/ GERD) accounts for upto 75% of the diseases of the esophagus. A hiatal hernia is present in over 80% of patients with GERD. There is no universally accepted definition of the disease.

"GERD is present when the passage of gastric and duodenal contents into the esophagus causes symptoms or damages the mucosa."

"Hiatal Hernia is protrusion of the stomach and upward into the mediastinal cavity through the esophageal hiatus of the diaphragm."

Treatment Goals for GERD and/or Hiatal Hernia are to eliminate symptoms, to heal esophagitis, to manage or prevent complications and maintain remission.

Surgical options available are Nissen's fundoplication, Toupet's partial fundoplication, Belsey mark IV partial fundoplication, Esophagectomy and Colli's Gastroplasty.

I have concentrated my study regarding post operative complications of 22 patients who underwent laparoscopic antireflux surgery in our surgical setup.

Risks or complications following fundoplication surgery include :

- Difficulty swallowing because the stomach is wrapped too high on the esophagus or is wrapped too tightly.
- The esophagus sliding out of the wrapped portion of the stomach so that the valve (lower esophageal sphincter) is no longer supported.
- Heartburn that comes back.
- Bloating and discomfort from gas buildup because the person is not able to burp.
- Excess gas.
- Risks of anaesthesia.
- Risks of major surgery (infection or bleeding).

Methods : The study was retrospective type. In this study a combined approach, comprising both quantitative and qualitative approaches were used to collect, analyze and interpret data. Informed consent was obtained from patients and relatives prior to study. 22 patients of severe GERD and/or hiatal hernia were selected by simple random sampling method, who was admitted in the department of Surgery of Sheth V S General Hospital. 12 of them underwent Laparoscopic Nissen repair and rest 10 underwent Toupet's.

Inclusion Criteria : Patients with persistent or progressive disease inspite of medical treatment, patients with structurally defective LES, Young patients with documented reflux with/ without defective LES and patients with complications of GERD were included in the present study.

Exclusion criteria : Patients who shows improvement with medical treatment were excluded.

Postoperative complications of these 22 patients were assessed.

Principles of anti-reflux procedures:

- Restore sphincter
- Restore abdominal length of LES
- Reconstructed lower end should relax
- on deglutition
- Resistance of LES should not increase beyond the peristaltic power of esophagus.
- No tension

Steps of procedure:

1. Crural Dissection
2. Circumferential Dissection of the Esophagus
3. Fundic Mobilization
4. Preparation of Crural Closure
5. Crural Closure
6. Fundoplication around the Lower Esophagus

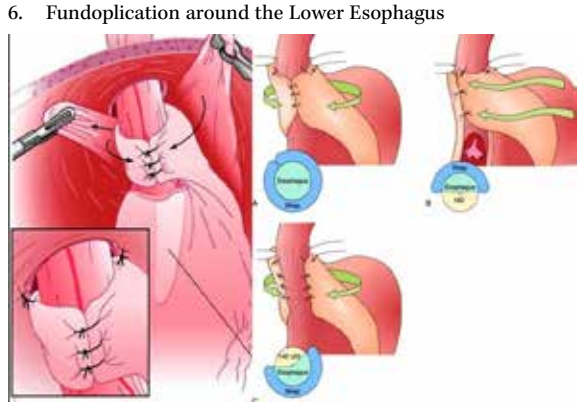

Post operative care :

- Post operative Ryle's tube removal done on POD-2.
- Sips to Liquid orally started on POD-3.
- All oral treatment started on POD-4 along with soft diet.
- Most of the patients had post operative hospital stay of 5-6 days.

Follow up of these patients on the OPD basis was kept for 2 months.

Observations : Major complications were

1. Difficulty swallowing in first 2-3 POD
2. Heartburn – in first 2-3 POD
3. Bloating and discomfort from gas buildup

Incidence of Bloating as post op complication in relation to sex

	Nissen		Toupet	
	Male	Female	Male	Female
	4	8	4	6
Bloating	2	3	1	1
Total	5/12		2/6	

Discussion : In the conducted study, 5 out of 12 who underwent Nissen's repair had post operative complication of Bloating. 3 out of those 5, improved with supportive treatment in immediate post operative period i.e. 15 days. No significant gender specific correlation with incidence of bloating was noted in the study.

All the patients who underwent Nissen's repair were in age group of 25-45 years and so, No age related correlation with post op complication was noted.

1 patient (18 year male) who underwent Toupet's repair had to undergo re-surgery for severe difficulty in swallowing and G.I. discomfort. Pre operative evaluation by endoscopy in this patient revealed that it was because of the stomach was wrapped too high on the esophagus.

1 out of the rest 9 patients developed complication of bloating which was managed successfully with supportive treatment.

Conclusion : My observation suggests that patients with severe bloating symptom before operation are likely (2 out of 3 chance) to experience improvement after laparoscopic antireflux surgery, whereas patients with no bloating or mild bloating preoperatively have a 1 in 3 chance of experiencing worsening of their bloating postoperatively. In the latter group, the exacerbation of bloating is generally very mild and is unlikely to have significant clinical or lifestyle implications for the patient.

Both partial and complete wrapping offer an effective form of therapy for reflux disease with around 80% patient satisfactions with slightly higher rate of bloating in Nissen's repair.

However, results will allow surgeons to better educate the patients about the potential risks of increased bloating after laparoscopic fundoplication.

REFERENCE

• Herbella FA, Tedesco P, Nipomnick I, Fisichella PM, Patti MG. Effect of partial and total laparoscopic fundoplication on esophageal body motility. Surg Endosc 2007; 21: 285-288 | • Booth MI, Stratford J, Jones L, Dehn TC. Randomized clinical trial of laparoscopic total (Nissen) versus posterior partial (Toupet) fundoplication for gastro-oesophageal reflux disease based on preoperative oesophageal manometry. Br J Surg 2008; 95: 57-63 | • Mickevicius A, Endzinas Z, Kiudelis M, Jonaitis L, Kupcinskas L, Maleckas A, Pundzius J. Influence of wrap length on the effectiveness of Nissen and Toupet fundoplication: a prospective randomized study. Surg Endosc 2008; 22: 2269-2276 | • Fibbe C, Layer P, Keller J, Strate U, Emmermann A, Zornig C. Esophageal motility in reflux disease before and after fundoplication: a prospective, randomized, clinical, and manometric study. Gastroenterology 2001; 121: 5-14 | • Zornig C, Strate U, Fibbe C, Emmermann A, Layer P. Nissen vs Toupet laparoscopic fundoplication. Surg Endosc 2002; 16: 758-766 | • Shaw JM, Bornman PC, Callanan MD, Beckingham IJ, Metz DC. Long-term outcome of laparoscopic Nissen and laparoscopic Toupet fundoplication for gastroesophageal reflux disease: a prospective, randomized trial. Surg Endosc 2010; 24: 924-932 |