Volume : 2 | Issue : 6 | June 2013 • ISSN No 2277 - 8179

Research Paper

A Comprehensive Multiparameter Study of Humeral Shaft Fractures Treated by Intramedullary Nailing.

Medical Science

KEYWORDS : Humerus fracture, Intramedullary nail, shoulder problems, screw breakage.

Dr. Rajiv Gupta	(M.S.Orthopaedics), S/o Dr. Vipin Gupta, Aggarwal nursing home, Sadhaura Distt-Yamunanagar, Pin-13320
Dr. Vivek Nayak	(M.S.Orthopaedics), 202/A, Dewan sadan, Veer Savarkar nagar, Vasai (w) Dist-Thane, Pin-401202
Dr.Daivesh Shah	(M.S.Orthopaedics), 401,Sardar centre,Vastrapur Ahmedabad 380015

ABSTRACT

This retrospective study of 24 patients evaluates the results of antegrade cannulated reamed intramedullary interlocking nailing in humeral shaft fractures with a minimum follow-up of 6 months. In 21 patients (88%), primary union was observed. The average time taken for union in closed fractures was 12.8 weeks and in open fractures was 14.1 weeks. 22 patients have excellent or satisfactory recovery of shoulder and elbow function. Hardware failure is most common (17%) complication & is mainly due to breaking of screws. Infection rate was 12%. This study shows that antegrade locked nailing in humeral shaft fracture is an excellent least invasive surgical option available with early fracture consolidation and better union rates.

INTRODUCTION

Fracture of shaft of humerus consists of 3% - 5% of all fractures [1]. Operative management of fracture shaft humerus can be with plate osteosynthesis or with intramedullary nailing [1],[2].

Plate fixation requires extensive open surgery with drainage of hematomas and stripping of soft tissue from the bone. It also provides less secure fixation especially in osteoporotic bone and is associated with increased risk of infection and potential iatrogenic radial nerve injury [3],[4].

Closed intramedullary nailing of fracture shaft humerus theoretically avoids these problems. The interlocking feature of these nails gives rotational stability. The other advantages are minimal surgical trauma, biological osteosynthesis & less operative time [6],[9]. Also biomechanically, nails are subjected to smaller bending loads and are less likely to fail due to fatigue. They act as load sharing devices thus; re-fracture after implant removal is seen less often [6].

In this study, we have tried to analyze outcomes in terms of time for consolidation, union rates, functional results and complications of humeral shaft fractures in 24 patients managed with closed antegrade cannulated reamed intramedullary interlocking nail in a standardized & objective manner.

MATERIALS AND METHODS

This is a retrospective study of 24 cases of humeral shaft fracture treated by closed reduction and intramedullary nailing over a period of 2.5 years (2010-2012). Information was obtained through review of clinical notes, X-rays and operative notes.

The maximum duration of follow up was 24 months and minimum duration was 6 months. In all patients, we have used 'Universal humeral nail' which is antegrade cannulated reamed interlocking intramedullary nail having 5° valgus angle; 7 cm distal to the proximal end.

The exclusion criteria for our study were patients having age < 20 years, patients with recent infections or immunosuppressive therapy and proximal fractures within 2 cms of surgical neck and those within 5 cms of junction of diaphysis and metaphysis, open Gustilo & Anderson grade-III fractures, pseudoarthrosis and fractures with vascular injury.

SURGICAL TECHNIQUE

Patient was placed in supine with head turned to opposite side. After palpation of greater tuberosity, incision was made using minimal invasive approach [13]. This approach avoids injury to rotator cuff. With the help of awl, establish the entry portal just posteromedial to tip of greater tuberosity. A guide wire was passed under IITV guidance maintaining reduction externally. Then, the canal was reamed with cannulated reamers. The nail was slipped over the guide wire and gently advanced until its tip lies 2 cm proximal to the olecranon fossa. The proximal end of the nail must be below the level of the articular cartilage. Proximal locking was done by proximal zig. Then, fracture site was compressed by placing an axial load on the elbow before locking distally. Distal interlocking in antero-posterior direction was done after viewing distal interlocking hole under C-Arm by free hand technique.

OBSERVATIONS AND ANALYSIS

In this study**,** 83% of the patients are male and 50% are labourer by occupation. 50% of the fractures have occurred in 3rd & 4th decade of life. Vehicular accident i.e. high velocity trauma is the most common cause (88%) of fracture humerus. This can be due to a fact that in our society, men are the main bread-winners and are more commonly involved in outdoor activities.

Majority (67%) of the shaft humerus fractures are of closed type. Even in the open fractures, Gustilo type I is more common than type II. This can be due to the fact that there is good muscular envelope surrounding shaft humerus. Right humerus fracture is more common than left side. No patient had bilateral humerus fracture. 80% of the shaft humerus fractures are at middle third level.

Transverse pattern of fracture shaft humerus is most common (45%) followed by spiral configuration of fracture. As most fracture are transverse fractures in this series, so most fracture (46%) are classified as type AO12 A3 as per AO classification.

21% of the cases had other associated injuries like head, chest & abdominal trauma in addition to fracture humerus. 88% of the patients were operated within first 4 days of the admission. 79% of the patients had not required hospital stay for more than 10 days.

Most common (54%) size of nail used is of 24 centimeters and most common (67%) diameter of nail used is of 7 millimeters. Larger nails were avoided to minimize sub-acromial impingement and shoulder pain. 63% have their nails double locked at proximal end & single locked (71%) at distal end.

Volume : 2 | Issue : 6 | June 2013 • ISSN No 2277 - 8179

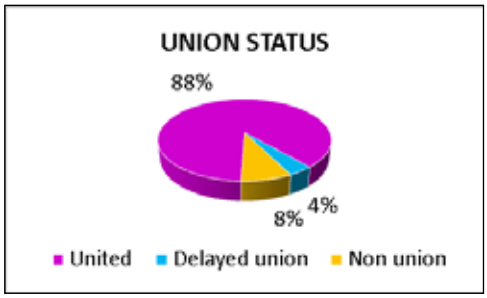

Fig 1: Union status of humerus fracture.

88% of the shaft humerus fractures treated by antegrade interlocking humerus nail got united. Only 8 % of the cases went into non-union. In 88% of the fractures which got united, time taken by 75 % of fractures for union is <24 weeks i.e. 6 months. Only one patient underwent secondary procedure in form of screw removal due to pain.

In 8% of patients, radial nerve palsy occurred after trauma. In one patient, radial nerve palsy occurred after surgery. All radial nerve palsy which occurred after trauma got fully recovered after 8 – 12 months showing neuropraxia type of injury.

67% of the patients have got no complications. Hardware failure is most common (17%) complication & is mainly due to breaking of screws. Infection rate was 12% in this study.

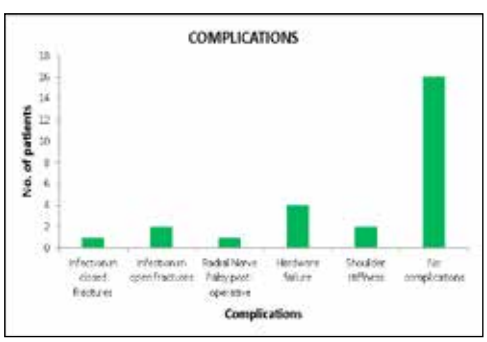

Fig 2: Complications of humerus nailing.

67% of the patients achieved full range of motion at shoulder joint and 25% are having good range of motion. 83% of the patients were returned to their same profession. 84% of patients are fully satisfied with results. 8% are only partially satisfied & 8% are unsatisfied.

To assess function, we used the Disability of Shoulder, Arm and Hand (DASH) score.[5] 84% of the patients have DASH score less than 8% i.e. minimum or no disability of shoulder, arm and hand after treatment of fracture. Only 8% of the patients have DASH score more than 20%.

DISCUSSION

Humeral shaft fractures usually can be treated satisfactorily with non-operative methods[1] but operative stabilization often is necessary for high energy humeral shaft fractures to improve healing, fracture alignment and functional results[6],[7]. In previous studies, the union rate of antegrade interlocking nailing of humeral fractures has ranged from 71% to 100% [3],[8],[9],[10]. These lower union rates among reported clinical results might be due to factors such as over-distraction of the fracture, improper nailing direction or insufficient fixation stability.

In this study, out of 24 cases of open and closed fractures, 21 got united giving the union rate of 88%. This shows the excellent efficacy of antegrade interlocking humerus nails. Out of rest 3 cases, 1 was having delayed union and at subsequent follow-up would have better functional results. Only 2 out of 24 cases (8%) went into non-union.

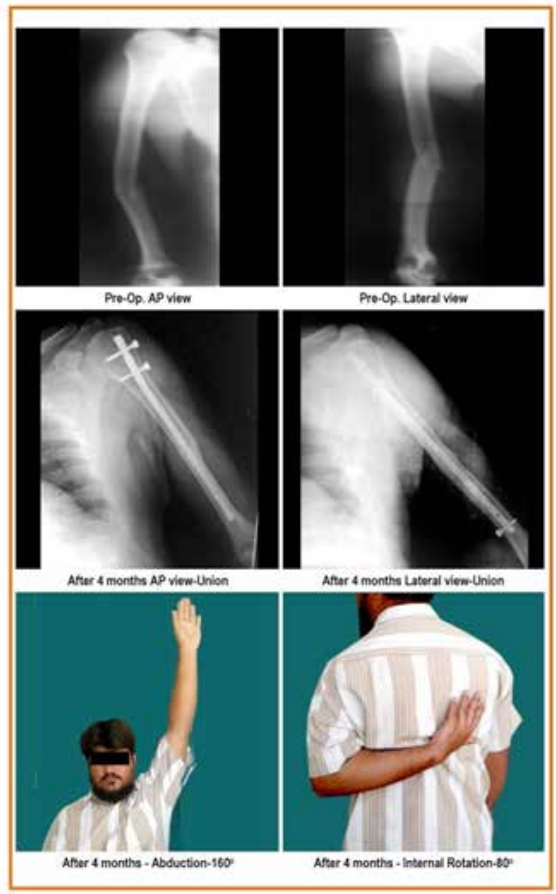

Fig 3: Clinical case no.- 1

The cause of Non-Union in our series was hardware failure in form of distal locking screw breakage leading to rotational instability with distraction at fracture site. In series by Crates and Whittle, 94.5% fractures got united without additional intervention.[3] In Linn and Hou study, 100% fracture union rate was reported.[2]

In 88% of fractures which got united, time taken by 75% of fractures for union was less than 24 weeks i.e. 6 months. 13% fractures took more than 6 months but got united. Overall average time for union was 13.5 weeks. Average time taken for union in closed fractures was 12.8 weeks and in open fractures was 14.1 weeks. Our results are comparable to Crates and Whittle series in which average union time was 14 weeks.[3] Bassi et al had callus formation uniformly by 13 weeks.[11]

The most frequent criticism of antegrade humeral nailing has been its potentially deleterious effect on shoulder function. Out of 24 cases in this study, 67% of cases achieved full range of movement at shoulder joint and 25% of cases had good range of movement. These figures show the benefit of minimal invasive approach while taking entry which avoids rotator cuff injury. Only 2 (8%) cases had unsatisfactory shoulder function with abduction and external rotation limitation >30°. Both of these 2 cases had no proximal nail impingement stating that decreased range of movement at shoulder joint was due to rotator cuff injury. In Crates and Whittle study, 90% cases had full range of painless movement at shoulder joint after an average of 3 months.[3] In Linn and Hou study, 88% patients had satisfactory range of movement at shoulder joint.[2]

In our study, 84% of the patients had DASH score less than 8% suggesting of better outcome of fracture healing by intramedullary nailing. Only in 3 cases (12%) where fracture was not united, DASH score was more than 16%.Fig 4: Clinical case no.- 2

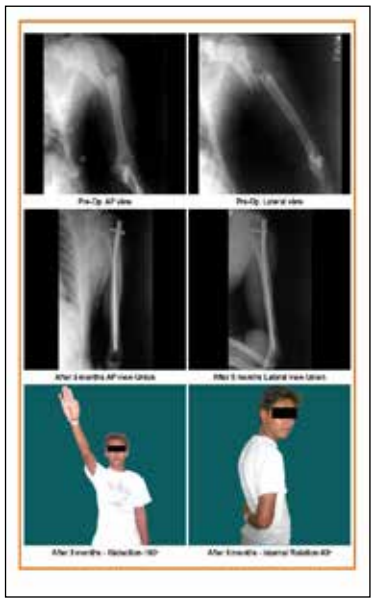

Fig 4: Clinical case no.- 2

CONCLUSION

Closed antegrade interlocking humerus nail is an excellent, safe and reliable mode of treatment for all properly selected closed and open Gustilo I and II humerus shaft fractures. As the soft tissues around the fractures are preserved and hematoma is not drained out, it leads to early union and early mobilization. Complications like non-union can be avoided by intraoperative compression and avoiding distraction at fracture site. Contrary to popular belief, the loss of motion at shoulder is not very significant if proper entry site and technique is used.

REFERENCE

1) Sarmiento A, Kinman PB, Galvin EG, Schmitt RH, Phillips JG. Functional bracing of fractures of the shaft of the humerus. J Bone Joint Surg 1977;59A:596-601. | 2) Lin J, Hou SM. Antegrade locked nailing for humeral shaft fractures. Clin Orthop Relat Res 1999;365:201-10. | 3) Crates J, Whittle AP. Antegrade interlocking nailing of acute humeral shaft fractures. Clin Orthop Relat Res 1998;350:40-50. | 4) Scheerlinck T, Handelberg F. Functional outcome after intramedullary nailing of humeral shaft fractures: Comparison between retrograde Marchetti-Vicenzi and unreamed AO antegrade nailing. J Trauma 2002;52:60-71. | 5) Hudak PL, Amadio PC, Bombardier C. Development of an upper extremity outcome measure: the DASH; The Upper Extremity Collaborative Group (UECG) Am J Ind Med. 1996 Jun;29(6):602-8. | 6) Brumback RJ, Bosse MJ, Poka A, Burgess AR. Intramedullary stabilization of the humeral shaft fractures in patients with multiple trauma. J Bone Joint Surg Am 1986;68:960-70. | 7) Henley MB, Chapman JR, Claudi BF. Closed retrograde Hackethal nail stabilization of humeral shaft fractures. J Orthop Trauma 1992;6:18-24. | 8) Hems TE, Bhullar TP. Interlocking nailing of humeral shaft fractures: The Oxford experience 1991 to 1994. Injury 1996;27:485-9. | 9) Ikpeme JO. Intramedullary interlocking nailing for humeral fractures: Experiences with the Russell-Taylor humeral nail. Injury 1994;25:447-55. | 10) Ingman AM, Waters DA. Locked intramedullary nailing of humeral shaft fractures.J Bone Joint Surg 1994;76B:23-9. | 11) Bassi J.S. et al: Unreamed humeral nailing in fracture shaft of humerus with a new distal targeting device,IJO- Vol 33, No.1 Jan 1999, P:54-57. | 12) Park JY, Pandher DS, Chun JY, Md ST. Antegrade humeral nailing through the rotator cuff interval: a new entry portal.J Orthop Trauma.2008 Jul;22(6):419-25. | | | |