Research Paper

Volume : 4 | Issue : 11 | November 2015 • ISSN No 2277 - 8179

Medical Science

KEYWORDS : Paediatric, Penetrating Injury

A Prevalence of Penetrating Ocular Trauma in Paediatric Age Group

Chaudhari Sagar V — Dr. Vasant Chaudhari Hospital, Timber Market, Bhusawal, Dist.- Jalgaon, Maharashtra. Pin – 425201

Waghmare Rohini B. — Dr. Vasant Chaudhari Hospital, Timber Market, Bhusawal, Dist.- Jalgaon, Maharashtra. Pin – 425201

ABSTRACT

Purpose: *To study the various ocular injuries, clinical features and visual outcome in paediatric age group.* ***Materials & Methods:*** *In this study total 50 patients with penetrating injury (up to 15 Years) were screened. The age and sex of the patient, history, general, systemic and ophthalmological examination was done. Time, object and circumstances of the injuries were noted. Slit lamp examination, fundus examination, vision, Routine examination and radiological examination were done.* ***Results:*** *Highest incidence 48% of penetrating injury was seen in age group of 6-10 years. Incidence of injury was higher in males 74% as compared to female. Children at play or sports were victims of penetrating injury in 40% of the cases. Domestic injuries 32% and agricultural injuries 24% were other major injuries. The maximum number of patients had corneal tear size of 4-6mm. 62%patients had iris prolapse and scleral tear seen in 24% of patients. Vitreous hemorrhage was observed in 10% of total patients. Retinal detachment, traumatic endophthalmitis and retinal tear observed in each 2 patients. 6 patients were developing phthisis. In 2 patient's enucleation was done.* ***Conclusion:*** *Common object causing injuries were stick 34%, wooden arrow 30%, thorn 18% and metal wire 10%. Injuries restricted to anterior segment formed majority of penetrating injuries. Maximum corneal injuries 76% of these 60% were limited to cornea and 16 % were cornea-scleral. The site and size has got direct relation with visual outcome. The tears of larger size and placed to affect center of cornea have poor visual results.*

INTRODUCTION-

An Injury is damage to a person or to a tissue/organ, e.g. the eye, caused by transfer of energy- mechanical, thermal, chemical, electrical or radiant. Consequently, eye injuries include all damage caused to the eye and its adnexa, orbit and periorbital tissue due to direct contact with fixed or mobile, blunt or sharp objects (mechanical energy being transferred e.g. by rapid deceleration), hot objects (thermal), chemical substances, sources of electrical power or different type of radiation (UV, X-ray, microwave) [1]

The eye ball is a fairly well protected structure in our body. There are anatomical as well as physiological factors for its protection. The bony orbit and its elastic fatty tissue are the anatomical factors protecting it. Physiologically it is protected by blink reflex, head turning reflex, and the lacrimation which follows intrusion of any irritant material. Despite these protective mechanisms injuries to the eye are commonly found.

Human, social and economic consequences of the injury are enormous. Ocular injuries comprise a group of disorders with wide variation in clinical presentation, cause and visual outcome.

Penetrating injury is defined as single laceration of the eyeball usually caused by a sharp object. [2] Most penetrating injuries are encountered in the course of occupation, but there increases in incidence in childhood. In fact, in paedritric age group commonest cause of monocular blindness. This is due to in part to the child's natural curiosity and inexperience but also to be the lack of awareness of potential danger on the part of parents and toy manufacture. In terms of loss to the society of productive human being due to visual impairment, childhood blindness contributes significantly.

Since the total number of blind years suffered by a blind child is more than suffered by a person who become blind in adulthood or in old age.

The purpose of this study is to known causes, clinical features of various ocular injuries in paedritic age group.

Materials and method-

Study was conducted at Department of Ophthalmology, in a tertiary care teaching hospital located in rural area of western Maharashtra. 50 patients in pediatric age group (up to 15 years) with penetrating ocular injuries were studied during a period 2 years. These patients were admitted in the hospital and were studied to evaluate the causes, clinical features and visual outcome after management. After the discharge from the hospital patients were followed up in OPD basis up to 6 months.

A detailed history of each patient was obtained from either patient or the relative. Each patient was evaluated according to name, age, sex, chief complaints, time of injury and object of injury. general examination, systemic examination, fundus examination and ophthalmic examination were done.

The slit lamp examination includes lids, conjunctiva, cornea, anterior chamber, iris, pupil and lens were done. A complete detail examination was carried out with the help of torch light (and slit lamp wherever possible). Rough assessment of vision was done in all patients with torch light, pre-school children (3-5 years) was done by illiterate E-cutout test. Measurement of vision in school children (above 5 years) was done with Snellen's chart. Investigations like Hb, urine routine, BSL, X-Ray of the orbit and in selected cases B-Scan, CT-scan was done.

Results-

Table no-1

Showing age incidence

Age groups in years	No. of patients	Percentage
0-5	09	18
6-10	24	48
11-15	17	34
Total	50	100

The present study shows highest incidence (48%) of penetrating ocular injury in the age group 6-10 years.

Table no-2

Showing sex incidence

Sex	No of patients	Percentage
Male	37	74
Female	17	26
Total	50	100

In the present study, incidence of penetrating eye injury was found to be more in males (74%) as compared to females (26%)

Graph no-1

Showing the type of injury

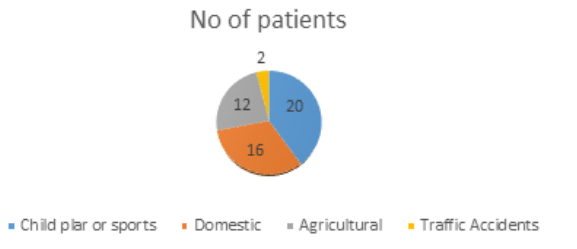

In the present study injuries at play or sports were 40%. Domestic injuries constituted 36% while agricultural injuries constituted 24%.

Graph no -2

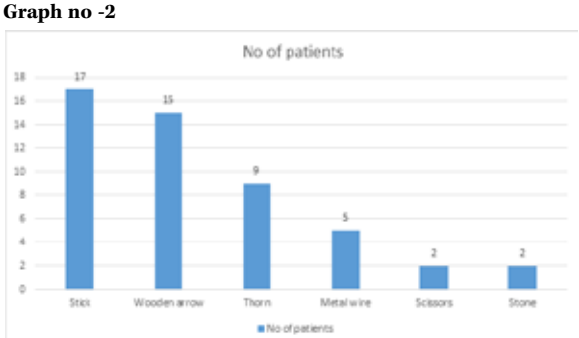

Showing the object causing penetrating injury

In the study common causes of penetrating injuries were stick (34%), wooden arrow (30%), thorn (18%) and metal wire (10%).

Table no-3

Showing anterior segment injury

Structure involved	No of patients	Percentage
Cornea	30	60
Sclera	12	24
Cornea and sclera	08	16
Prolapse uveal tissue	31	62
Lens	26	52

Several patients had involment of multiple structure.

In the present study injuries restricted to cornea constituted 60% while cornea – scleral injuries were 16 %. Prolapse of uveal tissue was found in 62% of the total number patient (uveal tissue prolapse was seen in 15 patients of corneal tear, 8 patients of scleral tear and 8 patient sod corneal scleral tear).

In the present study lens was affected in 52% of the total number of patients.

Traumatic cataract was seen in 42 % patients. In 4 patient's cataracts lens was subluxated.

Table no-4

Showing posterior segment injury

Structure involved	No of patients	Percentage
Vitreous prolapsed through wound	17	34
Vitreous hemorrhage	5	10
Endophthalmitis	2	4
Macular Oedema	20	40
Retinal Detachment	2	4
Retinal tear	2	4

Macular oedema was observed in maximum number of patient (40%). In the study vitreous prolapse through the wound was observed in 34%.

Table no-5

Showing visual outcome in relation to to the size of corneal or sclerocorneal tear

Size in mm	6/12 or better	6/18-6/60	6/60or less	phthisis	enucleation	undetermined	No of patients
0-2	7	1	-	-	-	2	10
2-4	6	4	1	-	-	2	11
4-6	-	8	6	-	-	-	16
6-8	-	-	3	1	-	-	5
>8	-	-	2	4	2	-	8
total	13	13	12	6	2	4	50

In the present study final visual outcome was 6/12 or better in87.5% of the patients having 0-2 mm size of the corneal tear. The same visual outcome was observed in 54.54% of the patients having corneal tear size of 2-4mm.

In patients with corneal tear size of 6-8mm 60% patients had final visual outcome of 6/60 or less.

In patients with corneal tear size more than 8mm, only 25% patients had functional visual outcome i.e.6/60 or less.

Corneal laceration with rupture of ant capsule

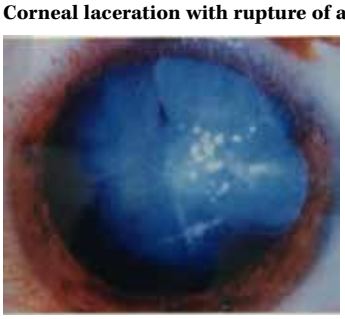

Penetrating injury with hyphema



Scleral tear with uveal prolapse



Volume : 4 | Issue : 11 | November 2015 • ISSN No 2277 - 8179

Lacerating eye trauma with cornea, lens and vitreous involment

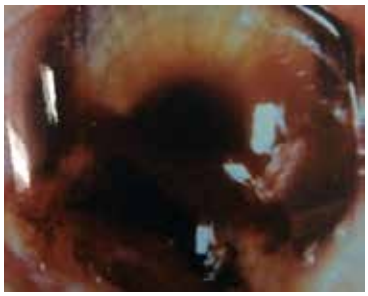

Cornea scleral tear with iris and vitreous prolapse

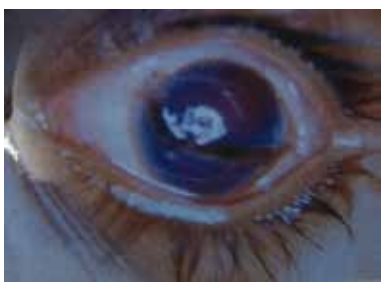

Peripheral corneal tear with traumatic cataract



Discussion –

In the study, 50 patients in paediatric age group with penetrating ocular injuries were studied. Age incidence of penetrating ocular injuries was found in the age group of 6-10 years (48%). In 11-15 years' age group it was 34%. Dasgupta S, Mukherjee R, Ladi DS, Gandhi VH [3] found the incidence of penetrating ocular injuries to be 45.45% in the age group of 6-10 years. Rapoport I, Romen M, Kinek M, et al [4] found almost half of the penetrating ocular injuries sustained by children in the age group of 6-12 years. DeResinis PA, Caputo AR, Fiore PM [5] found incidence of penetrating ocular injuries to be 31% in the age group of 11-15 years.

Sex incidence of penetrating ocular injuries was found to be more in males (74%) as compared to females (26%). This may be because of more exposure of male in lay, sports, accidents. The finding in this study were in close correlation with the following studies, Alfaro BV, Chaudhary NA, Walonker AF et al [6] found the incidence of 73% in male and 27% in female. NIramen [7] found the incidence of 78% in male and 22% in females. LA Roche GR, L, Schertzer RM [8] found the incidence of 78% males and 22% in females.

In my study injuries sustained at play or sports were 40%. In Luff Aj, Hodgkin PR et al [9] in their study of aetiology of penetrating injury in 143 patients found incidence of injury to be 34% with child at play or sports. Hasnain SQ, Kirmani M [10] found that children at play were most vulnerable (33.3%) for penetrating eye injury in their study.

In my study incidence of domestic injuries was 32%. Luff AJ, Hodgkind PR [9] et al found the incidence of domestic injury to be 34% and Rapoprt I, Romen M et al [4] reported the incidence of domestic injury to be 38.15%.

In my study, agricultural injuries were 24%. Umesh RE, UMesh OC [11] reported 10.1% during farm work. The high incidence in our study 24% is probably due to rural area where farming is the main occupation. Children were playing in the farm or engaged in agricultural parasites at the time of injury.

In my study common causes of penetrating injuries were stick (34%), wooden arrow (30%), thorn (18%), metal wire (10%). In Dasgupta S, Mukherjee R, Ladi DS, Gandhi VH [3] reported that pointed objects sticks, wires etc. were common causative agents, the recent trend being bow and arrow injuries in their study of "paediatric ocular trauma – a clinical presentation".

Corneal injuries (76%) constituted the greatest bulk of this study. Injuries restricted to cornea constituted 60% while cornea scleral injuries were 16%. On statistical ground it could be said that corneal injuries are the commonest penetrating injuries. his is probably due to the fact that being the most anteriorly situated structure of the eye. It is most vulnerable to various types of injuries. According to Arnold Sorby [12] approximately 66% of penetrating wounds of the eye through cornea and 24% are corneoscleral. Bigar F [13] in his study reported that in53% patients wound was limited to cornea and in 18% there was combined cornea scleral wound.

Sclera was injured in 24% of the patients included in the present study. All scleral injuries were in the form of scleral tear in 66.6% of the patients with scleral tear indicating more severe grade of injury. In Bigar F [13] in his analysis of 100 cases of penetrating injuries reported in 29% of the patients wound was limited to sclera. According to Parver LM [14] et al the most frequent type of tissue damage included corneal or scleral laceration.

In my study, iris prolapse was seen in 62% of the patients with cornea or sclerocorneal tear. In Michael Ilsar, Moses Chirambo and Michael Belkin [15] who found iris prolapse in 57.35% of patients with penetrating eye injury.

In my study, lens was affected in 52% of the total patients. The commonest lesion was traumatic cataract (42%). Hashain SQ, Kirmani M [10] in their retrospective study of penetrating ocular trauma found traumatic cataract in 50% of the patients with penetrating eye injury. In Rene

Muga, Eugenio Maul [16] found lens famage in 30% patients of penetrating eye injuries.

In my study vitreous hemorrhage was observed in 10% of the total number of patients. In bigar F [13] who reported that vitreous was injuried in one third of the cases of penetrating injuries of eye.

Two patients had retinal detachment initially both the patients had been treated with corneascleral tear. Both of these patients were treared with cryopexy. The tear was sealed and did not progress to retinal detachment.

In my present study, endophthalmitis was seen in two patients. The visual outcome depend upon the site and size of injury, extent of ocular damage, which is the most important factor, and period between time of injury. Site of injury affects the final visual outcome. Those injuries which damage the structure in visual axis lead to poor visual outcome.

In this study, corneal injuries involving the central pupillary

area. In my present study, injuries involving central part of the cornea had low final visual acuity as compared to those injuries not involving the central part of cornea. According to Umesh RE, Umesh OC [11] in penetrating injuries visual outcome was worse when posterior segment was involved than when injury involved only anterior segment.

AL_salem M, Ismail L studied [17] 194 children with eye injuries. out of 194, 47 were perforating injuries. dasgupta S et al [3] showed that out of 44 cases studied only 1 patient were

found to have visual acuity better than 6/18.

Conclusion-

In paediatric age group less than 15 years' ocular injuries are the commonest cause mono-ocular, preventable blindness. In children penetrating injuries are most commonly seen when they are at play. In rural area where farming is the main occupation, agricultural injuries are very commonly seen.

In the anterior augment injuries, corneal injuries formed a significant proportion of penetrating trauma. Corneal tear of larger size and placed to affect center of cornea results in poor visual outcome. Visual outcome better when only anterior segment involved.

In patients with traumatic cataract visual outcome is better where intraocular lens implant done in time. Children form an impartment population with respect to eye injuries. 'incidence of penetrating eye injuries can be decreased by considering certain preventive measures. Proper and repeated education of the children by parents of the hazards due to the injury, will go a long way in preventing such injuries.

REFERENCE

1) A-D Negrel: Magnitude of eye injuries worldwide, community health eye 1997: 10(24): 49-53. | 2) Kuhn f, Morris R, Witherspoon D, Heimann K, Jeffers JB, Trister G, A standardized classification of ocular trauma. Opjthalmol,1999; 103:240-243. | 3) Dasgupta S, Mukherjee R, Ladi GS, Gandhi V H: Paediatric ocular trauma- a clinical presentation. J Postgrad Med 1990 Jan:36 (1);20-2. | 4) Rapaport I, Roman m, Kinek M,Koval R,Teller J, Belkin M, Yelin N, Yanco L, Savir H; eye injuries in children Israel. A nationwide collaborative study, Arch ophthalmol1990 Mar,108(3) : 376-9. | 5) DeRespinis PA, Caputo AR, Fiore PM, Wagner RS, A survey of severe eye injuries in children. Am J Dis Child 1989 JUN ;143 (6) :711-6. | 6) Alfavo DV, Chaudhary NA, Walonkar AF, Runyan T, Saito Y, Liggett PE: Penetrating Eye Injuries in Young Children, Retina 1994:14 (3):201-5. | 7) Niramen M, Perforating Eye Injuries Treated at Helsinki University Eye Hospital 1970 to 1977, Ann Ophthalmol 1981 Aug;13(8):957-61. | 8) LaRoche GR, McIntyre L, Schertzer RM: Epidemiology of Severe Eye Injuries in Childhood. Ophthalmology 1988 Dec; 95 (12):1603-7. | 9) Luff AJ, Hodgkin's PR< Baxter RJ, Morrell AJ< CAlDER J: Aetiology of perforating eye injury. Arch Dis Child 1993 May; 68(5):682-3. | 10) HAsnanin SQ, Kirmani M: A 5 Years Retrospective Study of Penetrating Ocular Trauma at the Aga Khan University Hospital, Karachi. JPMA J Pak Med Assoc 1991 Aug; 41(8); 189-91. | 11) Umesh RE, Umesh OC: Causes Visual Outcome of childhood eye Injuries in Nigeria. Eye 1997,11(pt4):489-95. | 12) Arnold Sorby: Modern Ophthalmology. Vol 3, 2nd edition, Butterworth and Co. (publishers)Ltd .1972; 452-453. | 13) Biger F: Primary Wound Closure after Eye Injuries. An Analysis of 100 cases, Klin Monatsbl Augenheilkd 1981 Apr;178 (4):299-302. | 14) Parver LM, Dannenberg Al, Blacklow B, Fowler CJ, Brechner RJ, Tielsch JM: Characteristics and causes of penetrating eye injuries reported to the National Eye Trauma System Registry, !985-91. Public Health Rep !993 Sep-Oct; 108(5);625-32. | 15) Michael IIsar, Moses Chirambo, Michael Belkin: Ocular injuries in Malaawi.Br. J, ophthalmol1982;66:145-148. | 16) Rene Muga, Eugenio Moul: The Management of Lens Damage in Perforating Corneal Laceration. Br J. Ophthalmol 1978; 62; 784-787. | 17) AL-salem M, Ismail L: Eye Injuries Among Children in Kuwait: Pattern and outcome, Ann TROP Paediatric 1987 dec:7(4):274-7. |