ORIGINAL RESEARCH PAPER

Volume-7 | Issue-6 | June-2018 | PRINT ISSN No 2277 - 8179

INTERNATIONAL JOURNAL OF SCIENTIFIC RESEARCH

A PROSPECTIVE STUDY TO EVALUATE THE ANALGESIC EFFICACY OF QUADRATUS LUMBORUM BLOCK AFTER INGUINAL HERNIA SURGERY

Anesthesiology

Dr. Rajmala Jaiswal Senior Professor, M.D., Department of Anaesthesia PGIMS Rohtak India

Dr Nitu Yadav* Postgraduatestudent 3rd year, Department of Anaesthesia PGIMS Rohtak India. *Corresponding Author

ABSTRACT

INTRODUCTION

We present a study in which fifty male patients between 30-60 years, undergoing inguinal hernia under spinal anaesthesia were included. Quadratus Lumborum (QL) block type 2 was given in study group (n=25). Postoperative analgesia of study group was compared with control group (n=25).

MATERIALAND METHODS

After completion of surgery under spinal anaesthesia, ultrasound guided QL block was performed on the ipsilateral side.

OBSERVATIONS AND RESULT

When compared between the two groups time for the first PCA demand and mean total fentanyl consumption, there was clinically and statistically significant difference ($p < 0.001$).

CONCLUSION

We conclude that QL block is effective in providing post operative pain relief after inguinal hernia surgery

KEYWORDS

Inguinal hernia, Quadratus lumborum block

INTRODUCTION

Ultrasound (US) guided nerve blocks were first described by La Grange et al in 1978, when they performed supraclavicular brachial plexus blocks using a doppler device.[1] US guided Quadratus Lumborum (QL) block is a new approach and is performed ultrasonographically at the level of Quadratus lumborum muscle into thoracolumbar fascial plane,[2] this block provides wider spread of local anaesthetic from dermatome T5 to L1.[3] Blanco first described US guided QL block in 2007 at Europian Society of Regional Anaesthesia (ESRA) , Annual Scientific meeting as infiltration of local anaesthetic solution near anterolateral & posteromedial aspect of Quadratus lumborum muscle.[4] We present a study in which fifty male patients between 30-60 years, belonging to American Society of Anaesthesiologists (ASA) physical status I & II undergoing inguinal hernia under spinal anaesthesia were included. QL block was given in study group (n=25). Postoperative analgesia of study group was compared with control group (n=25) using PCA (Patient controlled Analgesia) fentanyl consumption and Linear Visual Analogue Scale (VAS) score in first 24hours postoperatively.

MATERIALAND METHODS

This prospective, randomized and comparative study , fifty male patients between 30-60 years, belonging to American Society of Anaesthesiologists (ASA) physical status I & II undergoing inguinal hernia under spinal anaesthesia were included.

Patients were randomly allocated to two groups comprising of 25 patients each group. Ultrasound guided ipsilateral QL block was administered in the study group, group QL (n=25) recieved 15ml of 0.25% bupivacaine. The control group, group C (n=25) did not receive the block.

The purpose and protocol of study was explained to patients and informed & written consent was obtained. Spinal anaesthesia was given using 2.6ml of 0.5% bupivacaine heavy. Surgery was commenced after desired level of anaesthesia at T8 was achieved. Intraoperative HR, ECG, NIBP & SpO2 were monitored.

After completion of surgery ultrasound guided QL block was performed on the ipsilateral side. Patient was positioned left lateral for right sided block & vice versa. Under all aseptic conditions, ultrasound probe was placed horizontally between the coastal margin and the iliac crest. Images were obtained using a Sonosite M Turbo ultrasound machine with a 6-13MHz HFL linear array probe placed on the iliac crest. The 3 muscle layers of the abdominal wall were identified: external oblique, internal oblique, and transversus abdominis muscles in the anterior axillary line. The probe was moved towards the mid axillary line and at this juncture the layers appeared to taper. When the probe was moved towards the posterior axillary line as per posterior approach, sonoanatomy showed first the transversus abdominis disappearing then the internal oblique and external oblique forming aponeurosis and appearance of quadratus lumborum was noticed. The fascia surrounding the transversus abdominis muscle was tracked posteriorly to its origin, where the transversus abdominis muscle merged with the thoracolumbar fascia surrounding the quadratus lumborum muscle (image 1). A 23G spinal needle was inserted in plane with the ultrasound probe and targeted towards the posteromedial aspect of QL muscle. Normal saline 3ml was used to identify the splitting of the fascia (hydrodissection). Fifteen ml of 0.25% plain bupivacaine was injected in the posteromedial aspect of QL muscle after negative aspiration and the drug was seen spreading around the quadratus lumborum muscle.

Patients were transferred to the recovery room. In both the groups postoperative HR, NIBP & SpO2 and respiratory rate were monitored every 15 minutes till 1 hour and monitoring continued for next 24hours. The presence and severity of pain was assessed by an investigator blinded to group allocation, using a Visual Analogue Scale (VAS, 10 cm line in which 0cm = no pain and 10cm =worst pain imaginable). All patients were asked to score their pain at rest and on movement (dynamic) 0, 2, 4, 6, 12 & 24 hours after surgery. PCA fentanyl bolus dose 20 µg was given as rescue analgesic when VAS score is ≥4. In surgical ward PCA fentanyl dose 10µg with lockout interval of 15 minutes was given as and when required. Total consumption of fentanyl was noted over 24hours.

The primary outcome measure in the study was 24 hours PCA fentanyl consumption. Secondary outcome measures included: Time to ask for first analgesic, nausea, VAS score, sedation score, antiemetics required, respiration rate < 10 and any other side effects. Any episode of hypotension (decrease in MAP≥ 10% of baseline value), bradycardia (HR< 60/min), nausea or any other side effect as a result of QL block or fentanyl use, were recorded and managed.



Image 1: Ultrasonographic view of Quadratus lumborum muscle (TA- Tranversus Abdominis; QL- Quadratus Lumborum; IO- Internal Oblique; EO- external Oblique muscle)

STATASTICALANALYSIS

At the end of the study all the data was compiled and analysed statistically. The SPSS Version 17.0 statistical package was used for statistical analysis. Unpaired t test was used to test the difference in age, weight, height, duration of surgery, postoperative vitals (pulse rate, blood pressure and SpO2), first PCA demand after surgery and VAS score at rest and on knee flexion in between the two groups. Mann Whitney U test was used to compare total fentanyl consumption in between the two groups. Chi square test was used to compare the patient satisfaction level and postoperative complications such as nausea, sedation, hypotension and bradycardia. Results were considered statistically significant if the p value was ≤ 0.05.

OBSERVATIONS AND RESULTS

Both the groups were comparable regarding patient demographic profile (age, weight and sex distribution) and postoperative hemodynamic parameters, there was no statistically significant difference ($p > 0.05$) between the groups.

Mean time for first PCA demand in group C was 2.52 ± 0.76 hours and in group QL was 4.92 ± 1.77hours. When compared between the two groups time for the first PCA demand, there was clinically and statistically significant difference ($p < 0.001$) [Figure 1]. Mean total fentanyl consumption in group C was 394.80 ± 114.42 µg and in group QL was 172.80 ± 71.04µg. Analysis of data in between the two groups was done using Mann Whitney test and was clinically and statistically significant ($p < 0.001$) [Figure 2]. When VAS scores were compared between the two groups: the VAS scores at rest and on knee flexion were significantly lower in block group (QL) at all the times except at 0hr ($p < 0.05$). Postoperative Complications such as nausea, sedation, hypotension and bradycardia after the surgery in the first 24 hours was recorded of all the patients and were comparable regarding the complications and there was no statistical significant difference ($p > 0.05$) in both the groups. Patient satisfaction was clinically and statistically significant between the two groups ($p < 0.001$).

Figure 1: First PCA Demand

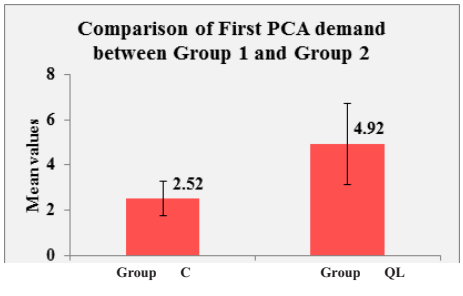

Table 2: Total Fentanyl Consumption

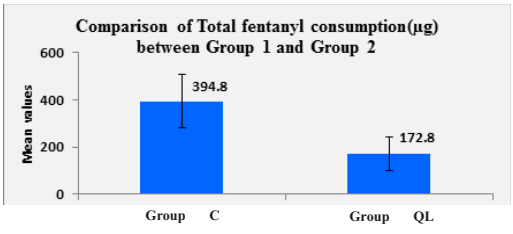

DISCUSSION

Inguinal hernia is a commonly performed surgical procedure,[5] associated with substantial postoperative pain and discomfort to the patients.[6] A multimodal postoperative pain treatment regimen is usually given to these patients that provide high quality analgesia with minimal side effects. Various analgesic drugs are used for postoperative pain relief after abdominal surgeries such as opioids, NSAIDs, α-2 agonist, paracetamol etc. Their use for postoperative analgesia is associated with various side effects like pruritis, nausea, urinary retention and respiratory depression, gastrointestinal bleed and ulcer.[8]

Various peripheral nerve blocks like ilioinguinal block, TAP block, iliohypogastric block etc. are used to relieve postoperative pain after inguinal hernia surgeries.[9] Ilioinguinal and iliohypogastric nerve blocks involve blocking of ilioinguinal and iliohypogastric nerve (L1) and cover inferior abdominal wall only.[10] In TAP block anaesthetic solution spreads upto anterior abdominal wall only. So TAP block provides good somatic analgesia but no visceral blockade.[11]

Quadratus Lumborum (QL) block is a new approach and is performed ultrasonographically at the level of Quadratus lumborum muscle into thoracolumbar fascial plane,[2] this block provides wider spread of local anaesthetic from dermatome T5 to L1.[3] QL block there is more widespread of anaesthetic solution in paravertebral space and posterior abdominal wall which may be responsible for its greater extent of analgesia and also longer duration of pain relief after QL block in comparision with TAP block.[2]The use of ultrasound was introduced to improve the success rate and accuracy of TAP block and to prevent potential complications.

The analgesic efficacy of QL block for postoperative analgesia in patients undergoing abdominal surgery has been demonstrated in various clinical trials. Blanco et al (2014) performed a randomized control clinical trial to study analgesic efficacy of QL block for postoperative pain after caesarean section as a part of multimodal approach.[2] The results of our study are in concordance with those of Blanco et al.

CONCLUSION

We conclude that QL block is effective in providing post operative pain relief after inguinal hernia surgery. First dose of fentanyl used, as well as total fentanyl consumption over 24 hours postoperatively was reduced in patients with QL block. No complication related to block was seen as block was under ultrasound guidance leading to infusion of drug after visualizing the needle tip and relevant anatomical structures. No difficulty in performing the QL block was seen in any of our patient. However more studies need to be done involving large number of patients to evaluate the minimal dose of bupivacaine in QL block and to establish its role in inguinal hernia surgery.

REFERENCES

1. La Grange PD, Foster PA, Pretorius LK. Application of the Doppler ultrasound blood flow detector in supraclavicular brachial plexus block. Br J Anaesth. 1978 Sep 1;50(9):965-7.
2. Blanco R, Ansari T, Girgis E. Quadratus lumborum block for postoperative pain after caesarean section: a randomised controlled trial. Eur J Anaesthesiol. 2015 Nov;32(11):812-8.
3. Carney J, Finnerty O, Rauf J, Bergin D, Laffey JG, Mc Donnell JG. Studies on the spread of local anaesthetic solution in transversus abdominis plane blocks. Anaesthesia. 2011 Nov 1;66(11):1023-30.
4. Blanco R. Tap block under ultrasound guidance: the description of a "no pops" technique: 271. Reg Anesth Pain Med. 2007 Sep 1;32(5):130.
5. Jenkins JT, O'Dwyer PJ. Inguinal hernias. BMJ. 2008;336:269-72.
6. Toivonen J, Permi J, Rosenberg PH. Analgesia and discharge following preincisional ilioinguinal and iliohypogastric nerve block combined with general or spinal anaesthesia for inguinal herniorrhaphy. Acta Anaesthesiol Scand. 2004;48:480-5.
7. Jin F, Chung F. Multimodal analgesia for postoperative pain control. J Clin Anesth. 2001 Nov;13(7):524-39.
8. Wang Y, Wu T, Terry MJ, Eldridge JS, Tong Q, Erwin PJ, et al. Improved perioperative analgesia with ultrasound-guided ilioinguinal/iliohypogastric nerve or transversus abdominis plane block for open inguinal surgery: a systematic review and meta-analysis of randomized controlled trials. J Phys Ther Sci. 2016 Mar; 28(3): 1055–60.
9. Yarwood J, Berrill A. J Nerve blocks of the anterior abdominal wall. Br J Anesth. 2010 Dec 1;10(6):182-6.
10. Carney J, Finnerty O, Rauf J, Bergin D, Laffey JG, Mc Donnell JG. Studies on the spread of local anaesthetic solution in transversus abdominis plane blocks. Anaesthesia. 2011 Nov 1;66(11):1023-30.