Volume : 3 | Issue : 7 | July 2014 • ISSN No 2277 - 8179

Research Paper

A Randomized Controlled Trial to Compare Efficacy of Ultrasound Therapy With End Range Mobilization Over Ultrasound Therapy With Capsular Stretching in Frozen Shoulder

Medical Science

KEYWORDS : Frozen shoulder, End Range Mobilization, Capsular Stretching, Ultrasound therapy.

Balbir Kaur	University College of Physiotherapy, Baba Farid University of Health Sciences, Faridkot, Punjab
Reena Arora	University College of Physiotherapy, Baba Farid University of Health Sciences, Faridkot, Punjab
Lalit Arora	University College of Physiotherapy, Baba Farid University of Health Sciences, Faridkot, Punjab
Sandeep Kumar	University College of Physiotherapy, Baba Farid University of Health Sciences, Faridkot, Punjab
Aseem Khajuria	University College of Physiotherapy, Baba Farid University of Health Sciences, Faridkot, Punjab

ABSTRACT

Frozen shoulder clinically referred to as adhesive capsulitis, has been described as a condition of unknown etiology and characterized by gradually progressive, painful restriction of shoulder joint motion with spontaneous restoration of partial or complete motion over months to years.In the physical therapy setting, physical therapists utilize a variety of interventions to treat patients with adhesive capsulitis.At present various interventions are available to treat frozen shoulder. However, there are not many studies that have analysed the effects of end range mobilization and capsular stretching in the treatment of frozen shoulder. The aim of the study was to find out the effectiveness of end range mobilization and capsular stretching on pain and functional disability in frozen shoulder.Thirty subjects were randomly assigned into 2 groups. Both groups received treatment of 6 days a week for 4 weeks. Group A received end range mobilization and ultrasound therapy for 10 minutes, whereas group B received capsular stretching and ultrasound therapy for 10 minutes. Outcomes were evaluated by visual analog scale, shoulder pain and disability index and range of motion. Study showed significant ($p<0.05$) reduction in pain, increased range of motion and functional improvement in both groups. But the pain reduction, increased range of motion and improvement in functional status was more significant in group A than group B. End range mobilization proved more effective treatment in frozen shoulder than capsular stretching.

Introduction

Frozen shoulder clinically referred to as adhesive capsulitis, has been described as a condition of unknown etiology and characterized by gradually progressive, painful restriction of shoulder joint motion with spontaneous restoration of partial or complete motion over months to years [1]. It usually involves regional tightness in the anteroinferior joint capsule which primarily compromises external rotation followed by loss of abduction and less often internal rotation and flexion [2].

It is divided into 3 stages, freezing stage lasting from onset to between 10 and 36 weeks, characterized by severe pain and a gradual diminution of articular volume, frozen stage lasting between 4 and 12 months when pain decreases gradually but without appreciable improvement in motion and thawing stage which is marked by gradual return of motion and may last between 12 months to few years [3].

Adhesive capsulitis is generally related to a shortening and fibrosis of the joint capsule (ligaments) surrounding the shoulder joint [4]. Although the exact pathophysiologic cause of this pathology remains elusive, there are two types identified in the literature: idiopathic and secondary adhesive capsulitis [5]. Idiopathic (primary) adhesive capsulitis occurs spontaneously without a specific precipitating event. Primary adhesive capsulitis results from a chronic inflammatory response with fibroblastic proliferation, which may actually be an abnormal response from the immune system [6]. Secondary adhesive capsulitis occurs after a shoulder injury or surgery, or may be associated with another condition such as diabetes, rotator cuff injury, cerebro-vascular accident [7]. Approximately 70% of frozen shoulder patients are women however, males with frozen shoulder are at greater risk for longer recovery and greater disability.

In the physical therapy setting, physical therapists utilize a variety of interventions to treat patients with adhesive capsulitis. These interventions are active/passive range of motion exercises, stretching, soft tissue mobilization, myofascial release, proprioceptive-neuromuscluar techniques, ultrasound therapy, electrical stimulation, hot packs, ice packs and joint mobilization techniques [2].

Although many studies have been determined the effect of ultrasound and mobilization in frozen shoulder, yet no study has been done on the combined effect of ultrasound and end range mobilization.

Material and Methods

This study was approved by Research and Ethical committee of University College of Physiotherapy, (UCOP) Faridkot. 30 Patients were taken from OPD of UCOP, Faridkot referred from Department of Orthopaedics, GGS Medical College and Hospital, Faridkot based on inclusion and exclusion criteria. Informed consent form was signed from each patient. After the initial assessment, patients were randomly divided into two groups, group A and group B. Randomization was done by using random number table, with allocation concealment by opaque sequentially numbered sealed envelopes.Inclusion Criteria included patients diagnosed with unilateral frozen shoulder (grade II), subject of both genders, age group 40-60 years, limited ROM of shoulder joint (Showing capsular pattern), no physical therapy for shoulder was given in the 4-5 weeks prior to study. Patients were excluded when they have any other Orthopaedics abnormality around shoulder, neuromuscular disorders, history of shoulder surgery, rheumatoid arthritis, cervical spondylosis with refering pain to the shoulder, cardiac conditions, painful stiff shoulder after trauma, fractureof shoulder joint and if patient is on steroids.

Intervention

Each patient was examined by therapist, in order to assess the presence of frozen shoulder .After the assessment patients were divided into two groups based on randomization and inclusion and exclusion criteria. Group A received end range mobilization and ultrasound therapy whereas Group B received capsular

Volume : 3 | Issue : 7 | July 2014 • ISSN No 2277 - 8179

stretching and ultrasound therapy. Treatment was given 6 days a week for 4 weeks.

Group A patients received end range mobilization. For mobilization patient was placed in supine lying.Patient's left hand's web and index finger cup over the patients shoulder medial to the acromion process. The fingers are extended over the scapula and thumb extends over clavicle. Alternatively, the heel of the hand extends over the acromoclavicular area. The right hand reaches round the patient's forearm to grasp the elbow from medial side so that the patient's right forearm is supported by therapist forearm and right hand of therapist hold right forearm by grasping it proximal to the wrist. The index finger extends along the anterior surface of patient's forearm and fingers and thumb holds the medial and lateral borders of patient's forearm. Then the therapist hold more firmly with the left hand to stabilize the shoulder girdle when the abduction is taken into resistance or up to limit of range. The pressure should be constant. After 10 -15 repetitions of intensive mobilization techniques in this end range position, the direction of mobilization was altered by varying the plane of elevation or by varying the degree of rotation [8]. This was followed by ultrasound in sitting with pulse ratio 1:4 and intensity of 1.5 W/cm^2 for 10 minutes. The total treatment duration was of 6 days a week for 4 weeks [3].

GroupB patients received capsular stretching. To stretch the anterior capsule the subject was positioned in high sitting. The shoulder and arm were brought backwards into extension and this stretch will be maintained for a minimum of 30 seconds and maximum duration up to the point of pain experienced by the patient. Posterior capsule stretching was performed with the subject in supine position and therapist performing cross body adduction. This was followed by ultrasound in sitting with pulse ratio 1:4 and intensity of 1.5 W/cm2 for 10 minutes. Total treatment duration was 6 days a week for 4 weeks [3].

Consort Flow DiagramConsort Flow Diagram

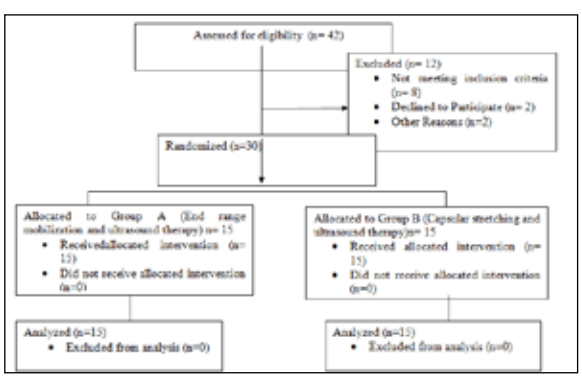

Figure 1: Flow chart of treatment procedure

Data Analysis:
The results were obtained by using SPSS. Data of 30 patients was analyzed to compare the results between the two groups. The results were considered significant with p value of 0.005. Effectiveness was checked by using paired and unpaired t- test.

Results:
The mean age group in study was 45 years. Males and females comprises of 36.7% and 63.3% respectively of the total 30 subjects. The maximum number of patients (14 patients) was in age group of 40-50 years i.e. 46.7%. Rest of patients was 40% (12 patients) in age group of 50-60 years and 13.3% (4 patients) in age group of 30- 40 years.

Paired t – test was used to compare different ROM of shoulder at day 0 and day 30th in group A and Group B, Group A shows significant improvement in flexion ROM with p = 0.000 by 6.072 % , external rotation ROM with p = 0.0001 by 77.04 % and abduction ROM with p<0.005 by 72.37 %. Group B shows less significant improvement in flexion ROM with p = 0.010, external rotation ROM with p = 0.0008 and abduction ROM with p = 0.08.

Unpaired t- test was done within Group A and Group B to analyze the correlation between mean value of flexion in Group A was 174.67 and Group B was 171.00 with p = 0.680, t = 1.898, mean value of external rotation in Group A was 79.67 and Group B was 73.33 with p = 0.010, t = 2.758 and mean of abduction in Group A was 137.33 and Group B was 120.3 with p = 0.001, t = 5.945. There is no significant difference in flexion ROM, whereas significant difference in external rotation and abduction ROM.

The mean values of VAS and SPADI showed significant improvement, paired t- test was used to compare pre and post protocol of Group A and Group B, shows significant improvement in both groups i.e. in Group A (VAS with p = 0.001) by 1.96%, (SPADI with p = 0.001) by 2.84% and Group B (VAS with p < 0.005) by 1.33%, (SPADI with p = 0.0064) by 1.01 %.

Unpaired t – test was done within Group A and Group B for VAS and SPADI. The mean of VAS in Group A = 2.60 and in Group B = 4.47 with p = 0.001, t = 5.856. The mean of SPADI in Group A = 35.06 and in Group B = 69.99 with p = 0.001, t = 9.210.This shows significant co-relation between group A and group B.

Unpaired t –test was used to compare mean difference of pre and post protocol of ROM, VAS and SPADI. Shows less significant difference in flexion with p = 0.0008 and external rotation ROM with p = 0.002 (Table 5.1) whereas highly significant difference seen in abduction ROM, VAS and SPADI with p = 0.001 (Table 5.2).

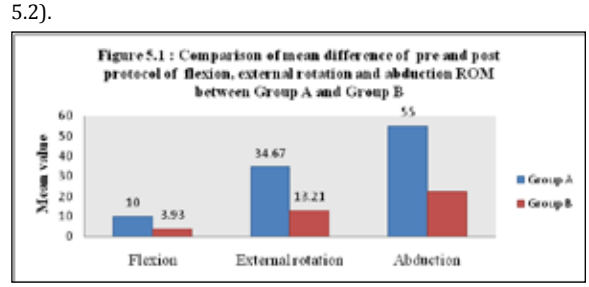

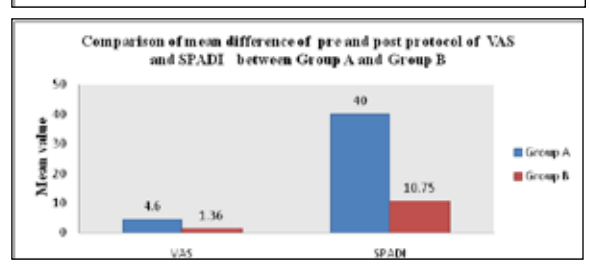

Discussion:
The two groups were analyzed with ROM which was assessed using Universal goniometer, VAS and SPADI. The result of present study showed that ultrasound therapy with end range mobilization shows more significant improvement as compared to ultrasound therapy with capsular stretching and thus it is clinically significant.

Yang (2007) conducted a study to evaluate the effect of mobilization technique in subjects with frozen shoulder. 28 subjects were included in the study and divided into 3 groups, Group I received mid range mobilization, Group II received end range mobilization and Group III received movement with mobilization for 12 weeks. Statistically significant improvements were found in End range mobilization and Movement with mobilization but no significant difference seen in outcome measures between End range mobilization and mid range mobilization. Thus it has been proven in this study that in End range mobilization and Movement with mobilization help to improve mobility and functional ability in patients with frozen shoulder. Study showed consistent results with the present study proving end range mobilization is effective.

The results of this study are in accordance with Sarkari (2006) who carried out a study to compare caudal glide and anteroposterior glide mobilization for the improvement of abduction

range of motion; the results of the study were highly significant for caudal glide with p< 0.05 for active and passive ROM. Thus caudal glide decreases pain and disability while improves active ROM and passive ROM. Kumar A (2012) conducted a study to evaluate the effectiveness of Maitland technique in frozen shoulder. Results of the study show significant improvement in patients treated with Maitland. Statistical analysis of the data revealed that within group comparison of both groups shows significant improvement in all parameters, whereas between group comparisons revealed higher improvement in group A which received Maitland mobilization compared to group B received exercises. Study results are consistent with present study results proving the effect of Maitland mobilization on frozen shoulder.

Janjua I et al (2011) conducted a study on physical therapy and Maitland manual joint mobilization technique in management of frozen shoulder and it was concluded that significant improvement was seen in ROM and VAS in patients with frozen shoulder who were treated with Maitland mobilization. The results of the study were consistent with results of present study providing improvement in ROM and VAS with Maitland technique in frozen shoulder.

Ansari et al (2012) conducted a study to compare effect of ultrasound therapy with end range mobilization and cryotherapy with capsular stretching on pain in frozen shoulder and it was concluded that ultrasound therapy with end range mobilization shows significant results and help to reduce pain, improves mobility and functional status. This study has a few limitations such as number of the subjects taken was very less, study involves short follow up,all shoulder range of motion was not measured andother techniques of mobilization may be used. Future studies can focus on more number of patients,protocol of longer duration andother mobilization techniques can be given to attain better results and all shoulder range of motions can be taken to see the effectiveness.

Conclusion:

This study concluded that ultrasound with end range mobilization is effective in treating frozen shoulder. It is best analyzed by using ROM, VAS and SPADI. Subjects receiving end range mobilization showed significant decrease in VAS, increase in range of motion and decrease in SPADI scoring as compared to subjects who were receiving capsular stretching.

REFERENCE

Ansari N, Lourdhuraj I, Shah S 2012, 'Effect of ultrasound therapy with end range mobilization over cryotherapy with capsular stretching on pain in frozen shoulder' Int j Cur Res Rev, vol. 04, pp.68-73. | Hand GC et al. 2007. 'The pathology of frozen shoulder', J Bone JointSurg Br. vol. 89, pp. 928-932. | Hengeveld E, Banks E 2002. 'Maitland's Mobilization' Fourth Edition, pp.311-312. | Hill J, Rasavong C 2009. 'Utilization of joint mobilization techniques to treat adhesive capsulitis of shoulder', Physical therapy resources. | Janjua I, Ali S 2011, 'Physical therapy and maitland's manual joint mobilization techniques are effective to manage the stage I adhesive capsulitis' Interdisciplinary journal of contemporary research in business.vol.3,pp. 243-248. | Kumar A, Aggarwal A, Ghosh P 2012, ' Effectiveness of Maitland technique in idiopathic shoulder adhesive capsulitis' International Scholarly Research Network . vol. 2012. | Nevaiser T. J 1945. 'Adhesive capsulitis of the shoulder: a study of the pathological findings in periarthritis of the shoulder', J Bone Joint Surg, vol. 27, pp. 211-222. | Rundquist PJ et al. 2003. 'Shoulder kinematics in subjects with frozen shoulder', ArchPhys Med Rehabil, vol. 84, pp. 1473-1479. | Siegel B, Norman J, Cohen 1999. 'Adhesive capsulitis', Journal of American acedemyof family physician, vol. 58, pp. 1843-1850. | Sarkari, Multani 2006, 'Comparison of caudal and antero-posterior glide mobilization for the improvement of abduction range of motion' Journal of Exercise Science and Physiotherapy. vol. 2, pp. 59-65. | Wolf. JM and Green 2008. 'Influence of comorbidity on self-assessment instrument scores of patients with idiopathic adhesive capsulitis', J Bone Joint Surg Am, vol. 84, pp. 1167-1173. | Yang J et al 2007, 'Mobilization Techniques in subjects with frozen Shoulder Syndrome: Randomized Multiple- Treatment Trial' Physical Therapy.vol.87, pp. 1307-1315. |