ORIGINAL RESEARCH PAPER

Volume-8 | Issue-6 | June-2019 | PRINT ISSN No. 2277 - 8179

INTERNATIONAL JOURNAL OF SCIENTIFIC RESEARCH

A RARE CASE OF GORLIN GOLTZ SYNDROME

Radiodiagnosis

Dr Simranjeet singh

Dr Pritam Gadia* *Corresponding Author

Dr Archit Tyagi

ABSTRACT

It is an inherited medical condition involving defects within multiple body systems such as the skin, nervous system, eyes, endocrine system, and bones. his shows a high level of penetrance and variable expressiveness, characterized by multiple basal cell nevi or carcinomas, odontogenic keratocysts, palmar and / or plantar pits, calcification of the falx cerebri, and is occasionally associated with internal malignancies. Early diagnosis is essential as it may progress to aggressive basal cell carcinomas and neoplasias. Here by we are reporting a case of gorlin goltz syndrome case here .

KEYWORDS

INTRODUCTION :-

The Gorlin-Goltz syndrome (GGS) is also known as the 'basal cell nevus syndrome', [1] or the 'nevoid basal cell carcinoma syndrome'. [2],[3]Jarish and White were the first to describe this syndrome, in 1894. n 1953, Gross presented a case with GGS. [5] Gorlin and Goltz, in 1950, established the classical triad of this syndrome, characterized by multiple basocellular epitheliomas, keratocysts in the jaws, and bifid ribs, [6] which was later modified by Rayner *et al*., who established that for making the diagnosis, at least odontogenic keratocysts had to appear in combination with calcification of the falx cerebri or palmar and plantar pits. [7] The incidence of this disorder is said to be 1 in 50,000 to 150,000 in the general population. [8] Both genders are equally affected and the clinical features arise in the first, second or third decade of life.

Systemic Manifestations

- BCCs are typically non-invasive with an average age of onset of 25. BCCs of varying number, size, and appearance occur most commonly in sun-exposed areas, and have a higher incidence in western countries
- Palmar and plantar pits are permanent, benign, red to dark brown or black papules that appear by age 10 in 30-65% of patients, and are present in more than 85% of patients older than 20 years of age.
- **Odontogenic keratocysts are jaw cysts with a characteristic radiographic appearance that are frequently recurrent, and affect 85-90% of patients, appearing as early as 10 years of age**.
- Calcification of the falx cerebri, evident on X-ray, increases with age, and affects 65% of patients in the United States, but rarely causes symptoms.[1]
- Skeletal abnormalities include bifid, fused, or markedly splayed ribs in 35% of patients, and kyphoscoliosis in 10-40% of patients.
- Medulloblastoma develops at age 2, earlier than it appears in the general population, and affects 5% of patients.
- Cleft lip and/or palate affects 5% of patients.

Ocular Manifestations

Twenty-six percent of patients develop ocular abnormalities.

- Periocular BCCs occurs in most patients
- Hypertelorism
- Strabismus, of which esotropia and esophoria may be more prevalent than exotropia and exophoria.
- Myelination of the retinal nerve fibers may occur bilaterally and involve the retina more extensively in Gorlin-Goltz syndrome patients than they do in the general population. This may cause visual field defects or decreased visual acuity
- Congenital cataracts.
- Milia may develop underneath the eyes and around the face in 30% of patients.
- Retinal anomalies include retinal detachment, retinal hole, retinal tear, retinoschisis, epiretinal membrane, macular hole, and combined hamartoma of the retina and retinal pigment epithelium (RPE).
- Rare ocular manifestations include nystagmus; iris, choroid, and optic nerve colobomas; congenital glaucoma; iris transillumination defects; and subconjunctival epidermoid cysts.

Diagnosis of Gorlin-Goltz syndrome may be established when 2 major, or 1 major and 2 minor criteria are present.
The major criteria are:
1. Multiple BCCs or one occurring under the age of 20 years.
2. Histologically proven odontogenic keratocysts of the jaw.
3. Palmar or plantar pits (3 or more).
4. Bilamellar calcification of the falx cerebri.
5. Bifid, fused, or markedly splayed ribs.
6. First-degree relative with NBCCS.
The minor criteria are:
1. Macrocephaly (adjusted for height).
2. Congenital malformation: cleft lip or palate, frontal bossing, coarse face, or moderate or severe hypertelorism.
3. Other skeletal abnormalities: Sprengel deformity, marked pectus deformity, or marked syndactyly of the digits.
4. Radiological abnormalities: bridging of the sella turcica, vertebral anomalies such as hemivertebrae, fusion or elongation of the vertebral bodies, modeling defects of the hands and feet, or flame-shaped lucencies of the hands or feet.
5. Ovarian fibroma.
6. Medulloblastoma.

The triad of nevoid basal cell carcinomas, jaw cysts and bifid ribs is known as nevoid basal cell carcinoma syndrome or Gorlin Goltz syndrome .

CASE REPORT :-

A 22 years old male presented with complaint of bilateral mandibular swelling since last 2-3 months. Now he gradually complains of discharge from the site of swelling and simultaneously he is also complaining of loosening of the teeth.

Patients also has features like hyperteleorism , cystic swelling of left eyelid . These were most of the extraoral facial features in this patient . On inspection of the oral cavity missing teeth of the right mandibular region .



Figure 1. Hyperteleorism



Figure 2. Other extraoral features include polydactyly

On orthopantomogram shows bilateral expansile lesion involving bilateral ramus of the mandible with sparing of the body of mandible with displacement of the underlying teeth .



Figure 3. On orthopantomogram shows bilateral expansile lesion involving bilateral ramus of the mandible with sparing of the body of mandible with displacement of the underlying teeth .



Figure 4. CT scan of the same patient was done and showed expansile lytic lesion noted involving bilateral ramus of mandible with sparing of body of mandible.

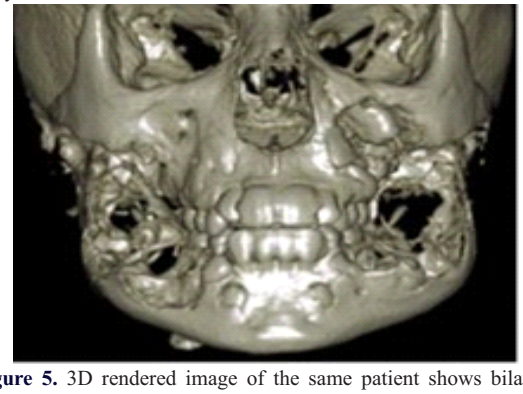

Figure 5. 3D rendered image of the same patient shows bilateral expansile lesion of the ramus of mandible with few septations in it .

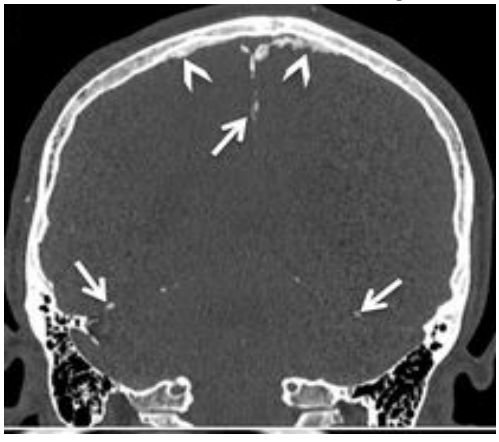

Figure 6. Coronal CT scan (bone window) shows ectopic calcifications of the falx cerebri and tentorium cerebelli (arrows) and spotted meningeal calcifications

DISCUSSION :-

The gorlin Goltz syndrome is an autosomal dominant disorder which presents with intra as well as extra oral features . Intraoral features includes the presence of bilateral odontogenic keratocyst which could be multi or uniloculated. Loosening of the teeth along with superimposed infection could be one of the presentation of the disease . Extraoral features like eyelid sebaceous cyst ,hyperteleorism, falx cerebri and tentorium cerebelli calcification. Spotted meningeal calcification can also be present . patient presented in early age of 10-3o years one should be suspecting Gorlin goltz syndrome and this diagnose should always be ruled out first as other malignancies are also associated with it .

CONCLUSION :-

The Gorlin-Goltz Syndrome must be considered as a possible diagnosis in all patients with odontogenic cysts. Early diagnosis by specialists with clinical and imaging modalities is useful for early management of neoplastic lesions in the early ages of life, and that results in a better prognosis.

REFERENCES

1. DeAmezaga AO, Arregui OG, Nuño SZ, Sagredo AA, Urizar JM. Gorlin-Goltz syndrome: Clinocopathological aspects. Med Oral Pathol Oral Cir Bucal 2008;13:E338-4
2. Gu XM, Zhao HS, Sun LS, Li TJ. PTCH mutations in sporadic and Gorlin-syndrome-related odontogenic keratocysts. J Dent Res 2006;85:859-63.
3. R Yang X, Pfeiffer RM, Goldstein AM. Influence of glutathione-S-transferase (GSTM1, GSTP1, GSTT1) and cytochrome p450 (CYP1A1, CYP2D6) polymorphisms on numbers of basal cell carcinomas (BCCs) in families with the naevoid basal cell carcinoma syndrome. J Med Genet 2006;43:e16
4. Agrawal A, Murari A, Vutukuri S, Singh A. Gorlin-goltz Syndrome: Case report of a rare hereditary disorder. Case Rep Dent 2012;2012:475439
5. Howell JB, Caro MR. The basal-cell nevus: Its relationship to multiple cutaneous cancers and associated anomalies of development. Arch Dermatol 1982;118:813-23
6. Gorlin RJ, Goltz RW. Multiple nevoid basal-cell epithelioma, jaw cysts and bifid rib. A syndrome. N Engl J Med 1960;262:908-12
7. Rayner CR, Towers JF, Wilson JS. What is Gorlin's syndrome? The diagnosis and management of the basal cell naevus syndrome, based on a study of thirty-seven patients. Br J Plast Surg 1977;30:62-
8. Ljubenoviæ M, Ljubenoviæ D, Biniæ I, Jovanoviæ D, Stanojeviæ M. Gorlin-Goltz syndrome. Acta Dermatovenerol Alp Pannonica Adriat 2007;16:166-9