ORIGINAL RESEARCH PAPER

Volume-8 | Issue-1 | January-2019 | PRINT ISSN No 2277 - 8179

INTERNATIONAL JOURNAL OF SCIENTIFIC RESEARCH

A STITCH IN TIME SAVES NINE – A CASE OF BEAR MAUL INJURY

Dental Science

Dr.Smriti Ticku Oral and maxillofacial surgeon Hosmat hospital, Bangalore

ABSTRACT

Bear bite injuries have become a common occurrence as the forest covers and natural habitats are diminishing. Patients injured in bear attack present with different patterns of injuries. Bears are strong and agile wild animals, potentially dangerous, unpredictable and can inflict serious injuries. Mammalian attack injuries have a special place in traumatology because of their high complication rate when compared with similar soft tissue wounds otherwise caused. Bites from attacking animals may lead to local infection, and wounds that are potentially contaminated with a variety of pathogens. The excellent blood supply of the face makes infection a rare occurrence, however, the injury may cause sufficient disfigurement to require extensive reconstruction. Treatment of mammalian bite wounds must address both the management of soft tissue deformities and then prevention of post treatment infection3. A common protocol may not be suitable for the management of injuries inflicted by these large wild animals. These animals usually attack in remote areas where composite trauma centres do not exist and urgent referrals of these patients will have significant effect on the final outcome. Limited literature is available describing bear bite management in maxillofacial practice. The goal of the present case reports is to document the injuries suffered in bear mauling and to add to the literature on the need for immediate soft tissue management with minimal complication.

KEYWORDS

Bear mauling, Maxillofacial, Management, Trauma Injuries

INTRODUCTION

Bear attack on the face and neck is a rare event causing a lot of injury to the neck and face, disfigurement and other life threatening consequences. The earliest form of surgical treatment would involve evaluation of vitals and early tracheostomy to secure the airway if urgently required followed by repair of primary injuries involving the face and throat. Bear bite injuries to the head and neck region can result in facial disfigurement with distressing physical and psychological consequences. Bear mauling cases are rarely reported in literature. The commonly involved injury sites being face (80.57%) and head (54.67%). Bite wounds by large animals can present in more serious fashion with the bone injuries. All the bony injuries will be associated with the soft tissue injuries namely punctures, lacerations, and avulsions ,joint damage, skin and deep tissue injuries with or without actual tissue loss [4].The facial bones (27.09%)were commonly involved followed by the skull(57.75%)[3].

CLASSIFICATION OF FACIAL BITE INJURIES

Type	Clinical findings
I	Superficial injury without muscle involvement
IIA	Deep injury with muscle involvement
IIB	Full-thickness injury of the cheek or lip with oral mucosal involvement (through and through wound)
IIIA	Deep injury with tissue defect (complete avulsion)
IIIB	Deep avulsive injury exposing nasal or auricular cartilage
IVA	Deep injury with severed facial nerve and/or parotid duct
IVB	Deep injury with concomitant bone fracture

Predominance of zygoma in the face and frontal bone in the skull explains the fact that the prominent parts are easily targeted .The management of facial bite wounds are often a challenge because of unforeseeable infections that can occur because of primary bacterial invasion .The reported incidence of infection varies from 13 to 30% and their optimal management is controversial[3].

Facial defects caused from such bite injuries not only create functional problems but also serious psychological problems, which can cause the individual to avoid social contact [2]. Hence, the first aim of maxillofacial rehabilitation should be solving the functional and aesthetic problems of the patient. Extensive soft tissue injuries should be treated according to the criteria of an aesthetic reconstructive surgery .The purpose of this article is to report an extensive case of bear maul injury and its early subsequent management.

CASE REPORT

A 57-year-old male patient was presented to Hosmat Hospital, Bangalore on 5th October 2017 at around 4pm with severe injuries caused by bear attack near Kolar .He was taken to nearby hospital for primary care due to absence of multispecialty unit he was referred to a higher centre .Patient had multiple skin lacerations resulting in exposure of underlying structures (parotid gland with duct, buccinators muscle, buccal pad of fat etc.) (Fig. 1, 2, 3) and was bleeding profusely from the avulsed lacerations over the face and other parts of the body.

PRE-OPERATIVE



(Fig. 1, 2, 3)

There were degloving injuries in upper and lower vestibule, and avulsion of upper anterior teeth in addition patient had avulsed right eye, multiple fractures of maxillary bone ,multiple lacerations over right forearm, sole of the right leg, buttocks ,scalp and was delirious at presentation. CT-scan revealed that there was bilateral fracture of alveolar process of maxilla with comminution on right side, complete fractures of all the wall of maxillary sinus bilaterally with displacement of fractured fragments into the sinuses on right side. There was bilateral fracture of zygomatic buttress bone, right communicated fracture of infraorbital rim and floor along with fractured zygomatic arch and Fronto-zygomatic bone on right side. (Fig. 4, 5, 6)

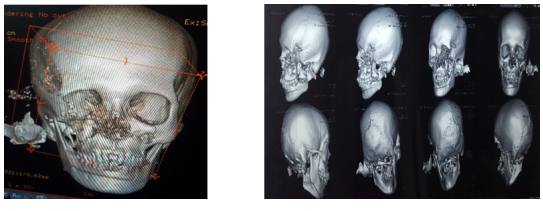

(Fig. 4,5,6)

After maintaining the airway, breathing and circulation, Tracheostomy was done, Tetanus prophylaxis and rabies vaccine were given to the patient. After thorough surgical debridement of wound, decision was

taken to close the wound primarily under general anaesthesia within 4 hours post trauma. Open reduction internal fixation of the fractured bones was done and buccal branch of the facial nerve was repaired. Intraoral layer wise closure of the wound was done with 4-0 vicryl suture. After the adequate approximation of deep structures extra oral wound closure was done using 5.0 ethilon sutures and an infant feeding tube was used as a drain was placed over left side (Figs. 7,8, 9) .Wound debridement and Primary closure of other lacerations over the right hand ,buttocks sole of the foot, and scalp was also carried out. Split thickness skin grafting procedure was carried out to cover the scalp defect and defect over left eye.

INTRA-OPERATIVE



(Figs. 7,8, 9)



A course of broad spectrum antibiotic and anti-inflammatory was given for one week and chart for Rabies vaccination was maintained, Ryle's tube was put and feeding was maintained following a high protein and calorie diet with the help of dietician. Patient was regularly followed up.

DISCUSSION

Facial injuries in bear mauling can be explained on the basis that head and face are the most prominent parts of body and there being multiple irregularities over the face due to bony projections, making it the most available for the bear paws /claws, resulting in severe injuries.

Mammalian bite wounds are associated with an infection rate between 10 and 20%. Prophylactic antibiotics are recommended for high risk wounds namely those more than 8 h old, deep punctures, wounds that require surgical repair, hand and lower extremity wounds and wounds in medically compromised patients [5,6].

Wild animal injuries are distinguished by combination of cutting, penetrating and crushing (due to powerful slap) are commonly seen in the victim of bear attack. These injuries involves substantial struggle on the part of victim on the ground, which forces mud, grass and other contaminating material into the wounds, so vigorous irrigation and removal of all foreign material are off para-mount importance. Bear bite injuries with tissue loss may result in severe disfigurement with significant functional and aesthetic concern.

The treatment of these lacerations should include thorough physical examination along with radiographic examination must warranted. These wounds should be irrigated with hydrogen peroxide and saline thoroughly, meticulously debrided and closed. For bite wounds presenting beyond the golden 24 h period primary closure is controversial [3].

However is this case primary closure and reduction of fractures was done within 6 hours post trauma. We have achieved acceptable results by closing the lacerations primarily with what we called the “Golden period” for soft tissue management.

Management of bites requires both local wound and systemic considerations. The principles of management of bite wounds include proper assessment, meticulous documentation, and thorough wound cleansing and debridement. Tendon/sheath involvement, distal neurovascular status, bone injury, joint space involvement, visceral injury and tissue loss must always be thoroughly assessed. The bottom of the wound should always be carefully screened to identify devitalized tissue, deep injury and foreign bodies (e.g., teeth). A major concern in all bite wounds is infection due to the presence of the large number of bacteria in the oral cavity. Hence all bite wounds should be considered contaminated.

Closure of infected wounds can lead to dehiscence and persistence of infection. Whenever possible the wound is covered with bandages are often used for the first 3 to 5 days. Wound closure may be possible for non-infected wounds that are in the “Golden period” (6-8 hours after injury).

The need for antimicrobial treatment in contaminated, non-infected wounds is controversial, there is no evidence it prevents infection and it may select for infection of the bacteria that are resistant to anti-microbial drug used. Anti-microbial treatment is necessary for deep punctures, or large dirty wounds that require extensive debridment.If deemed necessary, the drug of choice for contaminated wounds is amoxillin-clavulanic acid ,because it has efficacy against most oral commensals of the animals mouth such as Pasteurella spp.and variety of anaerobes, including those that produce beta-lactamase enzymes.

For severely infected wounds initial line of treatment should consist of parenteral anti-microbial drugs that have activity against gram negative and gram positive aerobic and anaerobic bacteria, which includes methicillin resistant staphylococci(in regions where methicillin-resistant S.pseudintermedius is prevalent).Appropriate combination include ampicillin –sulbactam and aminoglycosides, or combination include ampicillin ,metronidazole ,and an aminoglycosides. Where methicillin-resistant S.pseudintermedius is not prevalent, a fluoroquinolone could be substitute for the aminoglycosides. Subsequent treatment should be based on culture and susceptibility.

Infectious potential of animal bites

Factor	High risk	Low risk
Species	Domestic cat	Dog
	Large cat (deep punctures can penetrate joints, cranium),	Rodent
	Human (in hand wounds only),	
	Primate(anecdotal evidence only),	
	Pig, monkey	
Location of wound	Hand, feet, wrist	Face, scalp, ear and lip
	Scalp or face in infants (high risk of cranial perforation)	
	Below knee	
	Through-and-through oral	
	Penetration of underlying tissue (bone, joint, tendon, vascular)	
Wound type	Puncture (impossible to irrigate) (60 % of all bite infections)	Superficial, large clean lacerations that can be thoroughly cleansed; the larger the laceration and the better the cleansing, the lower the infection rate
	Extensive crush that cannot be debrided (typical of herbivores such as cows, horses)	
	Contaminated	Clean
	Delayed presentation >12 h	Recent
Patient	Elderly	
	Diabetic	
	Peripheral vascular insufficiency	
	Asplenic	
	Chronic alcoholic	
	Chronic corticosteroid therapy	
	Cytotoxic drugs	
	Altered immune status	
	Prosthetic or diseased cardiac valve (consider systemic prophylaxis)	
	Prosthetic or seriously diseased joint (consider systemic prophylaxis)	

Tetanus and rabies prophylaxis should be considered for all bite wounds. In region where rabies occurs, bite wounds may need to public health authorities. If the biting animal was from wild animal that was unavailable for testing, rabies booster should be administered.

Though surgical management in animal bites remains a controversy, there is no doubt that role of primary wound management specially emphasizing on highest level of wound toileting plays a very important role [11]. Now surgical opinion is swinging in the favour of early repair.

Bites from large animals generally have a significant crush element and often tissue loss because of the force involved. Primary closure/reconstruction may be considered in relatively clean bite wounds or wounds that can be cleansed effectively so as the possibility of infection has been eliminated.

In the present case reports since the subjects was attacked in the jungle while grazing cattle, the bear might have attacked them as a defensive measure. The majority of the wounds sustained by the victims (defensive or predacious attacks) in the present study involved the head and extremities.

Management of this case with tracheostomy and debridement, suturing

and interdental wiring with blood transfusion and intensive care unit management was done promptly on the Day 1 soon 4 hours post trauma .Immediate closure aesthetically improved and gave better results . Close follow up is necessary in these cases to avoid any complications and to treat any such complications as early as possible.

FLOLLOW-UP





Psychiatric complications are common following bear mauling. Post-traumatic stress disorder (PTSD) is defined as development of symptoms lasting longer than 1 month following emotional stress associated with trauma. These symptoms include depression, anxiety and cognitive difficulties. If these symptoms persist for less than 1 month following emotional stress, a diagnosis of acute stress disorder can be made. None of these complications were noticed in the present cases and subject is living happily after 1 year following the attack.

CONCLUSION:

Bear attack injuries require a team approach, as the injuries are not restricted to one area. Careful evaluation of bite wounds with physical as well as radiological examination should be carried out prior to definitive management. Proper surgical toilet with wound irrigation followed by careful debridement along with addressing the bony injuries remains the mainstay of treatment of all bite wounds. Most of these cases though treated with primary closure at the earliest, gives not only aesthetic results but also good recovery time for nerve regeneration in case of vascular injury to face. In this cases clinical judgement should be used and close follow up is recommended to assess post-surgical complications and deformities if any which may or may not require secondary correction. Monitoring Psychological condition of the patient is one major thing that should be taken into consideration post trauma .And role of multispecialty unit involvement plays a major role ,team effort including plastic and maxillofacial units for management of both soft tissue and bony injuries to give patient a better aesthetic results and improves his quality of life post trauma.

REFERENCES:

1. Rangila Ram-Maxillofacial Injuries due to Bear Mauling. Maxillofac. Oral Surg. (Jan-Mar 2011) 10(1):85–89
2. Ashutosh Kumar Singh1, Dr. Sanad Dulal1, Dr. N. Jayaprakasha Mayya2A Rare case of bear attack on the face and the treatment in college of medical sciences, Bharatpur, Central Nepal; Journal of College of Medical Sciences-Nepal, Vol-11, No 2, Apr-Jun 015
3. N. T. Geetha H. R. Shivakumar P. Upasi Amarnath Bekal Pattathan Rajesh Kumar Rai Kirthikumar- Bear Maul Injuries in Maxillofacial Region: Our Experience:J. Maxillofac. Oral Surg. (Oct-Dec 2012) 11(4):420–424
4. Stefanopoulos PK (2009) Management of facial bite wounds. Oral Maxillofac Surg Clin N Am 21:247–257
5. Kesting MR, Holzle F, Pox C, Thurmuller P, Wolff K-D (2006) Animal bite injuries to the head: 132 cases. Br J Oral Maxillofac Surg 44:235–239
6. Stefanopoulos PK, Tarantzopoulou AD (2005) Facial bite wounds: management update. Int J Oral Maxillofac Surg 34:464–472
7. K.Voss in feline orthopaedic surgery and musculoskeletal disease
8. Frank RC, Mahabir RC, Magi E, Lindsay RL, de Haas W (2006) Bear maulings treated in Calgary, Alberta: their management and sequelae. Can J Plast Surg 14(3):158–162
9. Smith PF, Meadoweroff AM, May DB (2000) Treating mam-malian bite wound. J Clin Pharm Ther 25(2):85–99
10. Beumer J, Curtis TA, Marunick MT (1996) Maxillofacial rehabilitation: prosthodontic and surgical consideration, 2nd edn. Ishiyaku Euroamerica, St. Louis, pp 377–453
11. Herrero S (2003) Bear attacks: their causes and avoidance, New revised edition. McClelland and Stewart Ltd, Toronto
12. Middaugh JP (1987) Human injury from bear attacks in Alaska, 1900–1985. Alaska Med 29(4):121–126
13. Brook I (1987) Microbiology of human and animal bite wounds in children. Pediatr Infect Dis J 6(1):29–32
14. Goldstein EJ, Citron DM, Wield B, Blachman U, Sutter VL, Miller TA, Finegold SM (1978) Bacteriology of human and animal bite wounds. J Clin Microbiol 8(6):667–672
15. Maimaris C, Quinton DN (1998) Dog-bite lacerations: a con-trolled trial of primary wound closure. Arch Emerg Med 5:156–161. doi:10.1136/emj.
16. Kaplan HI, Saddock BJ, Grebb JA (1994) Synopsis of psychiatry: behavioral sciences, clinical psychiatry, 7th edn. Williams and Wilkins, Baltimore, pp 608–611
17. Hayashi Y, Fujisawa H, Tohma Y, Yamashita J, Inaba H. Penetrating head injury caused by bear claws: Case report. J Trauma. 2003;55:1178–80.
18. Kunimoto D, Rennie R, Citron DM, Goldstein EJ. Bacteriology of a bear bite wound to a human: Case report. J Clin Microbiol. 2004;42:3374–6.
19. Vougiouklakis T. Fatal brown bear (Ursus Arctos) attack: Case report and literature review. Am J Forensic Med Pathol. 2006;27:266–7.
20. Jethani J, Nagori R, Ghodadara B. An unusual case of bear bite with severe loss of tissue. Indian J Ophthalmol. 2006;54:287–8.