Volume : 4 | Issue : 10 | October 2015 • ISSN No 2277 - 8179

Research Paper

A Study of Anaesthesia for Laser Surgery of Larynx

Medical Science

KEYWORDS : CO_2 laser in laryngeal laser surgery, Safe anaesthesia

Dr. Anita B. Patel — Associates Professor of Anaesthesia, Smt. NHL Muni.MMC, Ahmedabd

Dr. Exta Soni — Assistant Professor of Anaesthesia.

ABSTRACT

Laser surgery offers several advantages to the surgeon and patient; i.e. microscopic precision, a bloodless operative field & complete sterility. We have reviewed selected aspects of anaesthetic management of patients undergoing CO2 laser surgery of larynx & outlined the principles of laser technology. We also emphasized on currently available measures to prevent problems of laser surgery. We studied 60 patients of ASA Grade I to III posted for elective laryngeal laser surgeries to study the outcome of our anaesthetic management.

INTRODUCTION

With rapid advancement in ENT laser surgery there are new challenges to the surgeons and anaesthesiologist. It consists of package of some benefits and some problems. Anaesthesiologists and Surgeons are working in the same anatomic field and share the airway which is already compromised by the disease. Margin of safety is reduced. Close co-operation and communication between aneasthesiologist and surgeon is of paramount importance.

Airway fire is the major hazard.

Role of anaesthestist :

- Maintain Oxygenation
- Allow removal of CO_2
- Keep patient aneasthetised
- Reduce incidence of airway fire by special approaches
- To deal with crisis
- Reduce post operative complications

Anaesthesia Management :

Pre-operative Consideration :

We have studied 60 patients between 5 years to 60 years of age group. A pre-operative visit to determine the degree of existing airway obstruction is mandatory. Patients are being evaluated for hoarseness, stridor and haemoptysis.

Following laryngeal surgeries were included in our study :-

- Laryngeal papilloma exision -16,
- Vocal cord nodule/cyst removal -9,
- Postcorrosive tracheal stenosis -15,
- Posttrauma tracheal stenosis-10,
- Obstructing tumour -7,
- Vocal cord dysfunction -3.

A meticulous preoperative history, physical examination with particular attention to potential airway problems must precede any decision regarding the anaesthetic plan. Many patients have undergone IDL by surgeon & discussing the findings & plans with surgeon preoperatively are important.

The most important points is that whether the patient will be easy to ventilate with a face mask & easy to intubate with direct laryngoscopy. If either is in doubt, the patient's airway should be secured prior to induction by using alternative technique such as use of fibreoptic bronchoscope or tracheostomy under Local Anaesthesia. All the patients were given anaesthesia as follows.

PREMEDICATION:

Inj. Glycopyrolate 0.004mg/kg i.v. Inj. Fentanyl 1 µg /kg i.v. Inj. Ondansetron 0.08mg/kg i.v.

Anaesthesia goals include profound muscle paralysis to provide massater muscle relaxation for introduction of scope, immobile surgical field, adequate oxygenation, ventilation and cardiovascular stability during period of surgical stimulation. Profound relaxation is required until the end of surgery and rapid recovery is essential.

INDUCTION:

Monitors were applied and vitals, SPO_2, $ETCO_2$ were monitored. Preoxygenation with 100% O_2 for 3 minutes. Inj.Dexamethasone 150µg/kg. Inj. Propofol 1.5mg/kg, Inj. Lignocaine 1.5mg/kg, Inj. Suxaethonium 2mg/kg

INTUBATION:

Intubation was done with special tube (Mallinckrodt tube in adults and Wrapped tube in Paediatric patients) or ventilation with wrapped tracheostomy tube was done. Cuff was inflated with saline and methylene blue.

MAINTENANCE:

Controlled ventilation was done with air using silicon ambu bag with long extension. Intraoperative muscle relation with Atracurium/vecuronium. We used Inj. Propofol 8mg/kg/hour and Inj. Fentanyl 0.5 µg/kg/hour as TIVA.

REVERSAL:

Inj. Glycopyroplate 0.008 mg/kg. + Inj. Neostigmine 0.05 mg/kg. After extubation patients were observed for any complication like laryngeal edema and laryngeal spasm.

POSTOPERATIVE ANALGESIA:

Inj. Diclofenac 1mg/kg i.v. slowly.

PER/POST-OPERATIVE COMPLICATIONS:

- In one patient (1.6%) very little portion of alluminium foil covering the endotracheal tube got damaged due to heat. It was brought to notice by operating surgeon and we changed the tube.
- One of the patient (1.6%) complained of difficulty in breathing after extubation. On examination we diagnosed laryngeal edema and treated accordingly. Patient recovered fully.

DISCUSSION

OXYGENATION AND VENTILATION

Several methods have been successfully used to provide oxygenation and ventilation during endoscopy. The best approach is to have several alternatives available at the time of induction of anaesthesia. For adult patients, wrapped tubes, metal tubes and jet ventilation should be on hand. Each method has its own sets of problems and benefits. Most commonly the patient is intubated with small diameter endotracheal tube through which positive pressure is administered. Advantages of this is, smooth mainte-

Volume : 4 | Issue : 10 | October 2015 • ISSN No 2277 - 8179

nance of airway throughout surgery. Disadvantage is small size which increase airway resistance and it obstructs surgical field.

TIVA (TOTAL INTRAVENOUS ANAESTHESIA)
Propofol is a short acting induction agent. It is associated with rapid emergence of anaesthesia and hence it is agent of choice for TIVA. Fentanyl which is a strong analgesic is combined with it. It also deepens the plane of anaesthsia. Combination of this provide minimal intra and post operative complications by maintaining adequate depth of anaesthesia and wide awake patients. Disadvantage of TIVA are difficulty in assessing the depth of anaesthesia.

AIRWAY FIRE AND EXPLOSION
Airway fire and explosion is the major risk factor for laryngeal laser surgery.

Incidence – 0.5% to 1.5%.
It is caused by
- Direct laser illumination,
- Reflected laser light.

Airway fire causes
- Thermal burns,
- Chemical response to burns.

Approaches to reduce incidence of airway fire

Reducing flammability of ETT
- Special tubes those are laser resistant.
- Wrapping standard tubes.
- Cuff of ETT has to be inflated with saline+methylene blue

Using different modes of ventilation
- Intermittent Extubation
- Venturi Jet Ventilation,
  Jet ventilation: (HFJV) there are different method of delivering HFJV
  - o Transtracheal HFLV
  - o Subglottic / Traslaryngeal HFJV
  - o Supraglottic Superimposed HFJV

❖ Advantages: No obstacle to surgical field, Adequate ventilation
❖ Disadvantages : Surgical emphysema, barotraumas, pneumothorax, hypoxemia, hypercarbia, abdominal distension, compliant lung is required
❖ Contraindication: Patient requiring ETT <2.5mm

Fio_2 <30%, Avoid N_2O and volatile anaesthetics
Use of TIVA

Special Tubes:
These tubes are laser resistant, bulky and stiffer.

Disadvantages:
✓ Trauma to mucosa
✓ Reflect laser beam
✓ No protection of cuff
✓ Expensive

Laser Resistant Tracheal Tubes
THE NORTON TUBE:
- Reusable
- Stainless steel
- Flexible Tube
- No cuff

THE LASER FLEX TUBE (MALLINCKRODT LASER TUBE):

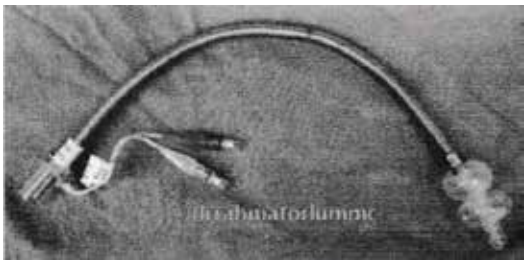

- Airtight stainless steel tube
- Flexible
- Uncuffed or with two cuffs

THE LASER-SHIELD II (XOMED-LASER SHIELD II TUBE):

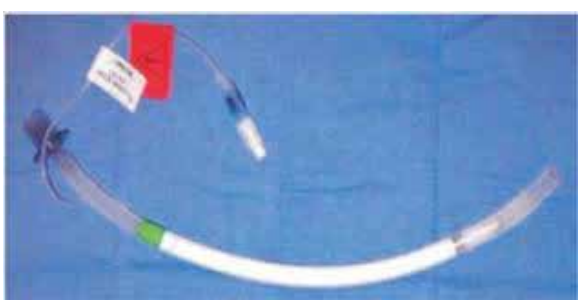

- Silicon tube
- Inner aluminum wrap
- Outer Teflon coating

THE BIVONA FOME-CUFF LASER TUBE:



- Designed to solve the perforated cuff deflation problem
- It consists of an aluminum wrapped silicon tube with unique self inflating foam sponge filled cuff which prevent deflation after puncture.

Wrapped standard tubes



- Standard tracheal tubes (rubber, silicon and PVC)
- Wrapped with laser resistant material (except cuff)
- Wrapped material may be

- Aluminum or copper foil tape with adhesive back.
- Merocel laser guard (merocel wrap).

- **Method of wrapping:**
- Paint the tube with medical adhesive such as benzoin.
- Cut the end of the tube with scalpel to approximately 60 degree.
- Start wrapping from junction of tube and proximal end of cuff
- Wrapping in spiral with 30% to 50% overlap layer
- It includes inflation tube of the cuff

- **Disadvantages**
- No cuff protection
- Add thickness to tube
- Airway obstruction
- Rough edges may cause damage to mucosal surface.

Airway fire protocol

1) Communication and recognition.
2) Stop ventilation, remove ETT and disconnect breathing circuit from anaesthesia machine.
3) Flood the airway with saline. (if flame not controlled)
4) Ventilate the patient with 100% via face mask.
5) Assess the damage:

- Rigid Brochoscopy – remove debris and fragmented mucosa
- Examine the patient's face and oropharynx
- Direct larygoscopy.

6) Monitor the patient with pulse oximetry, serial ABGA and chest X-ray.
7) Reintubate the patient or perform trachestomy as needed.
8) Use ventilator support, steroid and antibiotic as needed.

SAFETY MEASURES

- Warning signs outside OT
- Eye protection :
- For the patient: eye should be taped closed and covered with opaque saline swabs or metal shield.
- For the working personals: wear safety goggles or lens specific for the laser wave length in use

- **For laser plume:**
- Use efficient smoke evacuator mask.
- Use special high efficiency mask.

- Instruments: matt finish to avoid reflection.
- Mucous membrane and teeth adjacent to operative field should be covered with saline soaked gauze.
- Surgical drapes made of flame resistant or waterproof material.
- Preventive measures against fire and explosion must be ready. Eg. CO_2 fire extinguisher, bucket of water.

SUMMARY

Smooth and safe general anaesthesia in compromised airway with abnormal anatomy, sharing of airway with surgeon, avoidance of potential laser hazards, prevention of awareness, wide awake patient after surgery with least postoperative complication are main challenges for anaesthesia for laryngeal laser surgery.

With use of safety measures and special techniques for anaesthesia, the problems of laryngeal laser surgery are minimized.

REFERENCE

1) Schramm VL Jr, Mattox DE, Stool SE. Acutemanagement of laser-ignited intratracheal explosion. Laryngoscope, 1976;91: 1417-26. 2) Shaker MH, Konchigei HN, Andrews AH Jr Holinger PH. Anesthetic Management of carbon dioxide laser surgery of the larynx Laryngoscope, 1976;86: 857-61. 3) Edelist G, Alberti P. Anesthesia for CO2 surgery of the larynx. J. Otol, 1982; 11:2. 4) Alberti PW. The complications of CO2 laser surgery in otolaryngology. Acta Otol, 1981; 91:375-81. 5) Soder DM, Haight J, Fredrickson JL Scon AA. Mechanical ventilation during laryngeal laser surgery. Can Anaesth Soc J, 1980;27:111-5. 6) Jaquest Y, Monnier P, Van Melle G, et al. Complications of different venti lation strategies in endoscopic laryngeal surgery. A 10 year review. Anesthesiology 2006;104:52-59. 7) Werkhaven JA. Microlaryngoscopy-airway management with anaesthetic techniques for CO2 laser. Pediatr Anesth 2004;14:90-94.