Original Research Paper

VOLUME-6 | ISSUE-1 | JANUARY-2017 • ISSN No 2277 - 8179 | IF : 3.508 | IC Value : 78.46

A STUDY OF LEVATOR GLANDULAE THYROIDEA IN SOUTH INDIAN POPULATION

Anatomy

KEYWORDS: LEVATOR GLANDULAE THYROIDEA, THYROGLOSSAL DUCT, THYROID GLAND,

DR NAMITHA VISWANATH

ASSISTANT PROFESSOR DEPARTMENT OF ANATOMY GOVERNMENT MEDICAL COLLEGE KOZHIKODE

ABSTRACT

Thyroid gland is a highly vascular endocrine gland with 2 lateral lobes and an isthmus .A wide range of developmental anomalies are associated with thyroid gland namely the pyramidal lobe, agenesis of isthmus and levator glandulae thyroidea. This study aims on reporting the incidence and attachment of levator glandulae thyroidea in south Indian population. This cadaveric study is conducted on 50 thyroid gland (40 males and 10 females) at Government Medical College Kozhikode. Tabulated data obtained was analyzed by chi square chart .Levator glandulae thyroidea was noted in 26% of cases. The study showed no statistical difference between males and females .Levator glandulae thyroidea was then subtyped according to Mori's classification. This study highlights the importance of levator glandulae thyroidea which forms a cornerstone for safe and effective thyroid surgery.

INTRODUCTION

Thyroid gland is an endocrine gland located in front of neck consisting of 2 lateral lobes and an isthmus.

In 1600, Julius cassenius of Pandua was the first person to describe the thyroid as a single gland. There is a drawing in his "First Dissection of Man" in which the gland appears as a single body lying across the trachea and called it "corpus glandulosum ad Laryngeum ipsum situm".He was unable to find any duct from this gland and concluded that none existed. This led him to believe that the thyroid gland had an esthetic significance by filling out the sides of neck.

Thomas Warton in 1614 described the thyroid gland and it was he who gave the gland its modern name, thyroid gland. Warton suggested that the function of the gland was to round out and beautify the neck by filling the vacant spaces around larynx and in females for this reason a larger gland has been assigned.

Thyroid gland develops from a median endodermal thickening in the floor of the primitive pharynx at the region of foramen caecum. Later it descends in front of the pharyngeal gut as diverticulum called thyroglossal duct. It migrates anteriorly in front of hyoid bone and laryngeal cartilages .At first the diverticulum is hollow but later it becomes solid and divides into right and left lobes. It reaches its normal position in the neck and the thyroglossal duct disappears. In certain individuals caudal end of thyroglossal duct persist as pyramidal lobe and accessory muscles related to it.

Diverse arrays of accessory muscles associated with thyroid gland were documented right from 17th century. An accessory muscle was first described by Winslow in 1743.He called it 'thyro- adenoidein" which runs from inferior pharyngeal constrictor to thyroid gland.

In 1794, Sommerring introduced the term "Levator Glandulae Thyroidea" for an accessory muscle which originated either from hyoid bone or from thyroid cartilage and inserted on the isthmus, pyramidal lobe or lateral lobe of thyroid gland. Later Levator Glandulae Thyroidea came to be known as Levator Glandulae thyroidea of Sommerring.

In 1836,Bourgery described levator glandulae thyroidea and illustrated it as a muscle occupying the place of pyramidal lobe and he called it "hyo-thyroidien".

In 1847. Godart reported a case in which an accessory muscle run from hyoid bone to insert partly on thyroid cartilage and partly on the isthmus of the thyroid gland. He reported it as muscle on the basis of nitric acid test.

Streckeisen in 1886, with respect to its attachment, divided the accessory muscles into two groups. Group 1 for muscles attached to the pyramidal lobe and Group 11 for muscles attached elsewhere on the gland.

In group I, there are two muscles 1.Musculi hyopyramidalis , 2. Musculi thyreopyramidalis.

Musculi hyopyramidalis arises from hyoid bone and gets inserted to the pyramidal lobe at various points. Musculi thyreopyramidalis arises from thyroid cartilage and gets inserted on pyramidal lobe of thyroid.

In group II there are three muscles
1. Musculi Hyoglandularis
2. Musculi Thyreoglandularis
3. Musculi Hyo thyreoglandularis

They arise from hyoid bone, thyroid cartilage and both respectively. They insert on the thyroid isthmus or lateral lobes.

With respect to innervations of accessory muscles, a classification was put forward by Eisler in 1900. He divided it into 3 groups

Group I include muscles innervated by superior laryngeal nerve.
Group II include muscles innervated by the hypoglossal nerve
Group III include muscles innervated by the vagus

Group I muscles are independent muscles ,embryologically part of cricothyroid muscle arising from thyroid cartilage or hyoid bone and inserting on the pyramidal lobe,isthmus or lateral lobe of thyroid. He named them as Levator glandulae thyroidea anteriores sive ventrales.Group II muscles are non- independent slips of thyrohyoid muscle arising in the vicinity of inferior tubercle of thyroid cartilage and inserting on the lateral lobe of thyroid gland. He named them as Levator laterales. Group III muscle arise at the level of cricoid cartilage and insert on the medial surface of the lateral lobe of thyroid. They were named Levator posteriors sive dorsales.

Merckel in 1913 thought that Levator glandulae thyroidea is glandular structure though usually surrounded by muscle fibres.

Mori in 1964 did a study on levator glandulae thyroidea and classified it into 5 types as follows :

TYPE I: Hyopyramidalis: Origin from Hyoid bone, and gets inserted to the tip of pyramidal lobe.

TYPE II: Thyreopyramidalis: Origin from thyroid cartilage and gets inserted to the tip of pyramidal lobe.

TYPE III: Thyreoglandularis: Origin from thyroid cartilage and gets inserted to the sheath of thyroid gland.

TYPE IV: Hyoglandularis: Origin from Hyoid bone and get inserted to the sheath of thyroid gland.

TYPE V: Tracheoglandularis: Origin from upper trachea and inserted to the capsule of isthmus of thyroid gland

This study aims on reporting the incidence and attachment of levator glandulae thyroidea in south Indian population which may hopefully reduce the complication related to thyroid surgery.

MATERIALS AND METHODS

This study on levator glandulae thyroidea was undertaken in 50 cadavers (40 males and 10 females). 28 of them were adults and 22 foetuses. The study of the adult cadavers was undertaken in the specimens assigned for dissection of undergraduate students of Government Medical College, Kozhikode for a period of 2 years. The fetuses for the study were obtained from Institute of Maternal and Child Health attached to Government Medical College, Kozhikode. Ethical committee approval was obtained.

According to routine dissection skin, superficial fascia and investing layer of deep cervical fascia were removed. Strap muscles were detached from its origin to get a better view of thyroid gland. 2 lateral lobes and isthmus were inspected. Levator glandulae thyroidea was inspected. If present its upper and lower attachments were defined. Appropriate tables and charts were prepared for studying both the study groups (male and female).Values thus obtained were analyzed by chi square test to find out whether the observed series of frequency differ between both the study groups (Snedecor & Cochran 1967).The statistical significance or probability was expressed as P value. Statistical analysis was done by using SSP2 (Statistical package for social sciences) programme under the guidance of a statistician.

RESULTS

Levator glandulae thyroidea was seen in 13(26%) cases. Levator glandulae thyroidea was seen in 30% of cases of male and 10% of cases of female. As the P value is above 0.05 no significant statistical difference is seen among males and females.

Incidence of Levator Glandulae Thyroidea is given in table 1, chart 1,2

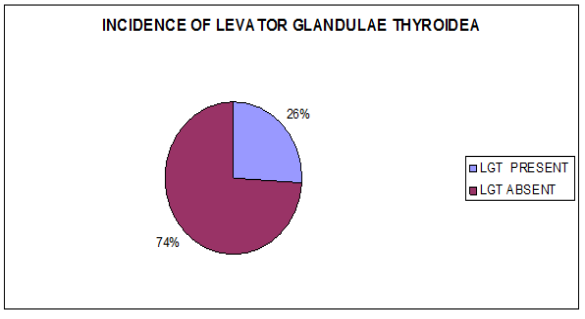

Chart 1

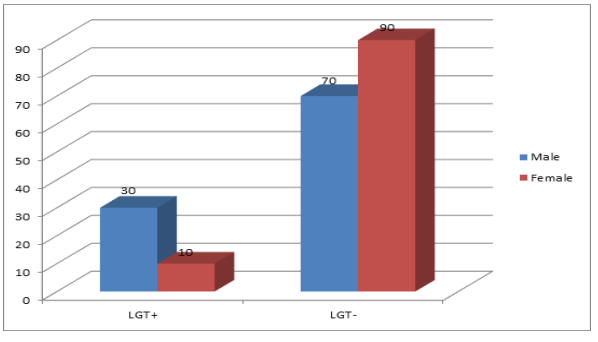

Chart 2

INCIDENCE OF LEVATOR GLANDULAE THYROIDEA

LEVATOR GLANDULA THYROIDEA	MALE		FEMALE		TOTAL	
	NO	%	NO	%	NO	%
PRESENT	12	30	1	10	13	26
ABSENT	28	70	9	90	37	74
X2 = 1.663 P VALUE = 0.197						

TABLE 1: INCIDENCE OF LEVATOR GLANDULAE THYROIDEA IN MALES AND FEMALES

Levator glandulae thyroidea was then typed according to Mori's classification.

Type I- was seen in 5 cases (Fig 1)
Type III- was seen in 6 cases (Fig 1)
Type 1V – was in 2 cases. (Fig 2)

Incidence of different types of Levator glandulae thyroidea is given in Table 2, Chart 3.

TYPES OF LEVATOR GLANDULAE THYROIDEA	NO	%
1	5	38.46
11	0	0
111	6	46.15
1V	2	15.39
V	0	0

TABLE 2: INCIDENCE OF TYPES OF LGT

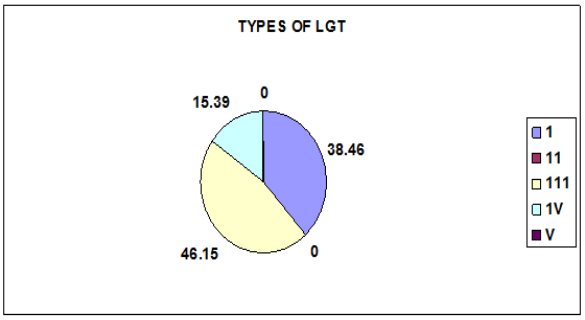

CHART 3

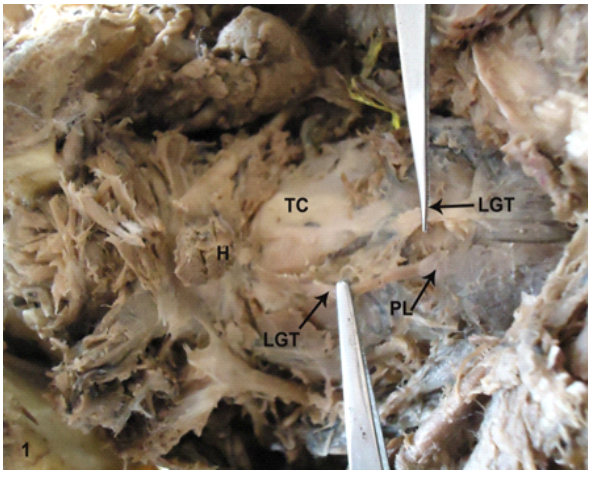

FIG 1: Two Separate Levator glandulae thyroidea, one extending from pyramidal lobe to hyoid bone(TYPE 1) and the other from sheath of thyroid gland to thyroid cartilage(type 111)(PL=Pyramidal lobe, LGT= Levator glandulae thyroidea,H=Hyoid bone, TC=Thyroid cartilage)

VOLUME-6 | ISSUE-1 | JANUARY-2017 • ISSN No 2277 - 8179 | IF : 3.508 | IC Value : 78.46

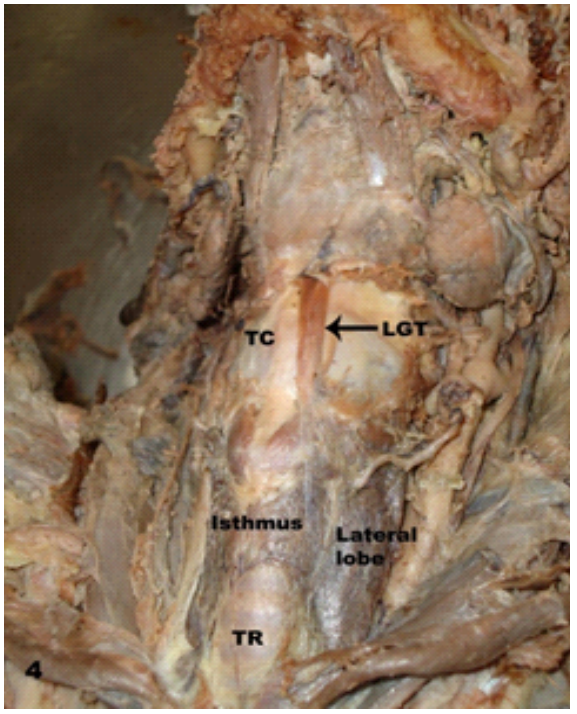

FIG 2: figure showing levator glandulae thyroidea Type IV(extending from the sheath of thyroid gland to hyoid bone)TC=Thyroid cartilage,LGT= Levator glandulae thyroidea, TR= Tracheal ring.

DISCUSSION

Levator Glandulae Thyroidea has been widely studied and its presence and attachment have been described by many workers.

In 2002, Hajjeet et al did a study to note the presence of levator glandulae thyroidea in northwest Indian population.He noted that the incidence of Levator glandulae thyroidea was 19.5%.

In 1996, Saadeh et al reported an unusual Levator glandulae thyroidea on the left side of the neck in a female cadaver. It arose from the mastoid process, extended superficially to the superior belly of omohyoid muscle and inserted into the connective tissue of the left lobe of thyroid gland.

In 2009 Loukas reported a case of thyroid gland having a small pyramidal lobe with 3 muscular slips of levator glandulae thyroidea in an 83 year old Caucasian female cadaver during a surgical mock thyroidectomy.

In the present study Levator glandulae thyroidea was observed in 26% cases. No significant statistical difference was seen between male and female group (P Value> 0.05). Comparative study of incidence of Levator glandulae thyroidea with the earlier studies is given in table 3.

The incidence of Levator glandulae thyroidea observed in the present study was more or less similar to that of Marshall (1895) Harjeet (2002) and Joshi (2010).

Regarding its superior attachment, Sultana (2009), Harjeet (2002) and Joshi (2010) opined that it was frequently attached to the hyoid bone followed by thyroid cartilage. Sultana stated that the Levator glandulae thyroidea was commonly seen arising from the pyramidal lobe and in a few from isthmus Levator glandulae thyroidea was typed according to Mori's classification and when the incidence of type 1,111, and 1V, was noted it showed a similarity to Moris study. However type 11 and V were not seen in the present study. Comparative figures are given in table 4.

NAME OF INVESTIGATOR	LGT-INCIDENCE
MARSHALL	28.30%
HAJJEET	19.50%
RANADE	49.50%
SULTANA	43.30%
JOSHI	30%
PRESENT STUDY	26%

TABLE 3: INCIDENCE OF LGT AS REPORTED IN LITERATURE

TYPES	MORI	PRESENT STUDY
I	25%	38.46%
II	0.80%	0
III	54.70%	46.15%
IV	13.30%	15.39%
V	3.30%	0

TABLE 4 :COMPARATIVE STUDY OF DIFFERENT TYPES OF LGT

CONCLUSION

This study was undertaken to study the developmental anomaly of thyroid gland namely the levator glandulae thyroidea.50 thyroid glands were dissected carefully. Incidence and attachment of levator glandulae thyroidea was noted. Photographs were taken to document each variation. Tables and charts were prepared for the statistical analysis of data. Levator glandulae thyroidea was noted in 26%. The percentage frequency of each study group (male and female) were analyzed by chi square test. As the P value obtained was found to be higher than 0.05 the difference between 2 study groups were found to be statistically insignificant. This study stresses the need of understanding the anatomy of levator glandulae thyroidea and thereby reduce the iatrogenic injuries during thyroid surgery.

REFERENCES

1. Braun E, Windisch G, Wolf G, Hausleitner L, Anderhuber F. The pyramidal lobe: clinical anatomy and its importance in thyroid surgery. Surg Radiol Anat 2007; 29:21-27.
2. Soemmerring ST. 1794. De muscularis, Tendinibus et Bursis Mucosis.Frankfurt am Main: Clossius et Schreger. p 128 (as cited by Gardiner WR. 1956. Unusual relationships between thyroid gland and skeletal muscle in infants: A review of the literature and four case reports. Cancer 9:681–691).
3. N. Dorairajan and P.V. Pradeep. Vignette Thyroid Surgery: A Glimpse into its History Int Surg. 2013 Jan-Mar; 98(1): 70–75.
4. Mori M. 1964. Statistics on the musculature of the Japanese. Okajimas Folia Anat Jpn 40:195–300 (as cited by Bergman RB, Afifi AK, Miyauchi R. 2006. Omohyoideus, Sternohyoideus, Thyrohyoideus, Sternothyroideus (Infrahyoid Muscles). Anatomy Atlases: Illustrated Encyclopedia of Human Anatomic Variation.
5. Marshall CF. Variation in the form of the thyroid in man. J Anat Physiol 1895; 29: 234-9.
6. Joshi SD, Joshi SS, Daimi SR, Athavale SA (2010) The thyroid gland and its variations: a cadaveric study. Folia Morpologica 69:47-50
7. Harjeet A, Sahni D, Indar J, Aggarwal AK (2004) Shape, measurement and weight of the thyroid gland in northwest Indians. Surg Radiol Anat, 26: 91–95.
8. Gardiner- Unusual Relationship between thyroid gland and skeletal muscle in infants. Cancer, July Aug 1956- Vol 9 page 681-91.
9. Devi sankar K, Sharmila Bhanu P, Susan PJ, Gajendra K. Agenesis of isthmus of thyroid gland with bilateral levator glandulae throideae : International Journal of Anatomical Variations (2009) 2;29-30
10. Ranade AV, Rai R, Pai MM, Nayak SR, Prakash, Krisnamurthy A, Narayana S, Anatomical variations of the thyroid gland: possible surgical implications, Singapore Med J, 2008, 49(10):831–834.
11. Godart J. Muscle de la glandethyroide, muscle de Duvernoi, musculus levator glandulae thyreoideae. (Exemple du Soemmerring.) [Abstr.] Bull Soc Anat Paris. 1847;22:202–05. French
12. Loukas M. Merbs W, Tubbs RS, Curry B, Jordan R. Levator glandulae thyroideae muscle with three slips. Anat Sci Int. 2008 Dec; 83 l4) 273-276.
13. Won HS, Chung IH. Morphologic variations of the thyroid gland in Korean adults. Korean J Phys Antropol 2002; 15:119-25.
14. Bergman RA, Afifi AK, Miyauchi R. Thyroid gland. In: Illustrated Encyclopedia of Human Anatomic Variation: Opus IV: Organ Systems: Endocrine System.
15. B.Milojevici, J.Tosevski, M.Milisavljevic,D. Babic, A. Malikovic. Pyramidal lobe of the human thyroid gland: an anatomical study with clinical implications. Rom J Morphol(2013,54(2): 285-289.
16. Moore KL, Dalley AF. Clinically Oriented Anatomy. 5th ed. Philadelphia: Lippincott Williams and Wilkins, 2006
17. Prakash, Rajini T, Ramachandran A, Savalgi GB, Venkata SP,Mokhasi V, Variations in

the anatomy of thyroid gland: clinical implications of cadaver study, Anat Sci Int, 2012, 87(1):4
18. Eisler P(1900) Der M .Levator glandulae thyroidea und verwandte pre laryngeale Muskelbildungen.Anat Anz. 17:183-196 as cited by Gardiner- unusual relationship between thyroid gland and skeletal muscle in infants. Cancer ,July Aug 1956- Vol 9 page 681-91.
19. Saadeh F A, Kawas S H, Haikal F A, Hawai J S. An unusual Levator glandulae thyroidea : a case report and literature review. J Anat .soc Ind 1996;45:125-8.
20. Sultana S Z, Khalil M, and Khan M K; Morphological study of levator glandulae thyroidea in Bangladeshi cadaver. Mymensingh Med J .2009 Jul 18(2): 179-83.
21. Winslow J B 1743: Exposition Anatomique de la shructure du corps Humain.Amsterdam: wetstein P 354 as cited by Gardiner- Unusual Relationship between thyroid gland and skeletal muscle in infants. cancer ,July Aug 1956- Vol 9 page 681-91.