Volume : 5 | Issue : 12 | December-2016 • ISSN No 2277 - 8179 | IF : 3.508 | IC Value : 78.46

Original Research Paper

A study of patients having posterior capsular rent with use of UBM

Ophthalmology

KEYWORDS: : : PCR, UBM

Dr Gunjan Tank (M.S. Ophthalmology) Consultant, Vasan eye care, Ahmedabad.

Dr. Suketu Bhapal (M.S. Ophthalmology) Consultant, Ram Krishna eye hospital.

ABSTRACT

AIM : To study patients having posterior capsular rent during cataract surgery with slit lamp examination as well as UBM and to find out complications associated with it. **MATERIAL AND METHODS :** 51 patients having posterior capsular rent during cataract surgery were evaluated as a cross sectional study. All patients underwent slit lamp examination, USG and UBM. Tononetry and fundoscopy was also performed in each case. Results are evaluated as per UBM findings. **RESULTS :** In our study 5o% of patients had peripheral anterior synechiae, 20% of patients had pupillary block, 10% patients had posterior synechiae, 8% patients had optic capture and iris bombe and 2% patients had descemet's tear and exudative membrane. In our study 84% patients of ACIOL developed glaucoma while only 8% of each tilted iol patients and SFIOL patients develop glaucoma.. As 0.55mm is normal thickness of cornea, > 90% of patient had corneal edema in our study. 34 patients were having corneal thickness more than 0.6mm. CONCLUSION : With slit lamp examination one can diagnose PC rent accurately when cornea is clear, but in patients with post operative corneal edema and non dilating pupil UBM has an important role in diagnosing PC rent and its associated changes..

With the advent of better quality microscopes, instruments and technologies, results of cataract surgery are getting better and better. Even then, complications do take place. Posterior capsular (PC) rent is the most dreaded complication that leads to unwanted squeal. It is always desirable to prevent PC rent to achieve good outcome of cataract surgery. Once PC rent occurs there are no direct methods to detect it. PC rent detection by slit lamp examination is not always possible especially when there is hazy media and non dilating pupil which is usually associated with PC rent. In such cases Ultrasound Biomicroscopy(UBM) is very helpful to detect PC rent and its associated features.

Ultrasound biomicroscopy is a new imaging technique that uses high frequency that is 35-50 MHz ultrasound to produce images of the eye at near microscopic resolution. This technique was developed in Toronto, Canada based on basic research conducted by Charles J Pavlin & Stuart Foster. It provides two dimensional images of the anterior segment of the eye. It evaluates the various anterior segment structures both qualitatively & quantitatively. In our study we evaluated 51 patients who had posterior capsular rupture during cataract surgery with UBM and slit lamp examination.

MATERIAL AND METHODS.

Ours is a cross sectional study of 51 patients who had posterior capsule rent during cataract surgery, done at tertiary eye care hospital. Patients with traumatic posterior capsular rupture and congenital presence of posterior capsular rupture were excluded from the study. Patients with good vision were not taken in the study. A thorough history including date of operation was taken. Visual acuity for distance of the patients was recorded using Snellen`s chart. Detailed slit lamp examination was done for residual lens matter,aphakic or pseudophakic, status of IOL whether in the bag or in the sulcus or in anterior chamber ,IOL centration , vitreous present in anterior chamber . Fundus examination was done using both direct and indirect ophthalmoscopy, wherever possible. Intraocular pressure was recorded in patients using Schiotz tonometer, where ever possible.

All of these patients were subjected to Ultrasound biomicroscopic examination and Ultrasound B scan. Ultrasound B scan was done in supine position by contact mode and UBM examination was done in supine position. Ultrasound biomicroscopy was performed with OTI scan 3000 model (Ophthalmic Technologies Incorporation, Toronto, Canada) with a 50 MHz transducer. After topical anaesthesia with 4% lignocaine, the eyes were studied using an eye cup filled with normal saline. Care was taken not to touch the cornea with probe. Patient was instructed to look straight up at the ceiling (figure 1,2). The probe was kept perpendicular to corneoscleral surface in constant ambient lighting condition. On USG we have seen for condition of vitreous, macular edema, presence of lens matter or fragments of nucleus in the vitrious, vitritis, retinal detachment etc. On UBM we have seen for corneal edema, AC depth, IOL position, PAS, exudative membrane, descemet's tear, optic capture, iris bombe, pupillary block, residual lens mater behind iris.

RESULTS :

In our study 5o% of patients had peripheral anterior synechiae, 20% of patients had pupillary block, 10% patients had posterior synechiae, 8% patients had optic capture and iris bombe and 2% patients had descemet's tear and exudative membrane (figure 3). In patients with posterior capsular tear, 41% patients had anterior chamber IOL, 27% patients had IOL on anterior vitreous phase, 20% patients had tilted IOL in sulcus, 8% had sulcus fixated IOL and only 4% patients were kept aphakic. So now a days trend is towards keeping patients pseudophakic as far as possible. Anterior chamber IOL is preferred if the rent is bigger. Sulcus fixated IOLs are preferred if rhexis margins are intact. If no support is found, one can go for scleral fixated IOL placement. From bum findings we have found that in patients of ACIOL, 9 patients develop PAS, 9 had papillary block, 5 had posterior synechie and 4 patients develop iris bombe. Where as in patients of tilted IOL, 7 develop PAS and 2 patients had optic capture. Exudative membrane was seen in one patient of sclera fixation IOL.

We found that in patients of ACIOL, haptic was pushing iris in 2 patients, in angle in 2 patients and touching endothelium in 2 patients. While in tilted IOL patients, haptic was pushing iris in 6 patients and was touching ciliray body in 4 patients. Iris push and ciliary body touch are mostly found in tilted IOL in sulcus, other haptic related complication like angle disturbance, endothelium touch and post synechia are mostly found in patients with anterior chamber IOL placement. In our study 84% patients of ACIOL developed glaucoma while only 8% of each tilted iol patients and SFIOL patients develop glaucoma. Uveitis due to uveal tissue irritation was noticed in 33% each that is in patients with tilted IOL, SFIOL and IOL in vitreous. As 0.55mm is normal thickness of cornea, > 90% of patient had corneal edema in our study. 34 patients were having corneal thickness more than 0.6mm.

DISCUSSION :

Ultrasound biomicroscopy is a new imaging technique that uses high frequency ultrasound to produce images of the eye at near microscopic resolution. This technique was developed in Toronto, Canada based on basic research conducted by Charles J Pavlin & Stuart Foster. It provides two dimensional images of the anterior segment of the eye. It evaluates the various anterior segment

Volume : 5 | Issue : 12 | December-2016 • ISSN No 2277 - 8179 | IF : 3.508 | IC Value : 78.46

structures both qualitatively & quantitatively. UBM uses a scan transducer having a frequency of 35—50 MHz or more in contrast to conventional USG that uses 7.5 – 10 MHz each pulse will excite the electrodes of the piezoelectric crystal of the transducer generating sound waves. The returning echoes are received by the transducer & transformed into electric signals. These signals are processed in the receiver & demodulator & than displayed on the screen of display unit. UBM provides 25 micron axial & 50 micron lateral resolution. The OTI scan 3000 software runs on windows & use the features of windows interface to direct the operation of the system & maintain patient records, permitting user friendly environment for clinical application & maintainance. The surface of 35MHz &50MHz transducers & the probe connector are gold plated. At the time of examination, the transducer and the probe are immersed in saline. The salts can build up on these, thus reducing the quality of the image. Excessive rubbing of gold plated surface may damage it & thus reducing the quality of the image. The probe end & the transducer can be cleaned,,.

AC-IOLs were used for eyes with a large or peripheral rent in posterior capsule. The capsular support available was minimal, I/A was sometimes incomplete with resultant iridocyclitis. The vitreous disturbance was also greater due to the larger rent in posterior capsule, some I/A done in presence of vitreous in AC and a greater loss of vitreous volume. So rate of PAS and posterior synechie are more with ACIOL. As well as rate of developing glaucoma was also more in ACIOL patients. Proper sulcus fixated IOL is having good outcome as compared to ACIOL in our study.

CONCLUSIONS:

Posterior capsular rupture is one of the dreaded but preventable complications of extracapsular cataract surgery. With slit lamp examination one can diagnose PC rent accurately when cornea is clear, but in patients with post operative corneal oedema and non dilating pupil UBM has an important role in diagnosing PC rent and its associated changes. After PC rent patient is left aphasic or managed by ACIOL, sulcus fixated IOL and scleral fixation of lens.Tilting of IOL is mostly seen with sulcus fixated IOL.Glaucoma is mostly seen with patients with ACIOL.Low grade of uveitis is common due to uveal touch of IOL or residual lens matter and vitreous disturbances. These complications can be prevented if PC rent is properly managed.UBM in cases of PC rent helps to decide further line of management.

Figure 1 : This is the UBM picture showing pc rent with aphakia with PAS and posterior synechia and iris bombe formation

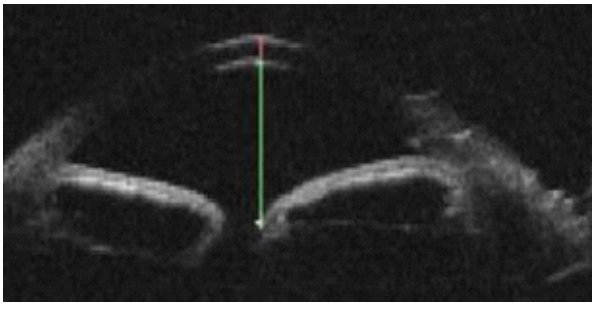

Figure 2: This is the UBM picture showing tilted IOL and posterior synechiae with residual lens matter behind iris pushing iris forwards causing PAS.



Figure 3 : Finding in UBM in 51 cases with PC rent

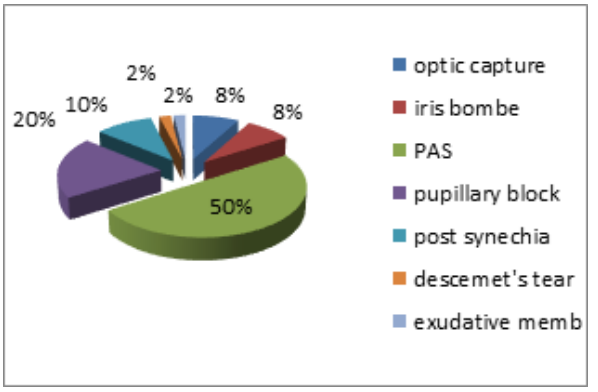

Referances :

1. Pavlin CJ. Interpreting technology. Practical application of ultrasound biomicroscopy. Can J Ophthalmol 1995; 30(4): 225–229.
2. Pavlin CJ, Harasiewicz K, Sherar MD, Foster FS. Clinical use of ultrasound biomicroscopy. Ophthalmology 1991; 98: 287–295.
3. Chang, D. F. "Strategies for Managing Posterior Capsular Rupture in Phaco Chop," in Mastering Techniques, Optimizing Technology, and Avoiding Complications (Thorofare, N.J.: Slack Inc., 2004
4. Liebmann JM, Ritch R, Esaki K. Ophthalmic imaging and diagnostics. Ultrasound biomicroscopy. Ophthalmol Clin North Am 1998; 11(3): 421–433
5. Ultrasound biomicroscopy. High frequency ultrasound imaging of the eye at microscopic resolution. Radiol Clin North Am 1998; 36:1047-58.
6. J Am Optom Assoc. 1996 Aug; 67(8) : 469-79. Ultrasound biomicroscopy of the anterior segment. Liebmann JM Ritch R.Department of Opthalmology, New York Eye and Ear Infirmary, NewYork 10003, USA