ORIGINAL RESEARCH PAPER VOLUME-6 | ISSUE-8 | AUGUST - 2017 | ISSN No 2277 - 8179 | IF : 4.176 | IC Value : 78.46

INTERNATIONAL JOURNAL OF SCIENTIFIC RESEARCH

A STUDY OF ROLE OF HYSTEROSCOPY IN ABNORMAL UTERINE BLEEDING

Gynaecology

Dr. Meenal Patvekar Professor, Dr. D. Y. Patil Medical College, Pimpri, Pune

Dr. Dipak Kolate Assistant professor, Dr. D. Y. Patil Medical College, Pimpri, Pune - Corresponding Author

Dr. Gazal Garg Dr. D. Y. Patil Medical College, Pimpri, Pune

Dr. Yogesh Thawal Associate professor, Dr. D. Y. Patil Medical College, Pimpri, Pune

ABSTRACT

Abnormal uterine bleeding (AUB) is one of the most common gynaecological disorders that prompt a patient to consult a physician. In our study 60 patients of abnormal uterine bleeding were examined systematically with office hysteroscopy. Findings of hysteroscopy were compared with histopathological examination. The diagnostic value of hysteroscopy as compared with histopathology in our study was 100 % as regards to most of intrauterine pathologies including submucous myoma, endometritis, retained products of conception, adenomyosis and endometrial carcinoma. Hysteroscopy has left its indelible mark in the evaluation of patients with abnormal uterine bleeding. Hysteroscopy provides the possibility of immediate diagnosis and allows prompt and effective treatment in patients with abnormal uterine bleeding.

KEYWORDS:

Abnormal uterine bleeding, Hysteroscopy, Endometrial Polyp, Submucous myoma

INTRODUCTION

Abnormal Uterine Bleeding (AUB) is a symptom not a disease. Though uterine bleeding is a normal physiological episodic occurrence for most women, the broad range of normal variation causes difficulty in identifying abnormal patterns. Any bleeding that is excessive or reduced than normal in duration, frequency or amount for a particular patient should be considered abnormal and investigated accordingly (1).

Various investigating modalities have been developed to diagnose intra uterine abnormalities for AUB – such as two dimensional and three dimentional ultrasound, saline infusion sonography, endometrial biopsy, hysteroscopy and hysteroscopic guided biopsies. Adding a visual dimension to the examination, hysteroscopy provides the ability to explore visually previously inaccessible areas within the uterine cavity and therefore, adds precision and accuracy (2). The recent technical advancement i.e. improvement in uterine distension methods and smaller diameter hysteroscopes have made it possible for hysteroscopy to move from the traditional hospital setting into the physician's office.

The present study has been undertaken to define the diagnostic value of hysteroscopy in evaluating the uterine cavity in patients with AUB and compare hysteroscopic findings with histopatho-logical diagnosis which is the gold standard.

AIMS AND OBJECTIVES

1. To determine the value of hysteroscopy in women with AUB.
2. To correlate hysteroscopic and histopathological findings in patients of AUB

MATERIALS AND METHOD

The demographic details of patients were taken and necessary investigations to complete the profile were done as per protocol. Office hysteroscope 2.9 mm was used, with normal saline as the distending media. Hysteroscopic examination of the whole of uterine cavity and endometrium was done systematically by vaginoscopic method and results were recorded. Biopsy was taken and sent for histopathological examination for the purpose of confirmation. Whenever needed, operative hysteroscopy was performed to treat the cause. Women were discharged on the same day of the procedure.

OBSERVATION AND RESULTS

Among the 60 patients of AUB 40 % of patients were in the age group of 46 to 55 years. However, Overall 55% of cases with AUB, presented in the reproductive age group of 26 to 45 years.

The most common presenting symptoms were menorrhagia and polymenorrhagia. Postmenopausal bleeding accounted for 13.33% of the cases.

GRAPH 1:-
ASSOCIATION BETWEEN AGE AND PATTERN OF AUB

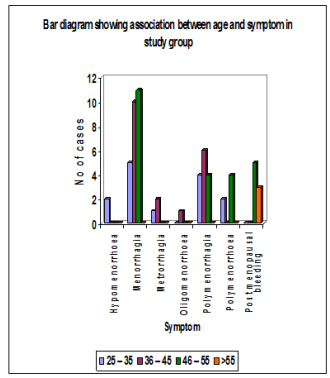

The most common finding detected in our series of cases were endometrial polyps, which constituted nearly 26% of the patients followed by submucous myoma, seen in 23% of cases. Normal looking functional endometrium was observed in 18% of cases. Findings of hysteroscopy were compared with histopathology.

TABLE 1 :-
HYSTEROSCOPY FINDINGS

Hysteroscopy Findings	No. of cases	Percentage
Endometrial Polyp	16	26.67
Submucous Myoma	14	23.33
Normal Endometrium	11	18.33
Endometrial Hyperplasia	7	11.67
Retained Products of conception	4	6.67
Endometritis	3	5
Intrauterine Adhesion	1	1.67
Adenomyosis	2	3.33
Endometrial Atrophy	1	1.67
Endometrial Carcinoma	1	1.67

TABLE 2: -
ASSOCIATION BETWEEN HYSTEROSCOPY FINDING AND PATTERN OF AUB

Hysteroscopy finding	Symptoms							Total
	Hypomenorrhoea	Menorrhagia	Metrorrhagia	Oligomenorrhoea	Polymenorrhagia	Polymenorrhoea	Postmenopausal bleeding	
Endometrial polyp	0	4	1	0	8	0	3	16
Submucous myoma	0	11	0	0	2	0	1	14

Normal endometrium	0	5	0	0	0	6	0	11
Endometrial hyperplasia	0	4	0	0	1	0	2	7
Retain products of conception	0	0	1	0	3	0	0	4
Endometritis	2	0	1	0	0	0	0	3
Adenomyosis	0	2	0	0	0	0	0	2
Adhesions	0	0	0	1	0	0	0	1
Endometrial carcinoma	0	0	0	0	0	0	1	1
Total	2	26	3	1	14	6	8	60

TABLE 3:-
COMPARISON HYSTEROSCOPY AND HISTOPATHOLOGY FINDINGS IN PATIENTS WITH AUB

Intrauterine pathology	Hysteroscopy N =60		Histopathology N = 60		Correlation between hysteroscopy and histopathology
	No.	%	No.	%	
Endometrial Polyp	16	26.67	14	23.33	87.5%
Submucous Myoma	14	23.33	14	23.33	100%
Normal Endometrium	11	18.33	9	15	81.88%
Endometrial Hyperplasia	7	11.67	11	18.33	71%
Retained products of conception	4	6.67	4	6.67	100%
Endometritis	3	5	3	5	100%
Adenomyosis	2	3.33	2	3.33	100%
Intrauterine Adhesion	1	1.67	1	1.67	100%
Endometrial Carcinoma	1	1.67	1	1.67	100%
Endometrial Atrophy	1	1.67	1	1.67	100%

Histopathology is an authenticated investigation in diagnosing and planning the treatment of patients with AUB. The above table shows the correlation between hysteroscopy and histopathological findings, which was the main stay of study.

In case of endometrial polyp out of 16 cases 14 were confirmed on histopathology whereas two cases were false positive. Thus correlation between hysteroscopy and histopathology for endometrial polyp was about 87.5 %.

Correlation between hysteroscopy and histopathology for submucous myoma, retained products of conception, endometritis and intrauterine adhesions was found to be 100%.

In our study least correlation was found in cases of endometrial hyperplasia. There were 7 cases suspected to have endometrial hyperplasia on hysteroscopy, out of which 5 were confirmed on histopathology and remaining two revealed normal endometrium. Whereas 4 more cases of endometrial hyperplasia were found on histopathology.

TABLE 4:-
SENSITIVITY AND SPECIFICITY OF HYSTEROSCOPY IN RELATION TO HISTOPATHOLOGY

	Sensitivity a/ (a+c)	Specificity d/ (b+d)	Positive predictive value	Negative predictive value
Endometrial Polyp	100	95.65	87.5	100
Submucous Myoma	100	100	100	100
Normal Endometrium	77.78	92.16	63.64	95.92
Endometrial Hyperplasia	54.55	97.96	85.71	90.57
Endometrial Atrophy	100	100	100	100
Intrauterine Adhesion	100	100	100	100
Endometrial Carcinoma	100	100	100	100
Retained Products Of Conception.	100	100	100	100

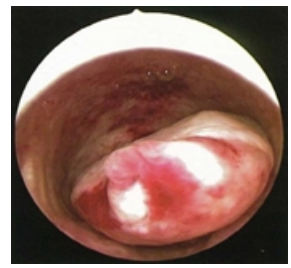

Picture 1: Endometrial Polyp

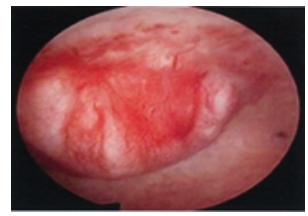

Picture 2 : Submucous Myoma

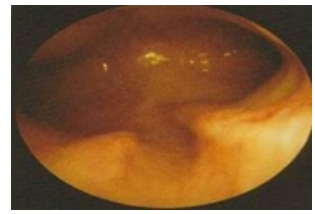

Picture 3: Endometrial Hyperplasia – increased endometrial thickness

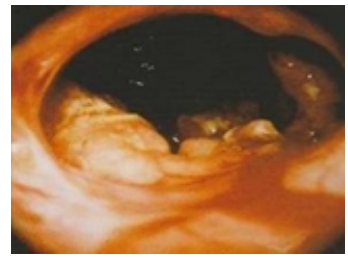

Picture 4: Endometrial Carcinoma

DISCUSSION

Regular cyclical menstruation is the result of choreographed relationship between the endometrium and its regulating factors. Disturbance in either of these factors results in abnormal uterine bleeding. AUB includes array of conditions like hormonal dysfunctions, infection, neoplasia, coagulopathies and complications of pregnancy. Abnormal uterine bleeding is a challenging condition for the gynaecologist and accounts for more than 20% of office visits (3) . Assessing the cause of AUB in a clinical setting has its own limitations. The frustrating part of the traditional investigative procedures for AUB is that, very little can be diagnosed with accuracy. In today's era of technological advancements a "see and treat" concept is preferred.Dilatation and curettage, which used to be the mainstay for investigations of AUB is not accurate and focal intrauterine lesions can be missed (4).

Majority of the cases belonged to the age group of 46 to 55 years (40%). Overall 55% of cases with AUB, presented in the reproductive age group of 26 to 45 years and comparable with other studies (3,5).

Age has always had a bearing with AUB, having different reasons in adolescents, reproductive age group, peri- and postmenopausal age group. It is well understood that transition from reproductive to premenopausal age group is associated with hormonal disturbances and benign or malignant neoplastic growth.

In our study menorrhagia was seen foremost in 43% of patients and was the commonest pattern observed. Polymenorrhagia presented in 23.3% of patients followed by postmenopausal bleeding in 13.33% of

cases. In a similar study, researcher found majority of the patients (62%) presented with menorrhagia while postmenopausal bleeding was present in 14% of the patients comprising the second most common group(3).

In our review endometrial polyp was the most common cause of AUB comprising 26.67% of total cases followed by submucous myoma attributed to 23.33% , which is consistent with previously published literature (5).

Endometrial Polyp The incidence of endometrial polyps on hysteroscopy was 26% whereas, histopathology confirmed 23% of cases. Therefore, the diagnostic accuracy of hysteroscopy for endometrial polyp was 87.5%. In similar studies reported 88.6% of the diagnostic accuracy for endometrial polyp (7,8).

Submucous Myoma Our study depicts submucous myoma as the second most common cause of AUB on hysterosopy accounting for 23% of patients. All cases of submucous myomas were confirmed on histopathology. Therefore the diagnostic accuracy of hysteroscopy for endometrial myoma in our study was 100%. Similar findings were reported by previous studies (14,15).

Endometrial Hyperplasia was present in 11% of patients on hysteroscopy whereas histopathology revealed hyperplasia in 18 % of cases. The diagnostic accuracy of hysteroscopy was 71%, which was least amongst all pathologies. Similar findings were reported in literature (7,8,14). This shows that hysteroscopy has intermediate accuracy in detection of premalignant lesions and mandates a directed endometrial biopsy for confirmation (8,9,10).

Endometrial Carcinoma was recognized on hysteroscopic examination in only one patient which accounts to be 1.67%.

The case of Endometrial Carcinoma suspected on hysteroscopy was confirmed on histopathology. Thus the accuracy of hysteroscopy for endometrial carcinoma becomes 100%, which is consistent with previous studies (7,14).

Normal looking functional endometrium was observed in 18% of the patients with AUB. However, only 15% cases were confirmed on histopathology. In this study the diagnostic accuracy of hysteroscopy for normal endometrium was 81%. Accuracy of 92.5% was reported by another Indian study, which was close to our study (14).

In our study, we compared the hysteroscopic findings with the pathology reports in women with AUB. The detection of Endometrial Polyp by hysteroscopy had a sensitivity of 100% and negative predictive value (NPV) of 100%. This is consistent with other study (5).

Hysteroscopy was 100% sensitive and specific for submucous myoma, atrophic endometrium, RPOC (retained products of conception), endometrial carcinoma and intrauterine adhesions. This is comparable to other similar studies (7,14).

However above results show least sensitivity for endometrial hyperplasia. Hysteroscopy was found to be 54.55% sensitive and 97.96% specific for endometrial hyperplasia. Therefore the results of our study were comparable to the other studies (3,5).

Thus, this study shows that hysteroscopy is a reliable method for evaluation of AUB, especially in benign lesions such as endometrial polyp and submucous myoma. It can be used as a first line diagnostic method for these abnormalities. However, hysteroscopy without directed biopsy has insufficient value in cases of endometrial hyperplasia and endometrial carcinoma. Therefore, hysteroscopy in combination with curettage should be considered in AUB to increase its sensitivity as well as positive predictive value.

CONCLUSION

Hysteroscopy has left its indelible mark in the evaluation of patients with abnormal uterine bleeding and has created a radical paradigm shift in terms of traditional thought. The diagnostic value of hysteroscopy as compared with histopathology in our study was 100 % as regards to most of intrauterine pathologies including submucous myoma and endometrial polyps but was relatively less for diagnosing endometrial hyperplasia. Therefore, hysteroscopy should be combined with curettage to increase its sensitivity. Hysteroscopy has the advantage of diagnosing treating some intrauterine pathologies in the same setting. With the recent technological advancements, hysteroscopy is gold standard in the evaluation of abnormal uterine bleeding.

REFERENCES

1. Speroff L, Fritz MA. Clinical Gynecologic Endocrinology and Infertility.7th edition. Philadelphia: Lippincott Williams & Wilkins; 2005. p. 187-234.
2. Bonnamy L, Marret H, Perrotin F, Body G, Berger C, Lansac J. Sonohysterography: A prospective survey of results and complications in 81 patients. Eur J Obstet Gynecol Reprod Bio. 2002;102:42–47
3. Madan M, Zainab, Jufairi A. Saudi Med Journal. 2001;vol 22(2):153-56
4. Word B, Gravlee LC, Wideman GL. The fallacy of simple uterine curettage. Obstet Gynecol. 1958;12:642
5. Tajossadat Allameh and Fareshteh Mohammadizadeh. Iranian J of Reproductive Medicine. 2007;(Vol 5) 261-64.
6. Alanis Fuentes J. office hysteroscopic polypectomies: 8 years analysis. Ginecol Obstet Mex.2007;75(6):341-6.
7. Valle RF. Hysteroscopic evaluation of patients with abnormal uterine bleeding . Surg Gynecol Obstet. 1981;153:521-6.
8. Sheth S, Hamper VM, Kurman R et al. A study between hysteroscopy with directed biopsies and dilatation and curettage. Am J Obstet Gynecol. 1989;158:489
9. Refaie A, Anderson T, Cheah S. Out-patient hysteroscopy: finding and decision making for treatment of abnormal uterine bleeding in pre and postmenopausal women. 2005;10(1):43-48.
10. Fay TN, Khanem N, Hosking D. Outpatient hysteroscopy in asymptomatic postmenopausal women. Climateric. 1999;2:263-267.
11. Loverro G, Bettochi S, Cormino G et al. Diagnostic accuracy of hysteroscopy in endometrial hyperplasia. Maturitas. 1996;25:187-191.
12. Fakhar S, Mahmud G. Validity of hysteroscopy and histopathology in patients with menstrual irregularities, J Ayub Med Coll Abbottabad. 2010; 22(1):129-132.
13. Patil SG, Bhute SB, Inamdar SA, Acharya NS, Shrivastava D. Role of diagnostic hysteroscopy in abnormal uterine bleeding and its histopathologic correlation. 2009; 1: 98-104.
14. Panda A, Parulekar SV, Gupta A. Diagnostic hysteroscopy in abnormal uterine bleeding and histopatholigical correlation. J Obstet Gynecol India. 1999;49,74-76.
15. Acharya Veena, Mehta S, Randar A. Evaluation of dysfunctional uterine bleeding by TVS, hysteroscopy and histopathology. J Obstet Gynecol India. 2003;53:17-7.