ORIGINAL RESEARCH PAPER

Volume-8 | Issue-1 | January-2019 | PRINT ISSN No 2277 - 8179

INTERNATIONAL JOURNAL OF SCIENTIFIC RESEARCH

A STUDY OF SURGICAL AND FUNCTIONAL OUTCOMES OF HEMI-ARTHROPLASTY IN FRACTURE NECK OF FEMUR

Orthopaedics

Dr Jalaluddeen MV Associate Professor, Department of Orthopedics, Kanachur Institute of Medical Sciences, Mangalore

Dr Hashir Safwan U* Associate Professor, Department of Orthopedics, Kanachur Institute of Medical Sciences, Mangalore *Corresponding Author

ABSTRACT

Older generation in the 6th decade and above often suffer from fracture neck femur. Hemi-arthroplasty has been the treatment of choice in these patients. The morbidity and mortality with this type of surgery is taken as a measure the outcome. The patient satisfaction, quality of life which he will lead should ideally be the indicators of the outcome. This study puts in a sincere effort to evaluate the outcome of hemi-arthroplasty after the patient suffers the fracture neck femur.

KEYWORDS

Fracture neck femur, hemi-arthroplasty, Functional outcome, quality of life

INTRODUCTION:

Injury by a fall is one of the leading cause of injuries and hospital admissions in the elderly population especially the female population.[1] Femoral neck fractures is one of the most commonest and accounts for 80 - 90% of hip fractures. [2] In a country like ours it contributes for loss of work-days and thus results in Economic burden. Fracture neck of femur is coupled with poor bone quality and loss of fixation as the common problems of attempts to fix these fractures. Displaced intracapsular fracture of the femoral neck can be treated with internal fixation, unipolar or bipolar arthroplasty or total hip replacement, but each has disadvantages and the optimal treatment of these fractures remains controversial.[3] Despite good results achieved with total hip replacement, the trend in our hospital is to treat any type of intracapsular hip fracture with hemi arthroplasty[4,5]. The morbidity and mortality with this type of surgery is taken as a measure the outcome. The patient satisfaction, quality of life which he will lead should ideally be the indicators of the outcome. This study puts in an effort to evaluated the functional outcome in addition to surgical outcomes of hemiarthroplasty in fracture neck of femur in these elderly patients.

Aims and Objectives:

To evaluated the functional outcome in addition to surgical outcomes of hemiarthroplasty in fracture neck of femur in these elderly patients.

METHODS:

This study conducted in the department of orthopedics at Kanachur Institute of Medical Sciences, Mangalore.

Thirty patients were included in the study that underwent hemi-arthroplasty.

All patients above 60 years undergoing hemi replacement arthroplasty treatment for fracture neck of femur during the period 2017-2018 were studied.

Inclusion Criteria:

- Patients were selected who were above 60 years.

Exclusion Criteria:

- Patients with basitrochanteric fracture,
- infection,
- fracture neck of femur more than one year,
- unfit for anesthesia,
- refusal for consent,
- associated fractures or polytrauma and pathological fractures

STATISTICALANALYSIS:

- ANOVA was used to assess the difference between functional scores.
- A two tailed p value less than 0.05 was considered statistically significant.

RESULTS:

Table 1: Age Distribution

Number	Mean age	Std Deviation
30	71.66 years	6.84 years

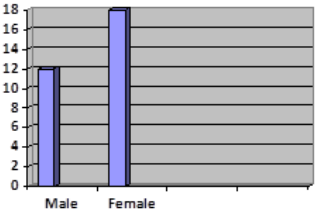

Graph 1: Sex Distribution

Table 3: Clinical Presentation

Presentation	
H/O trauma	100%
Inability to walk	83.33%
Limb Shortening	16.66%
Mass in anterior part of thigh	33.33%
Mal-Rotation of limb	10%

Table 4: HHS Surgical Outcome

Pre-Operative	Post-Operative (1 Month)	Post-Operative (6 Month)	P-Value
21.67± 7.74	56.34± 5.26	71.92± 3.55	<0.001

Table 5: VAS Score:

Pre-Operative	Post-Operative (1 Month)	Post-Operative (6 Month)	P-Value
7.24± 1.67	4.1± 0.98	2.02±0.76	<0.001

DISCUSSION:

The mean age of patients was 71.66±6.84 yrs and male: female ratio was 12: 18. The mean HHS score was 71.92± 3.55by the end of six months. The mean pain score on VAS Scale was reduced to 2.02±0.76 at six months follow-up visit.

Bhandari et al[6] found that many orthopaedic surgeons felt that the short-term outcome following hemiarthroplasty was comparable with that after a THR. Early wear on the acetabular cartilage may be one explanation of the difference in hip function between THR and hemiarthroplasty in our own and previous studies.[7]

Walia et al.,[8] reported the superiority of total hip replacement in terms of control of pain, however, they also highlighted certain drawbacks of total hip replacement arthroplasty in elderly patients such as instability, impaired reflexes, cognitive impairment, higher dislocation rates.

Fan et al.,[9] in their study reported bipolar hemiarthroplasty to provide comparable results with total hip arthroplasty in terms of hospitalization period, general complications, joint function, pain, rate of revision and mortality. Though the present study was not a comparative study, yet it provided promising results with achievement of remarkable functional ability and pain control. In present study no significant complication were seen in postoperative period but they all resolved with proper medical care by six week follow up. No patient required revision surgery. These results are similar to the results obtained by Sancheti et al.,[10]

CONCLUSION:

The functional outcome of hemiarthroplasty in fracture neck of femur in elderly patients is satisfactory and we strongly recommend this procedure.

REFERENCES:

1. Alexander BH, Rivara FP, Wolfe ME. The cost and frequency of hospitalization for fall related injuries in older persons. Am J Public Health. 1992; 82: 1020-23.
2. Dahl E. Mortality and life expectancy after hip fractures. Acta Orthop Scand. 1980; 51(1): 163-70.
3. Kenzora, John E. MD; Magaziner, Jay PhD, MSHyg; Hudson, James MD; Hebel, J. Richard PhD; Young, Yuchi DPhil; Hawkes, William PhD; Felsenthal, Gerald MD; Zimmerman, Sheryl Itkin PhD; Provenzano, George PhD. Outcome After Hemiarthroplasty for Femoral Neck Fractures in the Elderly. Clinical Orthopaedics & Related Research: March 1998, Volume 348 - Issue pp: 2-285
4. WH. Traumatic arthritis of the hip after dislocation and acetabular fractures: treatment by mold arthroplasty. An end-result study using a new method of result evaluation. J Bone Joint Surg Am. 1969 Jun; 51(4): 737-55.
5. Marchetti P, Binazzi R, Vaccari V, Girolami M, Morici F, Impallomeni C, Commessatti M, Silvello L. Long-term results with cementless Fitek (or Fitmore) cups. J Arthroplasty. 2005 Sep; 20(6): 730-7.
6. Bhandari M, Devereaux PJ, Tornetta P 3rd, et al. Operative management of displaced femoral neck fractures in elderly patients: an international survey. J Bone Joint Surg [Am] 2005; 87-A: 2122–30.
7. Keating JF, Grant A, Masson M, Scott NW, Forbes JF. Randomized comparison of reduction and fixation, bipolar hemiarthroplasty, and total hip arthroplasty: treatment of displaced intracapsular hip fractures in healthy older patients. J Bone Joint Surg [Am] 2006; 88-A: 249–60.
8. Walia JPS, Sansanwal D, Walia SK, Singh S, Gupta AC. Role of primary bipolar arthroplasty or total hip arthroplasty for the treatment of intertrochanteric fracture femur in elderly. Pb Journal of Orthopaedics. 2011; 12(1): 5-9.
9. Fan L, Dang X, Wang K. Comparison between Bipolar Hemiarthroplasty and Total Hip Arthroplasty for Unstable Intertrochanteric Fractures in Elderly Osteoporotic Patients. PLoS One. 2012; 7(6): e39531.
10. Sancheti KH, Sancheti PK, Shyam AK, Patil S, Dhariwal Q, Joshi R. Primary hemiarthroplasty for unstable osteoporotic intertrochanteric fractures in the elderly: A retrospective case series. Indian J Orthop. 2010; 44(4): 428–34.