Research Paper

Volume : 2 | Issue : 2 | Feb 2013 • ISSN No 2277 - 8179

A Study of The Intraoccular Pressure and Cardiovascular Changes During Insertion of Laryngeal Mask Airway

Medical Science

KEYWORDS : General Anesthesia, Elective Surgery Laryngeal mask airway Intraocular pressure, Cardiovascular changes.

Dr. Gauri Panjabi — Assistant professor, Dept. of Anesthesia, Smt. Shardaben general hospital, Ahmedabad.

Dr. Shivang Joshi — Smt. Shardaben General Hospital, Ahmedabad. Dept. of Anesthesia, Saraspur, Ahmedabad.

ABSTRACT

The study was carried out in 60 ASA I/II patients undergoing various elective surgery under General anesthesia. All patients were premedicated with I.V. Midazolam 1mg, Inj. Fentanyl 2µg/kg and Glycopyrolate 2mg, 10 minutes before surgery. 2 to 3 drops of tropical lignocaine 4 % was instilled into both the eyes. IOP was measured by an ophthalmologist with a Schiotz tonometer. Following Pre oxygenation for 3 minutes, induction of anesthesia achieved with propofol 2.5-3mg/kg. LMA was lubricated on the posterior surface and inserted after eyelash reflex lost. Anesthesia was maintained with oxygen, nitrous oxide and Halothane. The IOP and cardiovascular changes were recorded preoperatively as well as at regular intervals after LMA insertion. Mean IOP changes showed decreasing trend from baseline and remained low throughout the surgery. Mean pulse rate was increased at the time of insertion of LMA (5-10/min.) but reached to baseline values within 10 min. MAP and ECG showed no significant changes during surgery. The incidence of postoperative complications like cough, sore throat and vomiting were very less and mild in nature.

INTRODUCTION:

Tracheal intubation is performed routinely during general anesthesia in patients undergoing intraocular surgery. It is well known that the laryngoscopy, tracheal intubation and drugs particularly succinylcholine cause intense autonomic responses such as tachycardia, hypertension, and rise in IOP. This study assessed the suitability of the laryngeal mask airway (LMA) as a substitute for tracheal intubation. [1]

The normal intraocular pressure may be affected in variety of perioperative events. The IOP and cardiovascular changes varies with drugs used like succinylcholine and instrumentation during General anesthesia.

LMA is cost effective supraglottic device used in maintaining airway during GA. Advantages of LMA are ease of insertion, avoidance of laryngoscopy and muscle relaxant.

This problem has drawn the attention of many workers to study the attenuation of these responses with some pretreatment or by some alternative to laryngoscopy and tracheal intubation viz. LMA. Lignocaine pre-treatment either intravenous or nebulised, has been used to attenuate ocular and systemic responses to laryngoscopy and tracheal intubation.[2],[3],[4] Intranasal nitroglycerine has also been evaluated to prevent increase in IOP associated with tracheal intubation.[5]

LMA, as an alternative to endotracheal tube has attracted the attention of many workers with regards to IOP changes, as it obviates the need for laryngoscopy and tracheal intubation. Reports suggest that LMA insertion is associated with reduced stress response both systemic and ocular during GA.

This study was designed to determine the intraocular pressure and cardiovascular changes - arterial pressure, heart rate and ECG during insertion of LMA.

METHODS

This study was conducted in 50 ASA 1 and 2 patients aged between 20 to 45 years scheduled for elective surgery. All patients were preoperatively assessed and written informed consent taken. Patients with reduced mouth opening and hypertensive patients were excluded from our study.

All patients were premedicated with I.V. Midazolam 1mg, Inj. Fentanyl 2 µg/kg and Glycopyrolate 0.2 mg, 10 minutes before surgery. 2 to 3 drops of tropical lignocaine 4 % was instilled into both the eyes. IOP was measured by an ophthalmologist with a Schiotz tonometer. The average IOP in both the eyes was taken as baseline reading. Baseline cardiovascular parameters - noninvasive blood pressure and electrocardiogram were recorded.

Following pre oxygenation for 3 minutes, induction of anesthesia was achieved with propofol 2.5 -3 mg/kg until loss of eyelash reflex. LMA was lubricated on the posterior surface and inserted after loss of eyelash reflex.

Anesthesia was maintained with oxygen, nitrous oxide and Halothane. Patient's vitals and IOP were measured just after induction, 2 min., 5 min.,10 min after LMA insertion and just before extubation.

After completion of surgery, LMA was taken out under deeper plane of anesthesia after deflating the cuff and suctioning the secretions, if present. All patients were observed for postoperative complications like sore throat, cough and vomiting.

RESULTS

DEMOGRAPHIC DATA:

50 ASA grade I/II patients between 20-45 years of age of either sex, undergoing elective surgery were taken for study of the intraocular pressure and cardiovascular changes during insertion of LMA. Average duration of study was around 1-2 hrs.

Time to loss of eyelash reflex was taken as mean induction time, it was around 61.88±5.64 sec.

During LMA insertion 18 patients (30%) developed apnoea (>30 sec.) while patient movement was observed in 2 patients (3.3%). Coughing/Gagging and Laryngospasm/Bronchospasm was not observed in any patient.

TABLE 1; IOP CHANGES:

STAGES OF INSTUMENTATION	IOP(mm of Hg)
BASE LINE	15.60±1.35
JUST BEFORE LMA INSERTION	11.90±1.14
2 min. AFTER LMA INSERTION	11.40±0.95
5 min. AFTER LMA INSERTION	11.80±1.56
10 min. AFTER LMA INSERTION	12.40±1.51
JUST BEFORE EXTUBATION	13.76±1.8

IOP decreased subsequently below baseline values after LMA insertion. Preoperative Mean IOP was 15.60 mm. of Hg. Mean IOP changes at different stages have shown a decreasing trend from base line. It was found that after LMA insertion IOP came down to 11 - 14 mm. of Hg. from base line reading.

TABLE 2; CARDIOVASCULAR CHANGES

STAGES OF INSTUMENTATION	MEAN PULSE (Per min.)	Mean Arterial Pressure (mm of Hg.)
BASE LINE	78±4.28	95.3±5.64

JUST BEFORE LMA INSERTION	84±4.63	92.7±4.92
2 min. AFTER LMA INSERTION	86±5.52	88±4.64
5 min. AFTER LMA INSERTION	88±5.63	90.7±4.97
10 min. AFTER LMA INSERTION	80±3.99	94.9±4.84
JUST BEFORE EXTUBATION	82±5.27	97.3±5.64

Cardiovascular changes were monitored at every corresponding stage of IOP measurement. The cardiovascular stimulation response was very less following LMA insertion.

Pulse increased by about 5 - 10 / min. at the time of insertion but reached to base line within 10 min.

No significant change in Mean Arterial Pressure was noted. Immediately 2 min. after LMA insertion MAP was decreased by 7-8 mm of Hg. but reached to base line within 10 min.

ECG showed no significant changes.

TABLE 3; Postoperative complication

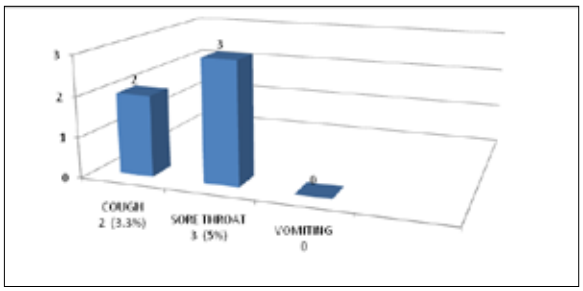

Next day patients were interviewed for cough, sore throat and vomiting. The incidence of postoperative complications were less and mild in nature.

DISCUSSION

The technique of insertion of LMA is absolutely different from that of inserting an endotracheal tube. It involves no use of laryngoscopy as vocal cords do not need to be visualized and LMA does not enter trachea but instead sits on the hypo pharynx when positioned correctly. So, considering these, the pressure responses to LMA insertion were expected to be different from that of laryngoscopy and tracheal intubation. The mechanical stimulation by pressure of laryngoscope on the soft tissue is the major factor in producing stress response to laryngoscopy and tracheal intubation.[6] Laryngoscopy produces the major contribution to the sympatho-adrenal response and tracheal intubation per se-contributed little additional effect.[7]

The LMA offers additional advantages during emergence from anesthesia; removal does not increase IOP and it is not accompanied by complication like coughing.[8],[9] Tracheal extubation, however, causes a marked increase in IOP, coughing and breath holding.[10]

A meta-analysis was performed on randomised prospective trials comparing the laryngeal mask airway (LMA) with other forms of airway management to determine if the LMA offered any advantages over the tracheal tube (TT) or facemask (FM). Advantages over the TT included: increased speed and ease of placement by inexperienced personnel; increased speed of placement by anesthetists; improved hemodynamic stability at induction and during emergence; minimal increase in intraocular pressure following insertion; reduced anesthetic requirements, lower frequency of coughing during emergence and lower incidence of sore throat in adults. [11]

Holden et al [12] were the first one to compare the IOP changes using LMA and endotracheal tube and their observations as well as those of Lamb et al. [7] revealed a significantly smaller increase in IOP using LMA both on placement and removal as compared to endotracheal intubation. Similar results were reported by Whitford et al [13] and Duman et al. [14]

In this study after LMA insertion IOP showed a decreasing trend from baseline and remained low at all stages of surgery. Moreover, LMA has extra advantage of less cardiovascular stimulation and less postoperative side effects.

The rise in IOP and cardiovascular changes is of great concern during intraocular surgery, penetrating eye injuries, surgery for glaucoma patient and in patients with compromised cardiovascular status. Therefore, Laryngeal mask airway is an acceptable alternative technique for ocular surgeries, offering advantages in terms of intraocular pressure and cardiovascular stability.

Conclusion:

We conclude that the use of LMA is advantageous where marked rise in intraocular pressure due to laryngoscopy and endotracheal intubation could be deleterious in patients with impending perforation of the eye, perforating injury, glaucoma etc. LMA may be recommended as an alternative to tracheal intubation for ocular surgeries. LMA also offers advantage in hypertensives, patients with coronary artery disease and patients with cerebro-vascular disease because of attenuated cardiovascular response.

REFERENCE

1) The laryngeal mask airway for intraocular surgery: effects on intraocular pressure and stress responses | Bja volume 69, issue 2 pp. 143-147 k. Lamb, f.r.c.anaes.m. f. M. James, ph.d., f.r.c.anaes.1 and K. Janicki, m.d., ph.d. | 2)Mostafa SM, Wiles JR, Dowd T, BatesR, Bricker S. Effects of nebulized lignocaine on the intraocular pressure responses to tracheal intubation. Br J Anaesth 1990; 64:515-517. | 3) Shribman AJ, Smith G, Achola KJ. Cardiovascular and catecholamine responses to laryngoscopy with and without intubation. Br J Anaesth 1987; 59:295-299. | 4) Drenger B, Peer J. Attenuation of ocular and systemic responses to tracheal intubation by intravenous lignocaine. Br J Ophthalmol 1987; 71:546-548. | 5) Mahajan RP, Grover VK, Sharma SL, Singh H. Intranasal nitroglycerin and intraocular pressure during general anesthesia. Anesth Analg 1988; 67:631-636. | 6) Prys-Roberts C, Greene LT, Meloche R, Foex P. Studies of anaesthesia in relation to hypertension: Haemodynamic consequences of induction and endotracheal intubation. Br J Anaesth 1971; 43:531-546. | 7)Lamb K, James MFM, Janicki PK. The laryngeal mask airway for intraocular surgery: Effects on for intraocular presure and stress responses. Br J Anaesth 1992; 69:143-147. | 8) Murphy DF, Eustace P, Unwin A, Mangner JB. Intravenous lignocaine pretreatment to prevent intraocular pressure rise following suxamethonium and tracheal intubation. Br J Ophthalmol 1986; 70:596-598. | 9) Kilickan L, Baykara N, Gurkan Y, Toker K. The effect on intraocular of endotracheal intubation or laryngeal mask airway use during TIVA without the use of muscle relaxants. Acta Anaesthesiol Scand 1999; 43:343-346. | 10) Madan R, Tamilselvan P, Shende D, Gupta V, Kaul HL. Intraocular pressure and haemodynamic changes after tracheal intubation and extubation: a comparative study in glaucomatous and nonglauco-matous children. Anaesthesia 2000; 55:367-390. | | 11) The advantages of the LMA over the tracheal tube or facemask: a meta-analysis | Canadian Journal of Anaesthesia; November 1995, Volume 42, Issue 11, pp 1017-1023 | J. Brimacombe | 12)Holden R Morsman CDG, Butler J, Clark GS, Hughes DS, Bacon PJ. Intra-ocular pressure changes using the laryngeal mask airway and tracheal tube. Anaesthesia 1991; 46:922-924. | | 13) Whitford AM, Hone SW, O'Hare B, Magner J, Eustace P. Intraocular pressure changes following laryngeal mask airway insertion- a comparative study. Anaesthesia 1997; 52:794-796. | 14) Duman A, Ogun CO, Okesli S. The effect on intraocular pressure of tacheal intubation or laryngeal mask airway insertion during sevoflurane anaesthesia in children witout the use of muscle relaxants. Paediatr Anaesth. 2001; 11:421-424. |