ORIGINAL RESEARCH PAPER

Volume-7 | Issue-11 | November-2018 | PRINT ISSN No 2277 - 8179

INTERNATIONAL JOURNAL OF SCIENTIFIC RESEARCH

A STUDY OF ULTRASOUND SCREENING OF THYROID GLAND:

Radiodiagnosis

Dr Sharanabasappa GM* Associate Professor, Department of Radiodiagnosis, Great Eastern Medical School and Hospital. *Corresponding Author

Dr Daruka K.M Professor, Department of Medicine, Great Eastern Medical School and Hospital.

ABSTRACT

Thyroid Gland is one of the most important endocrine gland in the human body as it regulates a number of metabolic functions. The disease of the thyroid gland is very common in our country. Though the disease is very common in our country it is often misdiagnosed or neglected thus resulting in a catastrophe for the patient. This study puts in an effort to understand the role of USG in screening the Thyroid Gland.

KEYWORDS

USG, Thyroid Gland, Benign, Malignant, Atypical.

INTRODUCTION:

Thyroid gland diseases is often found in our country. Thyroid Gland is one of the most important endocrine gland in the human body as it regulates a number of metabolic functions. The disease of the thyroid gland is very common in our country[1-3]. Though the disease is very common in our country it is often misdiagnosed or neglected thus resulting in a catastrophe for the patient. According to studies one in every ten adults in India is suffering from the thyroid disorder.[4,5] Hypothyroidism is more commonly encountered than the hyperthyroidism. If undetected and untreated for a long time then it results in a plethora of other metabolic disorders. Women are more affected than men and this may be due to the fact that it is the only endocrine organ which directly depends on the iodine from the external source for producing the hormones. [6,7] Early diagnosis and prompt treatment is needed so USG is such one screening option. Earlier radioactive materials were tagged and then injected to the body for diagnosing but now USG has slowly taken over and is widely used in the screening procedures of the thyroid diseases. This study puts in an effort to understand the role of USG in screening the Thyroid Gland.

AIMS AND OBJECTIVES:

To study the role of USG in screening the Thyroid Gland.

MATERIALS AND METHODS:

This study was done in Great Eastern Medical School and Hospital. The study was done from Jan 2018 to July 2018.

The study was done in the Department of Radio diagnosis and sixty patients were selected for the same.

Inclusion Criteria:

1. Patients with thyroid diseases
2. Age of the patient in between 30 to 60 years. This was done to eliminate the age related bias.

Exclusion Criteria:

1. Patients who were on medication for thyroid disease
2. Patients who was on chemotherapy for already known malignant diseases of the thyroid.

RESULTS:

Table 1: Mean age

Mean Age	Range	Standard Deviation
42.17 years	30-60 years	11.72 years

Table 2: Age Distribution:

Age	Thyroid Disease
30-40 years	11
40-50 years	43
50-60 years	06

Table 3: Thyroid Pathologies:

Disease	Freqquency
Hashimoto's Thyroiditis	06
Other Thyroiditis	09
MNG	17
Benign nodules	21
Atypical nodules	07

Graph 1: Thyroid Pathologies

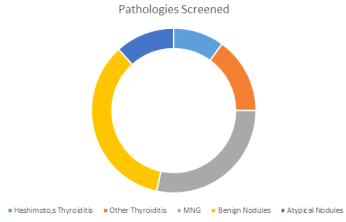

DISCUSSION:

Image 1: Thyroid Nodule

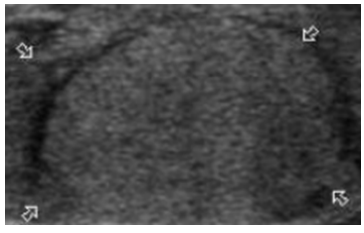

In this study the mean age of the poatients was found to 42.17 years, the range of the age of the selected patients was between 30-60 years. The standard deviation was found to 11.72 years.

Majority of the patients belonged to the age group of 40-50 years. Between 30-40 years 11 patients were found. Between 40-50 years 43 patients were found and between the age of 50-60 years 06 patients were successfully screened.

In our study we found that Hashimoto's thyroiditis were diagnosed in 06 patients, other thyroiditis were found in 09 cases. MNG were observed in 17 cases. Benign nodules were observed in 21 cases and atypical nodules were found in seven cases.

The thyroid is a very unique gland. Its blood supply is very rich and can be compared to that of kidneys. The gland directly depends on an external source for its function and it not only produces but also regulates the release of the produced hormones. So it is unique thrice. Thyroid diseases, if undetected and untreated for a long time then it results in a plethora of other metabolic disorders. Women are more affected than men and this may be due to the fact that it is the only endocrine organ which directly depends on the iodine from the external source for producing the hormones. [6,7] Early diagnosis and prompt treatment is needed so USG is such one screening option. Earlier radioactive materials were tagged and then injected to the body for diagnosing but now USG has slowly taken over and is widely used in the screening procedures of the thyroid diseases.

Our study is in agreement with the other studies conducted by

Chaudhary V et al [8] and Wong KT et al[9].

CONCLUSION:

USG is a non - invasive and non – radiational screening method. It is slowly becoming the gold standard to method of screening for thyroid pathologies.

REFERENCES:

1. Unnikrishnan AG, Kalra S, Sahay RK, et al. Prevalence of hypothyroidism in adults: an epidemiological study in eight cities of India. Indian J Endocrinol Metab 2013;17(4):647-652.
2. Sushmi Dey. 1 in 10 Indians suffer from thyroid disorder: study. The times of India. 2015 Jan25. disorderStudy/articleshow/46007453.cms
3. Unnikrishnan AG, Menon UV. Thyroid disorders in India: an epidemiological perspective. Indian J Endocrinol Metab 2011;15(Suppl2):78-81.
4. Nagarkar R, Roy S, Akheel M, et al. Incidence of thyroid disorders in India: an institutional retrospective analysis. International Journal of Dental and Medical Speciality 2015;2(2):19-23.
5. Nimmy NJ, Aneesh PM, Narmadha MP, et al. A survey on prevalence of thyroid disorders induced by demography and food habits in south Indian population. Indian Journal of Pharmacy Practice 2012;5(2):49-52.
6. Bagcchi S. Hypothyroidism in India: more to be done. Lancet Diabetes Endocrinol 2014;2(10):778.
7. Kangelaris GT, Kim TB, Orloff LA. Role of ultrasound in thyroid disorder. Otolaryngol Clin North Am 2010;43(6):1209-1227.
8. Chaudhary V, Bano S. Thyroid ultrasound. Indian Journal of Endocrinology and Metabolism 2013;17(2):219-227.
9. Wong KT, Yolanda YP, Lee, et al. Thyroid gland. In: Ahuja AT, ed. Diagnostic ultrasound: head and neck. 1st edn. Amirsys Publishing 2014:p. 52.