ORIGINAL RESEARCH PAPER VOLUME-6 | ISSUE-8 | AUGUST - 2017 | ISSN No 2277 - 8179 | IF : 4.176 | IC Value : 78.46

INTERNATIONAL JOURNAL OF SCIENTIFIC RESEARCH

A study of visual outcomes and complications following posterior chamber Iris claw lens implantation.

Ophthalmology

Dr. Ankita Patil MS Ophthalmology, FICO, SN-Fellow (Paediatric Ophthalmology and Strabismus)

Dr. Anamika H. Agrawal DNB (Ophthalmology),DO,DOMS,FICO. Associate Professor, TNMC & BYL Nair Hospital, Mumbai. Corresponding author

ABSTRACT

Aims : To evaluate visual outcomes & complications following posterior chamber iris claw lens implantation.
Material and Methods: 30 aphakic eyes without capsular support underwent retropupillary fixation of iris claw IOL at 6 weeks after primary surgery. Postoperative BCVA, IOP, anterior and posterior segment status were studied over 3 months.
Results: Early post operative anterior chamber inflammation was seen in (76.6%). 6.89% patients needed second surgical intervention in the form of haptic re-enclavation. BCVA at 3 months remained same or improved in 85.9% and deteriorated in 14.1% patients, due to ERM, PCO or moderate decentration of IOL. Factors that seem to affect the BCVA at 3 months were IOL decentration & irregularity in pupillary shape.
Conclusion: Iris-claw lens implantation behind iris plane combines the advantages of being posterior chamber lens with short operative time & relatively easy technique.

KEYWORDS:

Iris claw lens, visual outcomes, complications.

Introduction

Surgical options for optical correction of eyes with inadequate capsular support includes intra ocular lenses (IOL) in anterior chamber (AC), scleral fixated(SF) or iris claw in anterior or posterior chamber(PC). The technique of an angle-supported anterior chamber IOL is safe and fast but may result endothelial cell loss, bullous keratopathy, and secondary glaucoma in long term.[1] The advantage of scleral-fixated IOLs is that of being in a more physiological position, but the surgical procedure is difficult and takes long time with the risk of chronic inflammation, retinal detachment, vitreous incarceration, IOL decentration and pigment dispersion.[2] Also, the transscleral sutures can lead to conjunctival erosions, scleromalacia or endophthalmitis.[3] The advantages of posteriorly fixated iris claw lens (ICL) are physiological retropupillary position, easier surgical technique, lower incidence of complications like angle occlusion or corneal decompensation .[4, 5] However , raised intraocular pressure, hyphema, iritis, inflammation or cystoid macular edema may occur.[4]

Previous studies have shown that retropupillary iris fixed lenses have advantages of easy surgical technique and better safety profile as compared to scleral fixated IOL& angle supported IOL.[6]

There are very few studies on the visual outcomes and complications of posterior chamber iris claw lens in Indian population.

The purpose of this study was to look at the visual outcomes, potential complications following posterior chamber iris claw lens implantation and analyse reasons for poor visual outcome and the knowledge could be beneficial while considering it as an alternative for secondary IOL implantation.

Materials and Methods

This prospective, observational study was carried out at a tertiary care centre in Mumbai. The study was approved by the Institutional Ethics Committee. Written informed consent was obtained. 30 aphakic eyes with inadequate capsular support and best corrected visual acuity(BCVA) >/= 6/12 (Snellen's Chart) were included. They underwent posterior chamber iris claw lens implantation at 6 weeks after the primary surgery. Patients with corneal opacities involving visual axis, inadequate iris tissue for enclavation, retinal or optic nerve pathology were excluded. The preoperative data including demographics, etiology of aphakia , medications if any was collected. Patients were followed up for 3 months. One patient who lost to follow up(Attrition rate 3.3%) was not included in the final analysis at 3 months.

Surgery was done under peribulbar anesthesia . Main incision site was planned depending on the availability of iris tissue or presence of anterior synechiae, with 2 sideports on either side. Sutures if any were removed in the beginning. Anterior vitrectomy was done wherever vitreous was present in anterior chamber. Peripheral iridectomy was performed if not present. Iris claw lens was then introduced through scleral tunnel or corneal incision with the help of a duckbill forceps and enclaved on the peripheral iris using an enclaving rod. Wound was closed with 10-0 ethilon. Postoperatively treated with antibiotic & steroid eyedrops in tapering dose over 4 weeks .

Patients were followed up at day 1 & 7,1month& 3month. Evaluation consisted of BCVA, anterior segment and fundus examination & applanation tonometry. Slitlamp examination was done to assess corneal status, presence of hyphema, iritis, IOL centeration (well-centered/ decentered/ disenclaved) and shape of pupil (circular/ irregular).

TABLE 2: Grading of IOL Decentration

Centration	Distance between superior edge of lens and pupillary margin
Well centred	<1mm
Minimally decentred	1mm-2mm
Moderately decentred	>2mm

Indirect Ophthalmoscopy was done to evaluate retina status, vitreous inflammation and macular odema. Additional surgical intervention done if any were recorded. Findings were noted & analysed.

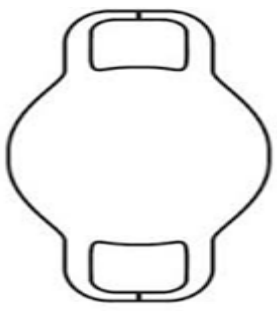

IrisClawLens

Results:

The average age of patients was 53.83 years with 73% males and 27% females. The most common etiology for aphakia was posterior capsular rent & complicated phacoemulsification surgery being the commonest primary surgery .

TABLE 3: ANTERIOR SEGMENT STATUS:

Anterior Segment Findings	Anterior Segment findings	Day1 (no)	Day7 (no)	1 month (no)	3 month (no)
Corneal Edema		20	2	0	0
Anterior Chamber	Cells 1+ to 3+	23	3	0	0
	Flare 1+ to 3+	23	3	0	0
	Membrane	2	0	0	0
	Vitreous strand	1	1	0	0
	Hyphema	1	0	0	0
Iol position	Well centred	17	17	17	17
	Minimally to Moderatel Decentred	12	12	12	12
	Disenclaved	1	1	0	0
Pupil shape	Circular	24	24	23	23
	Mid-dilated	4	4	4	4
	Irregular	2	2	2	2
Posterior Capsular Opacification		0	0	1	1

TABLE 4: BCVA at 3 Months

BCVA	Number
>/=6/12	25
6/12 to 6/36	4
</=6/60	0

In our study, 2 patients developed vitritis and 1 developed an epiretinal membrane. There was no evidence of cystoid macular edema in the postoperative period. Two patients required a second surgery in the form of IOL repositioning and 1 required YAG vitreolysis. One patient developed posterior capsular opacification.

DISCUSSION:

The surgical correction of aphakic eyes without capsular support is challenging. Glasses, contact lenses and various IOL are the options available for aphakic visual rehabilitation. During the last two decades several studies have focused on different secondary IOL implantation which include Scleral Fixated IOL, Anterior Chamber IOL & Iris Fixated IOL. [5,6]

The original iris-claw IOL was designed by Worst in 1972, and it was fixated in the iris mid stroma , where the iris is less vascularized.[7] Iris claw IOL has optic size 5mm, total length 8.5mm and haptics perforated for iris enclavation.

In our study, none of the patients had corneal decompensation. Endothelial loss may occur due to trauma during the surgical procedure or mechanical irritation from an IOL placed too close to the corneal endothelium. Therefore, implantation behind the iris plane may be safer.[5] Similarly, Gicquel et al directly compared patients with implantation of iris claw lens in front or behind the iris and found a significant lower endothelial cell loss in patients with posterior chamber implantation.[8]

We observed anterior uveitis (cells/flare/ pupillary membrane) in 25 patients on post-operative day1 which resolved with treatment by 1 month. Inflammation is probably due to iris tissue trauma by the haptics of the iris claw lens or handling during enclavation. There are case reports of development of anterior uveitis following iris claw lens implantation by Sridhar MS, et al.[9]

One patient had hyphema which resolved with conservative management within 7 days. Hyphema can occur due to trauma to iris during enclavation. Well centered IOL with round pupil is the desirable goal of ICL implantation. ICL can appear decentered and irregular pupil shape can occur if enclavation happens in upper or lower part of iris or not in the peripheral iris. Proper orientation of the central optical zone of ICL, the claws, the centre of pupil & peripheral iris has to be maintained by the surgeon while enclavation. Glare phenomenon may be experienced by such patients due to aberrations .We had 4+2 patients with irregular pupils. Similarly, Maurice Schallenberg et al also found irregular pupil.5 In our study, 2 eyes had disenclavation. This was probably because not enough iris tissue was enclaved. The IOLs were successfully re-enclaved however, they remained moderately decentered. Sreeni Edakhlon et al have also documented similar complication of disenclavation of haptics & then re-enclavation successfully done in their study.[10]

In our study,1 patient who had a traumatic subluxated cataract developed posterior capsular opacification(PCO) for which Yag capsulotomy was planned to be done at 6 months post operatively. He had a BCVA of 6/36. We had 1 patient with vitreous strand extending from the pupillary margin for which YAG vitreolysis was done at 4 weeks post operatively. This patient achieved BCVA of 6/12. Adequate anterior vitrectomy to remove all the vitreous strands from anterior chamber is required to prevent any future macular odema or corneal decompensation .

We had raised intraocular pressures(IOP) in 2 patients with significant anterior chamber reaction & vitritis , which responded to medical management. One patient developed raised IOP that was detected at 3 month follow up and had to be started on topical antiglaucoma medications. Similar complication was identified by Maurice Schallenberg et al.[5] In a study by Tmavec B1, et al pigment dispersion as a cause of glaucoma was identified after iris claw lens implantation.[11]

In our study, 2 patients developed vitritis who were treated with systemic steroids in tapering doses after ruling out any contra indications. One of them had a complete recovery and the other patient lost follow up after day 7. One patient developed an epiretinal membrane(ERM) confirmed on optical coherence tomography had BCVA of 6/36 at 3 month follow up& refused any further surgical intervention.

Macular odema may develop due to anterior segment inflammation with release of endogenous inflammatory mediators, vitreous traction or hypotony.[12] Lobo C. et al, observed clinically significant CME typically develop 4–12 weeks after surgery and generally resolve with treatment after 6 months.[13] There are case reports of development of CME by Dr. Sreeni Edakhlon et al.[10]

In our study, 25(86%)eyes had BCVA(>/= 6/12), 4 eyes had BCVA(6/18 - 6/36). Thus in 13.79% vision deteriorated .Out of these 4 patients, 1 patient had ERM, 2 had moderately decentered IOL and 1 had PCO. These findings are similar to other studies done by KS Lett et al, where iris claw lens insertion is beneficial for correction of aphakia ,and matches or exceeds preoperative BCVA in majority of cases.[14] Probable factors that seem to affect the BCVA at 3 months in our study were are IOL decentration, irregular pupil & ERM.

Conclusion:

Thus, retroiridial ICL implantation has the advantages of posterior chamber lens position, easy surgical technique and no significant corneal damage with good visual outcomes. However, long term follow up is required to know better on this.

References:

1. Sawada T, Kimura W, Kimura T, et al. Long-term follow-up of primary anterior chamber intraocular lens implantation. J Cataract Refract Surg. 1998;24(11):1515–1520.
2. Yilmaz A, Baser Z, Yurdakul NS, Maden A.Posterior chamber lens implantation techniques in posterior capsular rupture. Eur J Ophthalmol. 2004;14(1):7–1
3. Kwong YY, Yuen HK, Lam RF, Lee VY, Rao SK, Lam DS. Comparison of outcomes of primary sclera-fixated versus primary anterior chamber intraocular lens implantation in complicated cataract surgeries. Ophthalmology. 2007;114(1):80–85.
4. Nana Madhukar Jare, Ashwini Ganesh Kesari, Salil S Gadkari, and Madan D Deshpande. The posterior iris-claw lens outcome study: 6-month follow-up Indian J Ophthalmol. 2016 Dec; 64(12): 878–883.
5. Maurice Schallenberg, Dirk Dekowski, Angela Hahn,Thomas Laube,Klaus-Peter Steuhl, and Daniel Meller.Aphakia correction with retropupillary fixated iris-claw lens (Artisan) – long-term results Clinical Ophthalmology 2014;8:137–141
6. Dick HB, Augustin AJ. Lens implant selection with absence of capsular support. Curr Opin Ophthalmol 2001;12:47-57.
7. Worst GJ, Massaro RG, Ludwig HH. The introduction of an artificial lens into the eye using Binkhorst's technique. Ophthalmologica.1972 ; 164(5):387-91.
8. Gicquel JJ, Guigou S, Bejjani RA, Briat B, Ellies P, Dighiero P. Ultrasound biomicroscopy study of the Verisyse aphakic intraocular lens combined with penetrating keratoplasty in pseudophakic bullous keratopathy. J Cataract Refract Surg. 2007; 33:455–46.
9. Sridhar MS, Majji AB, Vaddavalli PK. Severe inflammation following iris fixated anterior chamber phakic intraocular lens for myopia. Eye 2006; 20: 1094–1095.

10. Dr. Sreeni Edakhlon, Dr. Abhijeet Khake, Dr. Gopal Pillai S, Posterior Iris Claw Lens for Surgical Correction of Aphakia — Long Term Results.39th annual conference of the kerela society of ophthalmic surgeons;2012 November 23-25, tiruvananthapuram, kerela,India
11. Trnavec B1, Cernák A, Vodrázková E et al. Pigment dispersion as a cause of glaucoma. Cesk Slov Oftalmol. 2005;61:66-9.
12. Andrzej Grzybowski,Bartosz L Sikorski, Francisco J Ascaso, and Valentín Huerva;Pseudophakic cystoid macular edema: update 2016;Clin Interv Aging. 2016; 11: 1221–1229.
13. Lobo C. Pseudophakic cystoid macular edema.Ophthalmologica 2012; 227:61–67
14. K S Lett1, and P R Chaudhuri. Visual outcomes following Artisan aphakia iris claw lens implantation .Eye.2011;25:73–76