ORIGINAL RESEARCH PAPER
VOLUME-6 | ISSUE-7 | JULY-2017 | ISSN No 2277 - 8179 | IF : 4.176 | IC Value : 78.46
INTERNATIONAL JOURNAL OF SCIENTIFIC RESEARCH

"A STUDY ON FINE NEEDLE ASPIRATION CYTOLOGY WITH POST OPERATIVE HISTOPATHOLOGY CORRELATION OF LUMP BREAST"

Surgery

Dr Sathyamoorthy Karuppiah Associate Professor , Department of Surgery, Government Dharmapuri Medical College and Hospital, Dharmapuri, Tamilnadu, india

Dr Thiruppathy Chakkaravarthy Associate Professor , Department of Surgery, Government Dharmapuri Medical College and Hospital, Dharmapuri, Tamilnadu, india

Dr Selvamuthukumaran Gunasekaran Senior Assistant Professor, Department of Surgery, Government Dharmapuri Medical College and Hospital, Dharmapuri, Tamilnadu, india

ABSTRACT

BACKGROUND: A method of definitive diagnosis of patients who present with palpable breast lump at the outpatient clinic is needed now a days. This method must be accurate, easy to perform and acceptable to the patient, can be carried out in a busy clinic setting and must not require too much preparation or expensive equipment. This study was conducted to compare the diagnostic accuracy of fine needle aspiration cytology(FNAC) in differentiating the benign and malignant lesions of palpable breast lump with histopathological correlation .

Methodology: One year prospective study from June 2015 to July 2016 involving 75 cases of women presenting in Surgery outpatient department, Government Dharmapuri Medical College Hospital with complaints of lump breast. Patients underwent FNAC of the palpable breast lump after thorough physical examination. The cytological report was described as benign, suspicious and malignant. Patient was informed about the report and proceeded with lumpectomy or mastectomy and histopathological confirmation. Later diagnostic accuracy of cytology reporting was compared with that of histopathology.

Results: FNAC had a diagnostic accuracy of 100% for patient with benign breast lesions and 93.55% for malignant breast lesions. The sensitivity of FNAC in diagnosing patients presenting with lump in breast was 100%.The specificity was 93.55%. The positive predictive value of 95.65%. The negative predictive value for FNAC was 100%.

K-coefficient-- 1.001068 which implies FNAC as a screening test and its results are comparable with the gold standard histopathological examination.

Conclusion: The FINE NEEDLE ASPIRATION CYTOLOGY (FNAC) is an essential and important test in diagnosing and managing patient presenting with lump breast. It is patient friendly, easy to perform, more reliable, repeatable and a simple test to diagnose patient presenting with lump breast. The accuracy of diagnosis increase if FNAC is performed and slides smeared and reported by an expert. High sensitivity and high positive predictive value shows that a patient with positive FNAC means a definite and accurate diagnosis of the concerned pathology when compared with the final histopathology report. The high specificity and a high negative predictive value of FNAC for malignancy showed the high accuracy of FNAC in the diagnosing malignancy. Thus, we conclude that FNAC is an important and essential preliminary test in diagnosing a patient presenting with breast lump and proceed with appropriate surgical management and it shows high degree of correlation with the final histopathological report. From our results, it can be advised that the patients in which FNAC is unequivocally diagnostic for cancer can be managed directly by mastectomy or any other definitive therapy

KEYWORDS:

FNAC, breast lump, carcinoma of breast, diagnosis of breast lump.

INTRODUCTION

Diseases of the breast constitute a significant proportion of surgical cases seen in both developed and developing countries, and frequently, the need arises to distinguish benign from malignant lesions prior to definitive treatment. The development in patient education and screening programs have permitted a marked increase in the number of tumours detected. [1] The most common sign and symptom of breast disease is a palpable mass; although breast diseases can also present as inflammatory lesion, nipple secretion or imaging abnormalities. [2] Most of the patients presenting with lump breast are benign lesions. [3] This produce anxiety in the patients and family members until they are reassured after thorough clinical examination and investigation. [4,5] It is difficult to differentiate between benign and malignant breast lesions clinically. Therefore a test as an outpatient basis is required to reach the definitive diagnosis before proceeding with the treatment. This should be an accurate , reproducible and easy to perform test. This test must be accepted by the patient, can be done in busy outpatient setup without much expenses. Fine needle aspiration cytology (FNAC) of lump breast is an important test to differentiate between benign and malignant lesion which cannot be dealt clinically .It reduces number of open biopsies in patientpresenting with breast lump .[7] FNAC is now used more frequently to diagnose any mass in the breast, which is clinically malignant. It is extremely beneficial in reaffirming the clinical impression of benign disease, which may not need subsequent biopsy. Furthermore, it allows more rapid diagnosis of a malignant condition in clinically non-suspicious masses. The ultimate benefit of aspiration cytology, however, rests in its demonstration of malignant disease, when other diagnostic modalities are inconclusive. [8] Fine needle aspiration cytology(FNAC) of lump breast is a substitute to excision biopsy in majority of instances and can differentiate and delineate the nature of the disease in most of the instances[9]

This study was done to see how a preliminary FNAC correlates well with the histopathological report of excised tissue after surgery .ultrasound guided Fine Needle Aspiration Cytology wound enhance the correct localisation of the lesion and more accurate diagnosis. Improve technique, with expertise false negative reports with respect to malignant lesion have been reduced and we can proceed with the definitive surgery.

AIMS AND OBJECTIVES

1. To assess diagnostic accuracy of FNAC in differentiating the benign and malignant lesions of palpable breast lump with Post operative Histopathological correlation.
2. To assess the incidence of various histopathological type in breast lump.
3. Age incidence of benign and malignant lesions.
4. To know the most common quadrant involved by benign and malignant lesions

MATERIAL AND METHODOLOGY

One year prospective study from June 2015 to July 2016 involving 75 cases of women presenting in surgery outpatient department with complaints of lump breast. FNAC followed by appropriate surgical management and histopathological examination of excised specimen.

In the surgical outpatient department patients presenting with palpable lump breast was examined. Detailed history was obtained and

a complete clinical examination was done and the proforma was filled . The patient was informed about the risk and benefits of the procedure and the definitive treatment following the cytological diagnosis and an informed written consent was obtained before doing FNAC of the breast lump.

1.Site of aspiration sterilised with alcohol
2.Lump is firmly held with one hand
3.Few patients may require local anaesthetic spray to reduce pain during aspiration.
4.Aspiration needle in introduced with a swift movement to reduce discomfort
5.Syringe is attached with the plunger closed properly so that air is excluded from its barrel.
6.Patient informed before puncturing the skin.
7.While introducing the needle into the skin there should be no air within the barrel.
8.Needle is properly positioned over the lump
9.Usually six passes of different direction and angle are made without withdrawing the needle from the lesion until there is a drop of fluid in the hub.
10.Release the negative pressure before withdrawing from the skin
11. Too much bloody aspirate is usually discarded and the procedure is repeated.
12. oily spread over the slide go for reaspiration
13.In case of deeper lesions long needle is being for aspiration.
14.If the aspirated material gets stuck in the hub, either wash with transport medium or use another syringe to suck the material from the hub.

The cytopathological report is given as benign , malignant or suspicious and patient is informed about the reported and proceeded with lumpectomy or mastectomy.

INCLUSION CRITERIA:

Age between 15 to 70 years
Patients presenting with complaints of lump in the breast

EXCLUSION CRITERIA:

1.Patient presenting with acute surgical conditions like mastitis and abscess
2.Patient presenting with ulcerated breast lump
3.Patient presenting with recurrent lump in the breast previously operated for malignancy
4.Patient not willing for surgery
5. Mass with skin infiltration

OBSERVATION AND RESULTS

AGE DISTRIBUTION:

AGE GROUP(YEARS)	FREQUENCY	PERCENTAGE%
15-24	16	21
25-34	13	18
35-44	21	28
45-54	15	20
55-64	6	8
>=65	4	5
TOTAL	75	100

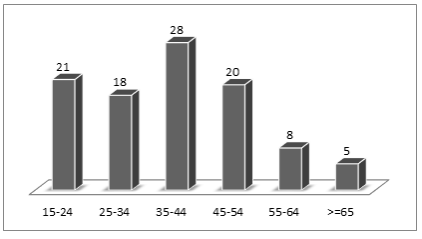

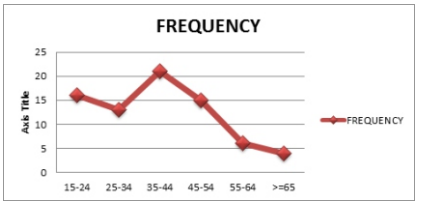

AGE DISTRIBUTION IN BENIGN AND MALIGNANT LUMP

AGE(YEARS)	BENIGN	MALIGNANT
15-24	16	0
25-34	13	0
35-44	11	10
45-54	4	11
55-64	0	6
>=65	0	4
TOTAL	44	31

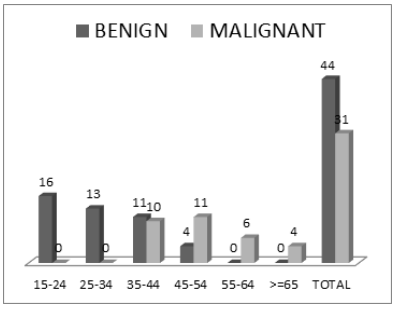

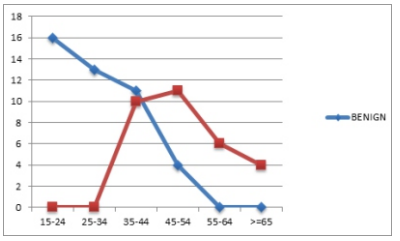

DISTRIBUTION OF PATIENTS ACCORDING TO AFFECTED SIDE OF BREAST

SIDE	BENIGN	MALINANT	TOTAL
RIGHT	21	18	39
LEFT	19	13	32
BOTH	4	0	4
TOTAL	44	31	75

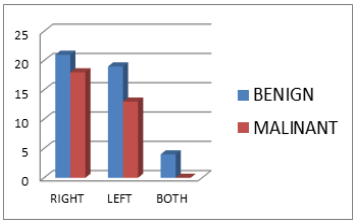

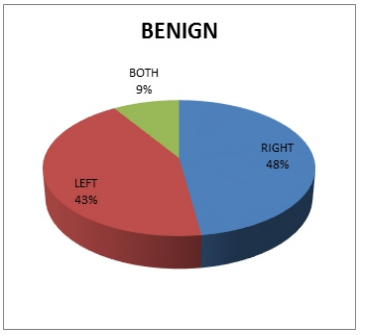

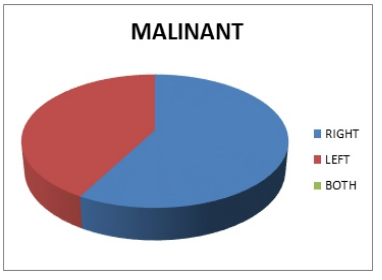

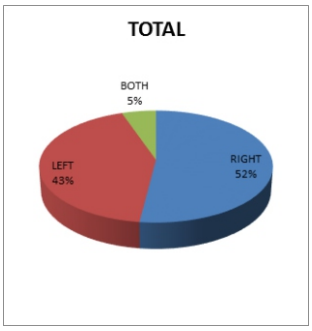

DISTRIBUTION OF PATIENTS ACCORDING TO THE QUADRANT OF BREAST

QUADRANT	BENIGN	MALIGNANT	TOTAL
U.O.Q	21	21	42
U.I.Q	10	3	13
CENTRAL	4	6	10
L.O.Q	5	1	6
L.I.Q	4	0	4
TOTAL	44	31	75

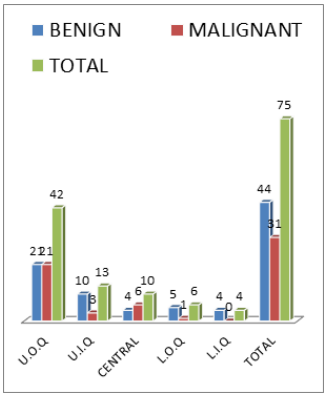

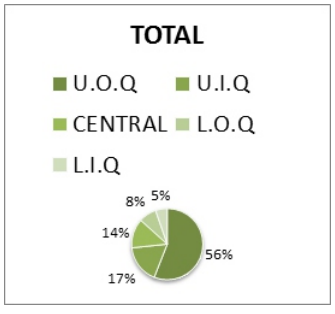

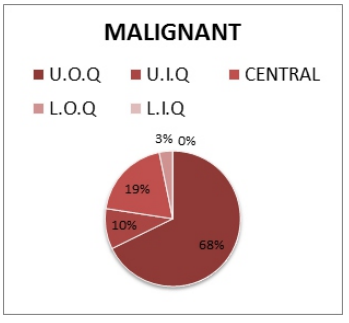

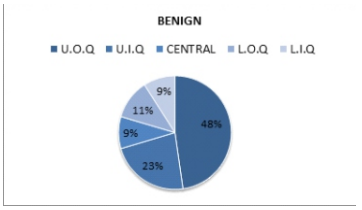

FNAC

BENIGN	MALINGNANT
46	29

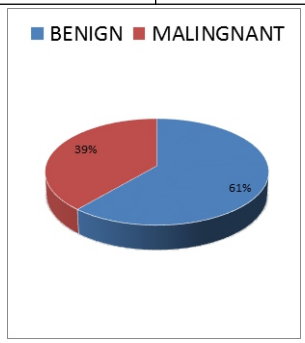

HPE

SIDE	BENIGN	MALIGNANT
TOTAL	44	31

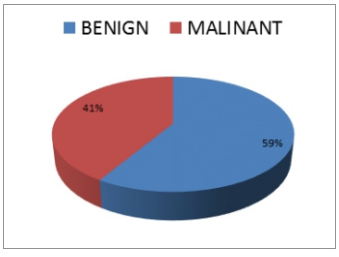

HISTOPATHOLOGICAL REPORTS OF BENIGN BREAST LESIONS

FIBROADENOMA	29
FIBROCYSTIC DISEASE	6
FIBROADENOSIS	4
PHYLLOIDES	3
LIPOMA	1
PAPILLOMA	1

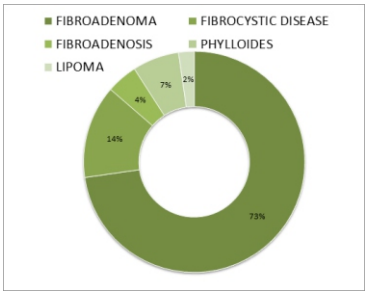

HISTOPATHOLOGICAL REPORTS OF MALIGNANT BREAST LESIONS

INTRA DUCTAL CARCINOMA	20
INTRA LOBULAR CARCINOMA	1
DUCTAL CARCINOMA INSITU	3
MIXED VARIANT	1
INTRA PAPILLARY CARCINOMA	3
MUCINOUS CARCINOMA	1
MALIGNANT PHYLLOIDES	2

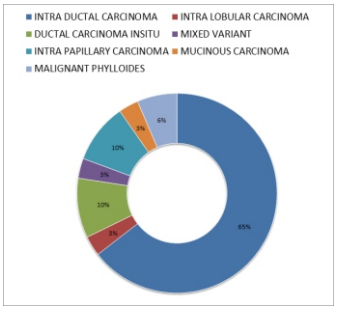

PREDICTIVE VALUE OF THE FINE NEEDLE CYTOLOGY OF PALPABLE BREAST LUMP

FINE NEEDLE ASPIRATION CYTOLOGY (FNAC)	HISTO PATHOLOGIC EXAMINATION (HPE)	
	BENIGN	MALIGNANT
BENIGN	44(a)	2(b)
MALIGNANT	0(c)	29(d)

TRUE POSITIVE
FALSE POSITVE
FALSE NEGATIVE
TRUE NEGATIVE

SENSITIVITY $\frac{a}{a+c} \times 100$

$$= \frac{44}{44+0} \times 100 = 100\%$$

SPECIFICITY $\frac{d}{b+d} \times 100$

$$= \frac{29}{29+2} \times 100 = 93.55\%$$

POSITIVE PREDICTIVE VALUE $\frac{a}{a+b} \times 100$

$$= \frac{44}{44+2} \times 100 = 95.65\%$$

NEGATIVE PREDICTIVE VALUE $\frac{d}{c+d} \times 100$

$$= \frac{29}{0+29} \times 100 = 100\%$$

SENSTIVITY	100%
SPECIFICTY	93.55%
PPV	95.65%
NPV	100%
OBSERVED AGREEMENT	0.973333
EXPECTED AGREEMENT	25.97067
K COEFFICIENT	1.001068

DISCUSSION

In the current study out of 75 cases the age incidence for the benign lesion ranged between 15-54 years and the age incidence for malignant lesion ranged between 35-70 years. Benign lesion was commonly found between 15-24 years and for malignant lesion was commonly seen 45-54 years.

In this study, the right breast was involved by the lump in 39 patients and 32 patients presented with lump in left breast. Both the breast was involved in 4 of the patients and all were benign lesions.

The upper outer quadrant of breast was the commonest quadrant to be involved by the lump followed by upper inner quadrant and central. 32 patients with lump in breast had Fibroadenoma which was the commonest cause of lump breast followed by 20 patients with ductal carcinoma and 6 with fibrocystic disease.

Fibroadenoma exhibits a smear patter composed of large sheets and cluster of epithelial cells in honeycomb patter with some degree of nuclear atypia. The key to the diagnosis of fibroadenoma is the detachment of oval naked nuclei from the cell clusters and sheets. Fibroadenoma is responsible for the false positive diagnosis. There was no cases with false positive reports. We had six cases of fibrocystic disease, which was reported as benign on fine needle aspiration cytology .

Two cases were Fibrocystic diseses in FNAC which came out as Ductal Carcinoma Insitu by histopathology which were treated accordingly with completion mastectomy.

One patient was reported to have lobular carcinoma which was a histopathological diagnosis. Cytology could only show the presence of malignant cells. It is difficult to differentiate to lobular from ductal carcinoma by Fine Needle Aspiration Cytology, but can often be suggested by the presence of low to moderate cell yield, individual epithelial cells, small chains, and small groups of cells, uniform population of small to medium sized cells with mild atypia and inconspicuous nucleoli and occasional signet ring cells.

Analysis of the cytological reports in various series confirms the very high diagnostic accuracy of FNAC. FNAC had a diagnostic accuracy of 100% for patient with benign breast lesions and 93.55% for malignant breast lesions.The sensitivity of FNAC in diagnosing patients presenting with lump in breast was 100%The specificity was 93.55%. The positive predictive value of 95.65%. The negative predictive value for FNAC was 100%. K-coefficient-- 1.001068 which implies FNAC as a screening test its results are comparable with the gold standard histopathological examination

SUMMARY OF THE STUDY

Lump breast was one of the common presenting problem in the surgery outpatient department of Tirunelveli medical college & hospital. In our study 75 patients with complaints of lump in the breast were evaluated and thorough physical examination was done. These patients were subjected to FNAC. These patients were categorised into three groups. They were informed about the cytopathological report and proceeded with appropriate management like lumpectomy or mastectomy and the final histopathological report was obtained from the excised specimen which was compared the cytological report.

The following conclusions were obtained from the above prospective study conducted in Dharmapuri medical college & hospital.

- the most common age group presenting with breast lump was 35-44 yrs
- benign breast lesion occurred between 15-54yrs of age
- malignant breast lesion occurred between 35-70 yrs of age
- benign breast lesion were common in age group of 15-24years
- the most common age group for malignant lesion was 45-54 years
- right breast was commonly involved and upper outer quadrant was commonly involved.
- Fibroadenoma was the common histopathological diagnosis of benign lesions
- Intra ductal carcinoma was the common histopathological diagnosis of malignant lesions
- diagnostic accuracy of FNAC in patients with malignant breast lesions was 93.55%
- diagnostic accuracy of FNAC in patient with benign breast lesion was 100%
- sensitivity in diagnosing malignancy --- 100%
- specificity in diagnosing malignancy ---93.55%
- Positive predictive value -95.65%
- Negative predictive value-100%
- K-coefficient-- 1.001068 which implies FNAC as a screening test its results are comparable with the gold standard histopathological exam

CONCLUSION

The FINE NEEDLE ASPIRATION CYTOLOGY (FNAC) is an essential and important test in diagnosing and managing patient presenting with lump breast. It is patient friendly, easy to perform, more reliable, repeatable and a simple test to diagnose patient presenting with lump breast. The accuracy of diagnosis increase if FNAC is performed and slides smeared and reported by an expert. High sensitivity and high positive predictive value shows that a patient with positive FNAC means a definite and accurate diagnosis of the concerned pathology when compared with the final histopathology report. The high specificity and a high negative predictive value of FNAC for malignancy showed the high accuracy of FNAC in the diagnosing malignancy. Thus, we conclude that FNAC is an important and essential preliminary test in diagnosing a patient presenting with breast lump and proceed with appropriate surgical management and it shows high degree of correlation with the final histopathological report.

References:

1. Mulford DK, Dawson AE. Atypia in fine needle aspiration cytology of nonpalpable and palpable mammographically detected breast lesions. Acta Cytol 1994; 38:9-17.
2. Klin TS and Neal HS. Role of needle aspiration biopsy in diagnosis of carcinoma of breast. Obstetrics and Gynecology 1975; 46:89-92.
3. Cochrane RA, Singhal H, Monypenny IJ, Sebster DJ, Lyons K, Mansel RE. Evaluation of general pr actitioner referrals to a specialist breast clinic according to the UK national guidelines. Euro J Surg Oncol 1997; June 23(3):198-201.
4. Hughes JE, Royle GT, Buchanan R, Taylor I. Depression and social stress among patients with benign breast disease. Br J Surg 1986;73: 997-999.
5. Ellman R, Angel N, Moss S, Chamberlain J, Maguire P. Psychiatric morbidity associated with screening for breast cancer. Br J Cancer 1989; 60:781-784.
6. A. Khemka, N. Chakrabarti, S. Shah, V. Patel. Palpable Breast Lumps; Fine-Needle Aspiration Cytology versus Histopathology: a Correlation of Diagnostic Accuracy. The Internet Journal of Surgery. 2009 Volume 18 Number 1.
7. Hindle WH, Payne PA, Pan EY. The use of fine needle aspiration in the evaluation of persistent palpable dominant breast masses. Am J Obstetrics Gynaecol 1993; 168 (6 Part 1): 1814—8.

8. Russ JE, Winchester DP, Scanlon EF, Christ MA. Cytologic findings of aspiration of tumours of the breast. Surg. Gynecol Obstetric 1978; 146: 407-411.
9. Khajuria R, Goswami KC, Singh K, Dubey VK. Pattern of Lymphadenopathy on Fine Needle Aspiration Cytology in Jammu. JK Science,2006; 8(3).
10. B D Chaurasia. Textbook of Human Anatomy : Regional and applied, dissection and clinical. Volume : 1 Upper limb and thorax. Fourth edition, page 39-43.
11. Homesh N A, Issa M A, El-Sofiani H A. The diagnostic accuracy of fine needle aspiration cytology versus core needle biopsy for palpable breast lump(s). Saudi Med J 2005; 26(1): 42-46.
12. Ashwin Hebbar. One year prospective study of fine needle aspiration cytology 0f clinically palpable br east lump with histopathology correlation in KLE Hospital and MRC District Hospital, Belgaum. A dissertation submitted to Rajiv Gandhi University Of Health Sciences, Karnataka 2005.
13. Litherland J C. Should fine needle aspiration cytology in breast assessment be abandoned?.ClinRadiol 2002; 57(2): 81-4.
14. Morris K T, Pommier R F, Morris A et al. Usefulness of the triple test score forpalpable breast masses. Arch Surg 2001;136(9):1008-13.
15. Green B, Dowley A, Turnbull L S et al. Impact of fine-needle aspiration cytology, ultrasonography and mammography on open biopsy rate in patients with benign breast disease. Br J Surg 1995; 82(11): 1509-11.
16. El Tahir A, Jibril J A, Squair J et al. The accuracy of "one-stop" diagnosis for 1 110 patients presenting to a symptomatic breast clinic. J R CollSurgEdinb 1999; 44(4): 226-30.
17. Lamb J, Anderson TJ, Dixon MJ, Levack P. Role of fi ne needle aspiration cytology in breast cancer screening. Journal of Clinical Pathology 1987, 40: 705–709.
18. Zajdela A, Chossein NA, Pillerton JP. The value of aspiration cytology in the diagnosis of breast cancer. 1975, 35: 499–506.
19. Azavedo E, Svane G, Auer G. Stereotactic fi ne needle biopsy in 2594 mammographically detected non-palpable lesions. Lancet 1989, 1: 1033–1035.
20. Edward Scalon. The case for and against two-step procedure for the surgical treatment of breast cancer. Cancer 1984;53(3): 677-680.
21. Leborgne R. Intraductal biopsy of certain pathologic processes of the breast Surgery 1946;19:47-49.
22. Zuber M. Naib. Exfoliative cytology, Boston, Little, Brown and Company 1996;18:477-495.
23. Smith BL. The breast. In: Ryan KJ, Kistner RW. Kistner's Gynecology and women's health. 7th ed. St. Louis: Mosby, 1999:197–202.
24. Morris KT, Vetto JT, Petty JK, Lum SS, Schmidt WA, Toth-Fejel S, et al. A new score for the evaluation of palpable breast masses in women under age 40. Am J Surg. 2002;184:346–7.
25. Sabiston, Text Book Of Surgery. New Delhi, Elsevier 2005, 2nd volume; 889-890.
26. Osuch JR, Reeves MJ, Pathak DR, Kinchelow T. BREAST-AID: clinical results from early development of a clinical decision rule for palpable solid breast masses. Ann Surg. 2003;238:728–37.
27. Crowe JP Jr, Rim A, Patrick R, Rybicki L, Grundfest S, Kim J, et al. A prospective review of the decline of excisional breast biopsy. Am J Surg. 2002;184:353–5.
28. Webb AJ. Early microscopy: history of fine needle aspiration (FNA) with particular reference to goitres. Cytopatology 2001; 12:1- 7.
29. Frable WJ. Needle aspiration biopsy: past, presnt and future. Hum Pathol 1989; 20:504-517.
30. Ansari NA, Derias NW. Fine needle aspiration cytology. J Clin Pathol 1997; 50:541-543.
31. Stewart FW. The diagnosis of tumour by aspir ation. Am J Pathol 1933; 9: 801-812.
32. Martin HE, Ellis EB. Biopsy by needle puncture and aspiration. Am Surg 1930; 92:169-181.
33. Editorial Opinion. The Uniform Approach To Breast Fine Needle Aspiration Biopsy. American Journal Of Surgery 1997; 173:371-383.
34. Non-operative diagnosis Subgroup of National Coordinating Group for Breast screening Pathology. Guidelines for Non-operative Diagnostic Procedur es andReporting Breast Cancer Screening. Sheffield, NHS Cancer screeningprogramme, 2001 (NHSBSP NO. 50).
35. Safneck JR, Kutryk E, Chrobak A, Harper R, Ravinsky E. Fixation techniques for fine needle aspiration biopsy smears prepared off site. Acta cytol.2001 May-jun; 45(3):
36. Silverberg Delvillis Frable. Principle in Practice And Surgical Pathology And Cytopathology, Singapore, Churchill Livingstone 1997, 3rd edition volume; 578-584.
37. Parson C A. Diagnosis of breast diseases, Singapore, Chur chill Livingstone 1990;1:201-203.
38. Michael Shabot. Aspiration Cytology is Superior to Tru-cut Needle Biopsy in Establishing the Diagnosis of Clinically Suspicious Breast Masses. Annals of Surger y 1982;196:122-126.
39. Orell SR. Pitfalls in fine needle aspiration cytology. Cytopatology 2003; 14:173-182.
40. Thunnissen FBJM, Kroese AH, Ambergen AW et al. Which cytological criteria are the most discriminative to distinguish carcinoma, lymphoma, and soft tissue sarcoma? A probabilistic approach. Diag Cytopathol 1997;17: 333-338.
41. Stewart FW. The diagnosis of tumour by aspiration. Am J Pathol 1933; 9: 801-812.
42. P Mendoza, Maribel Lacambra, Puay-Hoon Tan, and Gary M. Tse. Fine Needle Aspiration Cytology of the Breast: The Nonmalignant Categories. Pathology Research International. Volume 2011 (2011), Article ID 547580, 8 pages. Available at www.hindawi.com
43. Trott and Randal. Fine needle aspiration cytology. Lancet 1979;2:253.
44. S. Boerner and N. Sneige, "Specimen adequacy and false-negative diagnosis rate in fine-needle aspirates of palpable breast masses" Cancer 1998, vol. 84, no. 6, pp. 344–348.
45. Reshma Ariga et al. Fine needle aspiration of clinically suspicious palpable breastmass with histopathological correlation. American Journal of Surgery 2002;184:410-413.
46. Mark Rubin et al. Use of fine needle aspiration for solid breast lesion is accurate and cost effective. American journal of surgery 1997;174:694-698.
47. Hussain M T. Comparison of fine needle aspiration cytology with excision biopsy of breast lump. J Coll Physicians Surg Pak 2005;15(4): 211-214.
48. Aziz M et al. Comparison of FNAC and open biopsy in palpable breast lumps. Coll Physicians Surg Pak 2005;18(4): 316-323.
49. Michael Shabot. Aspiration Cytology is Superior to Tru-cut Needle Biopsy in Establishing the Diagnosis of Clinically Suspicious Breast Masses. Annals of Surger y 1982;196:122-126.
50. Dennison et al. A Prospective Study Of The Use Of Fine Needle Aspiration Cytology And Core Biopsy In The Diagnosis Of Breast Cancer. British Journal of Surgery 2003;9:491-497.
51. Abdulrahman Saleh Al-Mulhim et al. Accuracy of the triple test in the diagnosis of palpable breast masses in Saudi females. Ann Saudi Med 2003;23(3-4):158-161.
52. Alam A, Faruq TA, Bahar MM, Sultana MT. Age Related Incidence of Carcinoma of Breast in Female. Dinajpur Med Col J 2012 Jan; 5 (1):47-51.
53. Mohamed I Musa M I, Randa Z A Khair. Diagnosis of Breast Cancer: is there any protocol which is applicable worldwide? Sudan J.M.S. June2009;Volume 4 issue 2:157-162.
54. Sumaira Zareef, Muhammad Younis, Abbas Hayat. Fine Needle Aspiration Cytology of Breast Lumps. Journal of Rawalpindi Medical College (JRMC); 2011;15(1):35-37.
55. Ghimire B,Khan MI, Bibhusal T, Singh Y, Sayami P. Accuracy of Triple Test Score in The Diagnosis of Palpable Breast Lump. J Nepal Med Assoc 2008;47(172):189-92.
56. Tiwari M. Role of fine needle aspiration cytology in diagnosis of breast lumps. Kathmandu University Medical Journal (2007), Vol. 5, No. 2, Issue 18, 215-217.
57. O.N. Alema, A.M Gakwaya, D.Wamala. Comparision of Fine Needle Aspiration Cytology and Fine Needle Sampling without Aspiration in Diagnosis of Palpable Breast Lumps in Mulago Hospital. East and Central African Journal of Surgery. 2012 March/ April;17(1), 104-111.
58. Sudarat Nguansangiam, Somneuk Jesdapatarakul, Siriwan Tangjitgamol. Accuracy of Fine Needle Aspiration Cytology from Breast Masses in Thailand. Asian Pacific Journal of Cancer Prevention, Vol 10, 2009, 623-626.
59. Nggada HA, Tahir MB, Musa AB, Gali BM, Mayun AA, Pindiga UH, Yawe KD, Khalil MI. Correlation between histopathologic and fine needle aspiration cytology diagnosis of palpable breast lesions: a five-year review. . African journal of medicine and medical science. 2007 Dec;36(4):295-8.
60. Saleh FM, Ansari NP, Alam O. Comparison between fine needle aspiration cytology with histopathology to validate accurate diagnosis of palpable breast lump. Mymensingh MED J 2012, 21(3) : 450-5.
61. Ahmed HG, Ali AS, Almobarak AO. Utility of fine-needle aspiration as a diagnostic technique in breast lumps. Diagn Cytopathol. 2009 Dec;37(12):881-4.
62. Amrish Kambhoj, Investigating a lump for suspected cancer: fine needle aspiration cytology by AIIMS, 2007.
63. Walker SR. A randomized trail comparing a 21G needle with a 23G needle for fine needle aspiration of breast lumps. J R Coll Edinb 1998;4: 322-23.
64. Yeoh GPS, Chan KW. Fine-needle aspiration of breast masses: an analysis of 1533 cases in private practice. Hong Kong Medical Journal 1998; 4: 283-7.
65. Patel JJ, Gartell PC, Guyer APB, Herbert A, Taylor I. Use of ultrasound localization to improve results of fine needle aspiration cytology of breast masses. J R Soc Med 1988; 81: 10-12.
66. Padel AF, Coghill SB, Powis SJ. Evidence that sensitivity is increased and the inadequacy rate decreased when pathologists take aspirates for cytodiagnosis. Cytopathology 1993; 4: 161-5.
67. Cohen MB, Rodgers RP, Hates MS, Gonzales JM, Ljung BM, Beckstead JH. Influence of training and experience in fine-needle aspiration biopsy in breast. Receiver operating characteristic curve analysis. Arch Pathol Lab Med 1987; 111: 518-20.
68. Ljung BM, Drejet A, Chiampi N, Jeffrey J, Goodson WH 3rd, Chew K. Diagnostic accuracy of fine needle aspiration biopsy is determined by physician training in sampling technique. Cancer 2001; 93: 263-8.
69. Silverman JF, Elsheikh TM, Singh HK. The Role of Fine Needle Aspiration Cytology of the Breast in the Core Biopsy Era. Pathology Case Review 2007; 12(1): 44-48.
70. Kline T.S. Hand Book Of Fine Needle Aspiration Biopsy Cytology. C.V.Mosby Company 1981,Ch.6; 114-175.
71. Andrew Saxe et al. Role of sample ad equacy in fine needle aspiration biopsy of palpable breast lesions. American journal of surgery 2001;182:369-371.
72. Muzaffar Aziz, Naveed Ahmad, Jamil Zahid, Faizullah, Muzammil Aziz Comparison of FNAC and open biopsy in palpable breast lumps.Journal of the College of Physicians and Surgeons--Pakistan: JCPSP 11/2004; 14(11):654-6.
73. Somers RJ, Young KP, Kaplan MT, Bernhard UM, Rosenberg M, Somers D. Fine Needle Aspiration biopsy in management of solid breast tumors. Am J Surg 1985; 120: 673-7.
74. Choi YD, Choi YH, Lee JH, Nam JH, Juhng SW, Choi C. Acta Cytol. 2004; 48: 8016.
75. Medina Franco H, Abala Perez L. Fine needle aspiration biopsy - institutional experience. Zubiran 2005; 57: 394-8.
76. Westend PJ, Sever AR, Beekman-DeVolder HJ, Liem SJ. A comparison of aspiration cytology and core needle biopsy in evaluation of breast lesions. Cancer 2001; 93: 146-50.
77. Wu XP, Cia PQ, Zhang WZ, Tang J, Gu YK, Li L. Clinical evaluation of three methods of fine needle aspiration, large- core needle biopsy and frozen section biopsy with focus staining for non-palpable breast disease. Ai Zheng 2004: 23: 346-9.