Original Research Paper

VOLUME-6 | ISSUE-4 | APRIL - 2017 • ISSN No 2277 - 8179 | IF : 4.176 | IC Value : 78.46

A Study On Post Operative Dermatological Complications Of Foam Sclerotherapy For Varicose Veins

General Surgery

KEYWORDS: Foam sclerotherapy, Varicose veins.

Dr Rishikeshan Nair	Associate Professor, Department of General Surgery, Government Medical College, Trivandrum
Dr. Vidya Sharada Bhat K	Junior Resident, Department of General Surgery, Government Medical College, Trivandrum.
Dr Aravind S Ganapath	Junior Resident, Department of General Surgery, Government Medical College, Trivandrum

ABSTRACT

Varicose veins are a common manifestation of venous incompetence in the lower limb and appear as dilated, elongated or tortuous superficial veins. Varicose veins may lead to changes in the skin and the subcutaneous tissues, which are often clinically referred to as chronic venous disease. Foam sclerotherapy (FS) is a relatively novel minimally invasive technique that is used to treat varicose veins. Various dermatological complications associated with foam sclerotherapy are urticaria, hematoma, hyperpigmentation, telengiectatic matting, cutaneous necrosis and thrombophlebitis. We conducted logitudinal study in Department of General Surgery, Government Medical College Trivandrum for a period of 7 years from 2009 to 2016 on patients with varicose veins who underwent foam sclerotherapy at our centre. The most common dermatological complication was hyperpigmentation – in 15.1% patients followed by cutaneous necrosis in 7.3% patients and superficial thrombophlebitis in 6.6% patients.

Introduction

Chronic venous insufficiency (CVI) is characterized by various types of varices, some with associated skin abnormalities, which may in some cases even lead to venous ulcers[1]. Varicose veins represent a burden to a large proportion of the population, with incidences of up to 50%, rising with age[2].One in 10 of the affected persons reports varices related symptoms that require treatment. Symptoms include a feeling of heaviness and fatigue in the legs, spasms, restless legs and venous claudication. The treatment consists of elimination of the underlying venous hypertension, which is often caused by truncal varices.

The gold standard for the treatment of primary truncal varices has always been surgical intervention. A new therapeutic option for lower limb varices is foam sclerotherapy, in which the sclerosant is mixed with air to create a foam[3].

Compared to surgical interventions, the treatment is minimally invasive,patient-friendly and cost-effective[4]. It is a suitable treatment for lower limb varices, recurrent varices after surgery, reticular veins and perforating vein varices.

In recent years there has been an increased demand for minimally invasive and less expensive procedures in all fields of surgery. For varicose veins the available minimally invasive procedures are foam sclerotherapy (FS), endovenous laser ablation (EVLA) and radiofrequency ablation (RFA)[4]. FS is a variant of liquid sclerotherapy, in which the liquid–air mixture (foam) is injected into varicose veins under ultrasound guidance. Compared with liquid sclerotherapy, FS is more effective[5]. FS has a reported success rate of 75–85 per cent after 1 year and 69 per cent after 2 years of follow-up[6]. Advantages of this treatment are that it is less invasive, reduces healthcare costs, and is associated with a shorter recovery time than surgery, making FS an attractive alternative to surgery for the treatment of varicose veins.

The mechanisms of action of sclerosing detergents are the destruction of venous endothelial cells, leading to thrombus formation and, ultimately, the formation of fibrotic obstruction of the vein. The use of foaming solutions prolongs the contact time, amplifying the effect of the detergent by a factor of four.Today foam sclerotherapy is commonly used with sclerosing solutions, such as polidocanol and sodium tetradecyl sulphate (STDS). The most popular technique used today to prepare foam was developed by Tessari, who used a three-way stopcock connected with two syringes. The Double Syringe System (DSS) is also commonly used. In both techniques, liquid and air are pushed from one syringe into another to create air.

Although success rates after one FS session may be lower than after surgery, FS is an attractive alternative to surgery given that foam is four times more effective than liquid sclerosants, is less invasive than surgery, is performed in an outpatient setting and is associated with a shorter recovery time than surgery. Still FS is associated with various complications of which dermatological complications are the most common. The various dermatological complications are

1. Urticaria- Red, raised and itchy areas at the site of injection induced by sclerosant. It is not an allergic reaction. It is Self limiting and no treatment is necessary except for reassuring the patient that the itching and redness will be resolved in 4-24 hours.
2. Hematoma- usually intravascular. A liquefied thrombus trapped between the two ends of a treated vein if left in place, turns into hemosiderin.
3. Hyperpigmentation- Is the most common complcation with a reported incidence-10-30%. 90% of cases resolve within 1 year. Hemosiderin staining happens when blood leaves a ruptured blood vessel, the red blood cell dies and the hemoglobin from the red blood cell is released into the dermis.
4. Telangiectatic Matting- it is of unknown etiology. Maybe due to inflammation secondary to endothelial injury leading to angiogenesis. Presents as “blush type” area containing large numbers of tiny red blood vessels that are less than 0.2 mm in diameter.
5. Cutaneous Necrosis- Localized superficial tissue damage as a direct result of sclerotherapy. Dermal sloughing starts 24-72 hours after the ischemic event
6. Superficial Venous Thrombosis- A tender red, hard cord along length of superficial vein.

Aim of the study

The aim of the present longitudinal study was to study the post operative (2 weeks) dermatological complications which occurred amongst patient who underwent foam sclerotherapy in our institution from 2009 to 2016.

Methodology

It was a longitudanal study conducted in the Department of General Surgery, Govt. Medical College Thiruvananthapuram for a period of seven years from Jan 1st 2009 to 31st December 2016. Patients who underwent foam sclerotherapy for Varicose veins between 2009 to

2016 where followed up post operatively for a period of two weeks to study the various dermatological complications which may occur.

Results

All the patients who underwent foam sclerotherapy for varicose veins were followed up for the period of 2 weeks to study the various dermatological complications occurring.. In our study total of 1136 patients were followed up for 2 weeks over a time period of seven years. The common dermatological complications were hyperpigmentation – in 15.1%, cutaneous necrosis in 7.3% patients, superficial thrombophlebitis in 6.6% patients and hematoma in 2.8% patients. No patients were reported to have urticaria or telengiectatic matting.

TABLE 1- Distribution of dermatological complications

Complications	No: of patients	Percentage
Hyperpigmentation	172	15.1%
Cutaneous necrosis	83	7.3%
Thrombophlebitis	75	6.6%
Hematoma	32	2.8%
Urticaria	0	0
Telengiectatic Matting	0	0

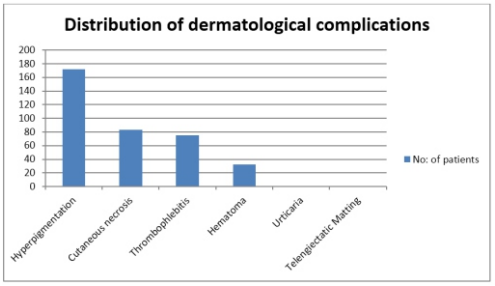

GRAPH 1- Graph showing distribution of dermatological complications

Discussion

In a review article published on complications of foam sclerotherapy by Cavezzi and Parsi in Phlebology the incidence of cutaneous complications after foam sclerotherapy were - superficial venous thrombosis (4.4%), tissue necrosis (variable frequency), telangiectatic matting (15–24%) and pigmentation (10–30%)6. Our incidence of complications are hence comparable to world literature except that telengiectatic matting was not reported in our study. This probably maybe due to darker complexion of skin in Indians which makes it difficult to appreciate telengiectatic matting.

Conclusion

Foam sclerotherapy is a novel minimally invasive and effective treatment modality for varicose veins. Various dermatological complications are reported but the incidence is low and seldom cause permanent or devastating effects. The incidence in Indian scenario is comparable to reported incidence in world literature.

References

1. Evans CJ, Fowkes FG, Hajivassiliou CA, et al. Epidemiology of varicose veins. A review. Int Angiol. 1994; 13: 263 70.
2. Beebe-Dimmer JL, Pfeifer JR, Engle JS, Schottenfeld D. The epidemiology of chronic venous insufficiency and varicose veins. Ann Epidemiol. 2005; 15: 175 84.
3. Evans CJ, Fowkes FG, Ruckley CV, Lee AJ. Prevalence of varicose veins and chronic venous insufficiency in men and women in the general population: Edinburgh Vein Study. J Epidemiol Community Health. 1999; 53: 149 53.
4. Fowkes FG, Evans CJ, Lee AJ. Prevalence and risk factors of chronic venous insufficiency. Angiology. 2001; 52 Suppl 1: S5 15.
5. Heit JA, Rooke TW, Silverstein MD, et al. Trends in the incidence of venous stasis syndrome and venous ulcer: a 25-year population-based study. J Vasc Surg. 2001; 33: 1022 7
6. Cavezzi etal. Complications of foam sclerotherapy. Phlebology 2012;27 suppl 1:46-51.