ORIGINAL RESEARCH PAPER
Volume-6 | Issue-10 | October-2017 | ISSN No 2277 - 8179 | IF : 4.176 | IC Value : 78.46
INTERNATIONAL JOURNAL OF SCIENTIFIC RESEARCH

A SUCCESSFUL MANAGEMENT OF MYOMA COMPLICATING PREGNANCY BY CONSERVATIVE TREATMENT: A CASE REPORT

Gynaecology

Lt Col Pranaya Gurmeet MS DNB Obstetrics & Gynaecology, AFMS

***Lt Col Barun Bhai Patel** MD, Community Medicine, AFMS *Corresponding Author

Col Sudhir Mansingh MS, DNB Obstetrics & Gynaecology, AFMS

ABSTRACT

Background: Myoma complicating pregnancy may lead to complication with unequal gravity. Its prevalence during pregnancy has been reported to be 1-4 %. It can cause spontaneous abortion, premature labour, malposition of fetus and many more complications. A case report of case presented in a Tertiary care hospital. Here we are presenting a case of myoma complicating pregnancy which was managed successfully without any adverse maternal and fetal outcome. A 35 years multigravida G2A1 with thirty weeks gestation approached us with history of pain abdomen. On examination, her vitals were normal; a 5*4cm tender lump was palpable on the fundal region of uterus. She was given Tocolytics, antibiotics and surfactant induction (for fetal lung maturity). She became asymptomatic after 12hrs of treatment and was discharged after 72hrs of observation. Management is essentially conservative and supportive with good outcome.

KEYWORDS

Fibroid, leiomyoma, pregnancy

I. Introduction

Uterine leiomyomatas a benign smooth muscle tumors of the uterus, is the most common estrogen dependent benign tumor of the uterus occurring in the reproductive age. Asymptomatic myomas can be present in 50% of cases[1]. Growth of leiomyoma is dependent on estrogen production, growth factors and clonal expansion [2]. They are present in approximately 20-50 % of women of reproductive age. But the actual prevalence of uterine fibroid tumors is found to be as high as 80 % [3]. Presence of myoma during pregnancy, is potentially a serious problem and of frequent clinical concern since fibroids are commonly detected in women of reproduction age, and can cause adverse pregnancy outcome [4]. Uterine leiomyoma are usually asymptomatic but may be occasionally complicated by red degeneration and an increased frequency of spontaneous abortion, preterm labor, premature rupture of fetal membranes, antepartum hemorrhage, malpresentations, obstructed labour, cesarean section and postpartum hemorrhage [4-5]. So careful monitoring of the patient is needed during antenatal, intranatal and postnatal period. Here we are reporting a case of myoma complicating pregnancy without any adverse maternal and fetal outcome.

II. Case report:

Case: A 35 years multigravida G2A1, with 30 weeks gestation, with regular antenatal checkups with frequent ultrasound examinations of gravid uterus (all scans were normal) She had no antenatal complications. Her first pregnancy was a suspected heterotopic pregnancy, for which she underwent laparotomy with suction and evacuation. She reported with history of pain abdomen in present pregnancy. On examination, her vitals were normal. Abdomen was over distended, uterus was corresponding to 30week size, breech presentation and normal fetal heart rate. A tender lump 5 x 4cm was palpable on the fundal region of uterus. Uterus was irritable, Cervix was uneffaced, OS was closed and presenting part was breech and was high up. Pelvis was gyneacoid. Clinically the lump was suspected to be a fibroid uterus, keeping fundal perforation/ dehiscence of uterus as differential diagnosis. Ultra sound examination of the Uterus revealed single live fetus in breech presentation of 30 weeks gestation of estimated fetal weight 1.5 kg with fibroid of 5.77 X 4 cm on the fundus (figure 1&2).



Figure: 1 Fetus with fibroid



Figure 2: Fibroid

Management: Patient was managed conservatively on analgesics, tocolysis, and prophylactic antibiotics. Surfactant induction was given for fetal lung maturity. Patient was asymptomatic after 12hrs of admission. She was observed for 72hrs and was discharged with instructions for follow up in OPD. She completed her full term uneventfully. On completion of term she delivered a full term baby by caesarian section (fig 3 &4).

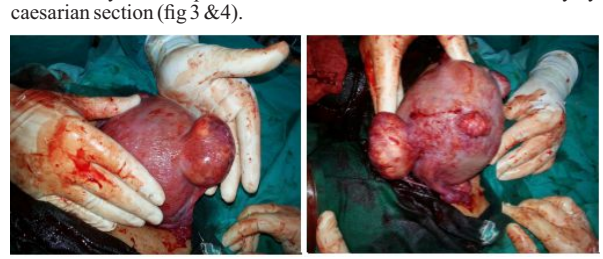

Fig 3 &4: Fetus with Fibroid

III. Discussion

Uterine fibroids have long been implicated as a cause of adverse pregnancy events though in some cases it does not affect the outcome of pregnancy, but in many cases it leads to problems like abortion, preterm labor, other complications being premature rupture of membranes, placental abruption, uterine dysfunction and obstructed labor, mal presentations and mal positions, retained placenta, post-partum hemorrhage, pain, degeneration, IUGR [6-7]. The two factors most important on determining morbidity in pregnancy are leiomyoma size and location. The proximity of myoma to the placental implantation site is also a factor. Specifically abortion, preterm labour, placental abruption and post partum hemorrhage all are increased if the placenta is adjacent or implanted over a leiomyoma. Generally fibroids are associated with multiparty and infertility. The relative risk of fibroids decreases with each additional term pregnancy, the risk is reduced to 1/5th, with five term pregnancies compared with nulliparous women [8]. There is a fourfold increase of placental

abruption and breech presentation, two fold increases of first trimester bleeding and dysfunctional labour and sixfold increase of caesarean delivery [9]. In the present case also the patient presented with breech and was delivered by caesarean section which corresponds with the various studies. The rate of caesarean section was 38-72.7 % and the indications for caesarean section being failure to progress, fetal distress and malpresentation, (Breech-19.04%, Neglected shoulder presentation 4.76%, cordprolapse 14.28%) [8-9]. If caesarean section is indicated myomas should be generally left alone unless they cause recalcitrant bleeding. It is unwise to attempt myomectomy because of associated vascularity of the procedure. Caesarean hysterectomy may be considered if there are multiple fibroids and the women has completed her family but is associated with increased morbidity and reserved for emergency situations only. Incidence of postpartum hemorrhage is high and is due to decrease of force of uterine contractions because of fibroids in myometrium or because of disruption of the coordinated spread of contractile wave, there by leading to dysfunctional labor. Risk of postpartum sepsis may be increased because of extensive necrotic degeneration of fibroid attributed to hormonal changes of pregnancy and the puerperium. Fibroids are associated with increase in perinatal mortality when placenta is implanted over the fibroid or close to the fibroid. There is increased incidence of spontaneous pregnancy loss, particularly with multiple fibroids[10].

IV. Conclusion

Although fibroids are associated with increased complications during pregnancy, overall good maternal and neonatal outcomes are expected. Prophylactic intervention is seldom warranted and that surveillance during pregnancy with a referral to obstetrician is sufficient for most women with myomas. As fibroid during pregnancy are associated with increase caesarian section rate & post partum hemorrhage, the obstetrician dealing with such patients must be experienced to deal with any untoward events during management. Degeneration in a myoma may present with localized pain and tenderness. The diagnosis will depend on recognizing the presence of myoma; it is easier when they are already documented. Treatment is essentially conservative with myoma.

References:

1. C ramer SF, Patel A. The frequency of uterine leiomyomas. Am J Clin Pathol 1990;94:435-8.
2. Levy G, Hill MJ, Beall S, Zarek SM, Segars JH, Catherino WH. Leiomyoma: Genetics, assisted reproduction, pregnancy and therapeutic advances. J Assist Reprod Genet 2012;29:703-12.
3. Umezurike c. Feyi-waboso P. successful myomectomy during pregnancy: a case report. Reprod health 2005,2(1)6. Published online 2005 August 11.dei 10.1186/1742-4755-2-6.
4. 23rd Edition Williams Obstetrics Mac Graw Hill 2010;40:903-904
5. James PR , Helen H K .Barry SM. The clinical significance of leiomyomas in pregnancy. Am J Obstet Gynecol 1989;160:1212-16
6. Quyang DW: Economy KE Norwitz ER obstetric complications of fibroids. Obstet Gynaecol clin North Am 2006:33(1):153-69
7. Mason Tc Red Degeneration of a leiomyomata masquerading as retained products of conception. J Natl Me Assoc 2002; 94(2) : 124-6.
8. Kokab H. Elahi N, Shaheen T. Pregnancy associated with fibroids .Complications and pregnancy outcome. J col physician's surg pak 2002; 12:731-4
9. Coronado GD, Marshall LM, Schwartz SM. Complications in pregnancy, labor and delivery with uterine leiomymas. A population based study. Obstet Gynecol 2000;95:764-9.
10. Vollenhovea BJ. Lawrence As. Healy DL. Uterine fibroids. A clinical review. Br J obstet Gynaecol 1990;97:285-98