VOLUME-6 | ISSUE-1 | JANUARY-2017 • ISSN No 2277 - 8179 | IF : 3.508 | IC Value : 78.46

Abdominal Tuberculosis Presents as Hernia Sac Tubercles and Immune Reconstitution Inflammatory Syndrome in a HAART Patient - A Case Report and Review of Literature

General Surgery

KEYWORDS: Hernia Sac, Tubercles, HIV, TB, IRIS

Jayakumar P	Department of General Surgery, Government Rajaji Hospital and Madurai Medical College, Madurai-20.
Maruthupandian D	Department of General Surgery, Government Rajaji Hospital and Madurai Medical College, Madurai-20.
Latha D	Department of General Surgery, Government Rajaji Hospital and Madurai Medical College, Madurai-20.
Saravanan C1.	Department of General Surgery, Government Rajaji Hospital and Madurai Medical College, Madurai-20.

ABSTRACT

A rare case of abdominal tuberculosis (TB) presents as Hernial Sac Tubercles with Immune Reconstitution Inflammatory Syndrome (IRIS) in a HIV patient on Highly Active Antiretroviral Therapy (HAART). It is an accidental finding while opening an indirect inguinal sac during Hernioplasty, excision of the excess sac done . This is the first case report to our Knowledge as HIV-TB IRIS primary presentation as hernia sac tubercles.

Introduction:-

Tuberculosis (TB) is common in developing countries like India, extra pulmonary manifestation like abdominal TB also one of the common manifestations. Immune compromised patients like Human Immunodeficiency Virus (HIV) infected patients are harboring higher chance of TB infection particularly extra pulmonary ones like abdominal TB. Abdominal TB most frequently associated with Pulmonary Tuberculosis, which is not a mandatory one particularly in HIV patients [1-3].

Immune Reconstitution Inflammatory Syndrome (IRIS) associated with TB is called TB-IRIS, which is a paradoxical reaction following Anti-Retroviral Therapy (ART) with worsening of symptoms and signs in a known treated TB patient or newly detected TB patients along with immune reconstitution. It is mainly due to CD4+ T-cell response against Mycobacterium Tuberculosis surface antigens and high pathogen load. Disseminated and Etrapulmonary TB patients are at high chance of developing TB-IRIS [1,4,5].

Abdominal tuberculosis presenting primarily as Inguinal Hernia sac tubercles is reported rarely, but no reports were available in HIV patients as per our knowledge and in the electronic search we made.

Here we reported a case of Hernia sac tubercles in a HIV patient associated with silent IRIS.

Case Report:-

A 47 year Old male Patient Living with HIV and AIDS (PLHA) presented to our surgical out patient department with complete Right Inguinal Hernia for 13 months who was on Highly Active Anti-Retroviral Therapy (HAART) Zidovudine, Lamivudine and Nevirapine (ZLN) for 10 months without any symptom suggestive of TB. The hernia is completely reducible on lying down. We planned the right side Hernioplasty for this patient. On preoperative evaluation patient had no comorbid illness except HIV and there is no symptoms or signs suggested tuberculosis for him except Ultrasonogram(USG) of abdomen and pelvis reveals multiple small hypo-echoic lesions in the spleen. His Hemoglobin is 11.6 gms%, ESR 18 mm/ hr and base line CD4 on starting ART is 221 cells, six months later is 306cells.

He was evaluated for pulmonary tuberculosis by history, sputum Acid Fast bacilli (AFB) and Sputum Gene Xpert which all turned to be negative. Thoracic physician opinion obtained, they started the patient on Anti-Tuberculosis Therapy (ATT) CAT-1 empirically due to high burden of TB in HIV patients in developing countries like India.

Patient was posted for hernioplasty two weeks after starting the ATT. During the surgery indirect inguinal sac was identified which is 10X6cms and having a granular feel, which reduced with gurgling sound on palpation, which we suspected as bowel and omentum as content of the hernia sac. On opening the sac we surprised to see multiple studded tubercles over the hernia sac[Figure.1], small bowel and mesentery[Figure.2].

Excess hernia sac excised for biopsy and right hernioplasty done using prolene mesh. Postoperative Histopathological Examination(HPE) of the hernia sac confirms the granulomas, epitheloid cells, Langerhan cells and healed fibrosis[Figure.3] ,which all confirmed the tuberculosis etiology. Postoperative period was uneventful except a minimal scrotal edema, which resolved spontaneously over two weeks of follow up.

Discussion:-

In this case no symptoms or signs suggested TB, except the USG finding. Abdominal TB in this patient presents as hernia sac tubercles over peritoneum and small bowel after immune recovery following ART. CD4 cell count raised is 85 cells (>25 cells) which is one of the criteria for IRIS. Immune recovery may heal the TB in this patient, but there is high chance for developing fibrosis, stricture and obstruction of the bowel loops [1,6]. This case may be silent TB-IRIS or a newly infectected TB, because there is no symptoms of inflammatory reaction but only with the intraoperative sign of tubercles in the hernia sac and USG evidence of multiple small hypo-echoic lesion in the spleen.

Hernia sac biopsy proved the TB disease in this patient, even though the patient was started on empirical ATT. Hernia sac biopsy is not routinely useful, except suspicion of pathology like thickened sac or tubercles in sac [6].

IRIS usually common in patients started on ART with low CD4 count, but it is common that TB-IRIS develops in patients with higher CD4 count also [7].

Hernioplasty (Mesh Repair) is not recommended in
Infective etiologies. Hernioplasty was done in this case, because the patient was started on empirical ATT two weeks before surgery and the prolene mesh was placed in front of the peritoneum and not intra-abdominally where the TB disease is active [8].

Conclusion:-

Even though hernia sac biopsy is not routinely recommended in inguinal hernias, it may be useful for early detection of TB in HIV and immune compromised patients.

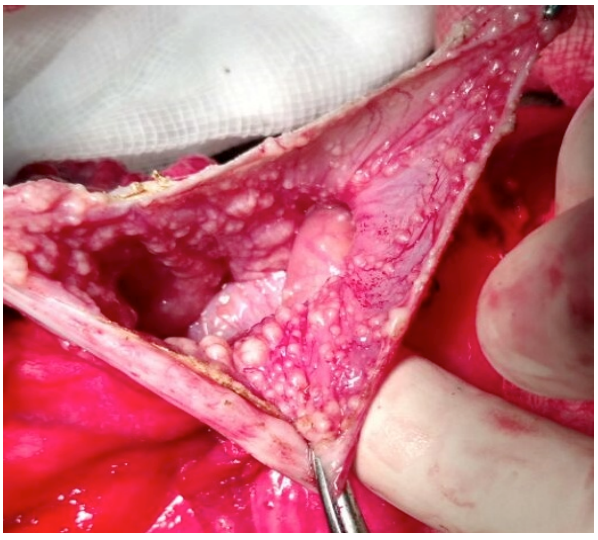

Figure 1. Multiple tubercles seen inside the hernia sac

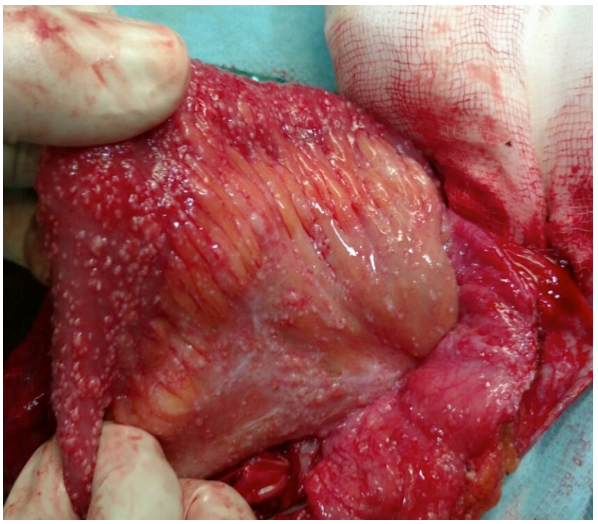

Figure 2. Multiple tubercles over small bowel and mesentery

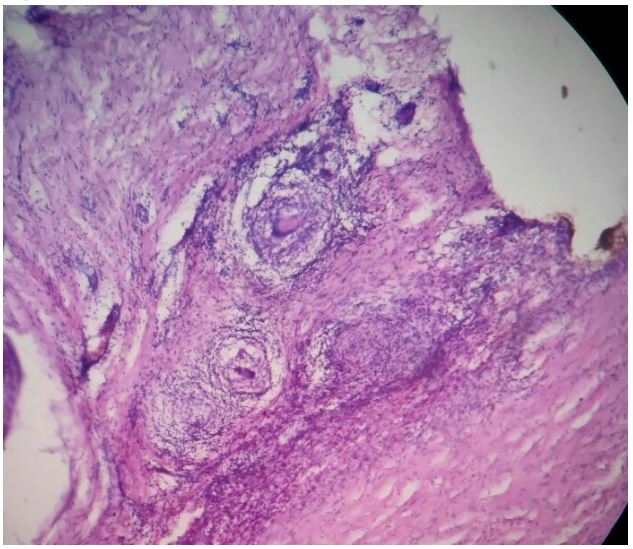

Figure 3. HPE of hernia sac

References:-

1) Surendra K. Sharma., Manish Soneja., HIV & immune reconstitution inflammatory syndrome (IRIS)., Indian J Med Res 134, December 2011, pp 866-877.
2) Priya Kandola and Laxman S. Meena., Extra pulmonary tuberculosis: Overview, manifestations, diagnostic and treatment techniques., Adv. Mater. Rev. 2014, 1(1), 13-19.
3) Cengiz Bolukbas, Fusun F Bolukbas, Tulin Kendir, Remzi A Dalay, Nihat Akbayir, Mehmet H Sokmen, Ali T Ince, Mithat Guran, Erkan Ceylan., Guray Kilic., and Oya Ovunc., Clinical presentation of abdominal tuberculosis in HIV seronegative adults., BMC Gastroenterology 2005, 5:21.
4) Rachel P. J. Lai , Graeme Meintjes, Robert J. Wilkinson., HIV-1 tuberculosis-associated immune reconstitution inflammatory syndrome., Semin Immunopathol (2016) 38:185–198.
5) Vignesh R1, Kumarasamy N, Lim A, Solomon S, Murugavel KG, Balakrishnan P, Solomon SS, Mayer KH, Swathirajan CR, Chandrasekaran E, Pradeep A, Poongulali S, Benson CA, French MA. TB-IRIS after initiation of antiretroviral therapy is associated with expansion of preexistent Th1 responses against Mycobacterium tuberculosis antigens. J Acquir Immune Defic Syndr. 2013 Nov 1;64(3):241-8.
6) Neeraj K. Dewanda, Manojit Midya, Naresh N. Rai., Hernial Sac Tuberculosis- An Unusual Presentation of Gastrointestinal Tuberculosis: Case Report with Review of Literature. International Journal of Scientific and Research Publications, Volume 4, Issue 2, February 2014.
7) Kumarasamy N1, Venkatesh KK, Vignesh R, Devaleenal B, Poongulali S, Yepthomi T, Flanigan TP, Benson C, Mayer KH. Clinical outcomes among HIV/tuberculosis-coinfected patients developing immune reconstitution inflammatory syndrome after HAART initiation in South India. J Int Assoc Provid AIDS Care. 2013 Jan-Feb;12(1):28-31.
8) Zhou C. Inguinal Hernia with Tuberculous Peritonitis: A Case Report and Literature Review. J J Surg. 2015, 2(3): 025.