ORIGINAL RESEARCH PAPER
VOLUME-6 | ISSUE-7 | JULY-2017 | ISSN No 2277 - 8179 | IF : 4.176 | IC Value : 78.46
INTERNATIONAL JOURNAL OF SCIENTIFIC RESEARCH

ABERRANT ORGANISATION OF RENO-TESTICULAR VASCULATURE: ANATOMICO-CLINICAL INSIGHT

Anatomy

Deepika — Senior Resident, Department of Anatomy,Maulana Azad Medical College, New Delhi, India - Corresponding author

Preeti Goswami — Associate Professor, Department of Anatomy,Maulana Azad Medical College, New Delhi, India

Sabita Mishra — Director, Professor and Head of Department, Department of Anatomy,Maulana Azad Medical College, New Delhi, India

ABSTRACT

We hereby report a case with multiple reno-testicular vascular anomalies. This work was performed in Maulana Azad Medical College, New Delhi, India. A 60 years old embalmed Indian male cadaver hosted double renal arteries bilaterally, double renal veins on the right and bilaterally testicular vein was replaced by anastomotic plexus of veins which received a tributary from perinephric fat. On the right, a vein from this venous plexus draining testis terminated into right renal vein and other drained into inferior vena cava. On the left side multiple renal veins emerged from the renal hilum, they joined to form a single renal vein. The pre-operative knowledge of anomalous renal vasculature is the key for the surgeon to avoid intra-operative vascular accidents and associated post-operative complications.

KEYWORDS:

Renal vein, renal artery, testicular vein, variations.

Introduction

The five renal vascular segments have been described in the standard textbooks: apical, superior/anterior, middle/anterior, inferior, posterior. The apical segment includes the anteromedial part of the superior pole of kidney. The superior/anterior segment occupies remaining part of the superior pole along with the central part of anterosuperior region. The inferior segment implies, the inferior pole of kidney. The middle/anterior segment occupies the region between anterior and inferior segment. The posterior segment includes the posterior region between the apical and inferior segments. Each segment is supplied by end arteries. The contrary to the arteries, renal veins have no segmental distribution.

The renal arteries are the lateral branches of abdominal aorta. In approximately 70% of the cases each kidney is supplied by single renal artery. Near the hilum it divides into two divisions- Anterior and Posterior. These divisions divide into segmental arteries which supplies renal vascular segments. Accessory renal artery found in about 30% population may supply inferior pole of kidney. It may cross the ureter anteriorly leading to ureteral compression and hence hydronephrosis. Accessory renal artery may be the branch of coeliac trunk, superior mesenteric artery or common iliac artery.

In the renal hilum renal vein is in anterior relation with the renal artery. Bilaterally, renal veins drain directly into inferior vena cava. The left renal vein may be double, passing either anterior or posterior to the aorta. Accessory vein is rare on the right side.

The testicular veins emerge from the posterior border of the testis, form pampiniform plexus which is an anastomotic plexus of veins, pass through the spermatic cord, coalesce to form a single testicular vein. The right testicular vein drains into inferior vena cava at an acute angle whereas on left it drains perpendicularly into left renal vein (Standring S.).

Case Report

This is a retrospective study undergone during routine medical undergraduate dissection teaching sessions. We noticed a rare case harbouring bilaterally multiple morphological variations in renal arteries, renal veins and testicular veins. The hilum of the right kidney was deeply indented. It was supplied by double renal arteries (superior and inferior) arising from abdominal aorta (figure 1). The superior renal artery before entering into the hilum divided into four branches which entered the renal hilum such that two of them were in dorsal relation, one superior and one inferior relation to the renal vein. The inferior renal artery was a supernumerary artery which entered the renal parenchyma aberrantly through the medial border of inferior pole of kidney (figure 2b).

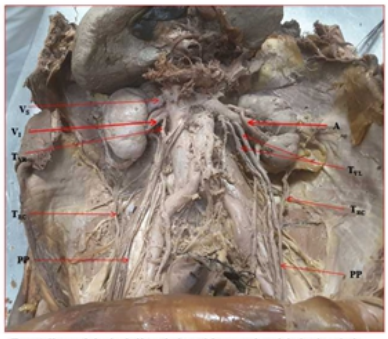

Figure: 1: Photograph showing double renal veins on right, venous plexus drained testis received a tributary from perinephric fat bilaterally, a testicular vein on right terminated into renal vein other drained into inferior vena cava, on the left veins from testis drained into inferior vena cava
V_S: Superior renal vein — A: Aberrant renal artery
V_I: Inferior renal vein — T_{VS}: Veins from testis draining separately into renal vein
T_{VR}: A tributary draining into inferior renal vein — PP: Venous plexus draining testis
T_{RC}: A tributary draining renal capsule

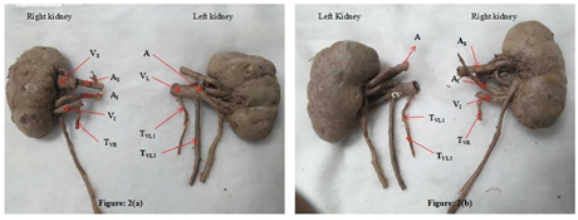

Figure 2(a): Anterior view of kidneys showing on the right double renal veins (V_S,V_I)and double renal arteries (A_S,A_I) on the right, and a vein from testis (T_{VS}) drained into inferior renal vein(V_I). Accessory renal artery(A) on the left passing anterior to renal vein. Fiture 2(b): Posterior view of kidneys showing on the left multiple hilar vein forming a renal vein, a vein from testis drained into common renal vein(CV) another into renal vein main renal vein.

V_S: Superior renal vein — V_I: Inferior renal vein
A_S: Superior renal artery — A_I: inferior renal artery
T_{VR}: Tributary from testis draining into inferior renal vein — V_L: Left renal vein
T_{VL1}: Tributary from testis drained into renal vein — T_{VL2}: Tributary from testies drained into common renal vein
A: Accessory artery on right side

The same kidney was drained by two renal veins- Superior and Inferior (figure 1). Superior renal vein had larger calibre emerged from the renal hilum in ventral relation to the two branches of superior renal artery. It drained into the inferior vena cava at higher level compared to the left renal vein. The inferior renal vein emerged from the medial border of the inferior pole of right kidney, just below the site where the supernumerary renal artery entered the kidney. This aberrant renal vein terminated into inferior vena cava at the same level where left renal vein joined the inferior vena cava. This aberrant vein received a tributary from the testicular venous plexus found in this cadaver (figure 1).

Bilaterally a single testicular vein was replaced by anastomotic venous channels, which received a tributary from the perinephric fat. The venous channel coalesced to form three testicular veins on the right and

two on the left. On the right, one testicular vein drained into the inferior renal vein draining the inferior pole of right kidney, remaining two terminated in inferior vena cava at an acute angle. On the left, the two testicular veins drained separately into the renal vein (fig. 1).

While performing careful dissection on the left side, we found a supernumerary renal artery which sprouted from the renal artery (figure 2a). This aberrant artery crossed the renal vein anteriorly and entered the medial border of the inferior pole left kidney. This anterior relation of artery to the vein may generate confusion during the surgery. The main renal artery after giving the aberrant branch divided into ventral and dorsal divisions. The ventral division further divided into two branches before entering the renal hilum (figure 2b).

On the left, three veins drained the renal parenchyma. Two emerged from the renal hilum, third vein emerged from the medial border near the inferior pole and had the aberrant renal artery in its inferior relation. The two of these renal veins joined to form a common vein(V) into which the third vein drained to form a renal vein. One out of the two testicular veins drained into the common vein(V) formed by union of two renal tributaries. The second testicular vein drained into the main renal vein formed by the three renal tributaries.

Discussion

The existing literature has extensive data regarding morphological variations and relation of the structures in renal hilum. But because of the high risk of operative complications and preceding patient morbidity after renal surgeries, it necessitates an anatomist to report any variation in the structures present in renal hilum.

Merklin and Michels (1958) studied the origin of supernumerary renal arteries and grouped them in three categories on the basis of their origin from: 1) aorta, 2) main renal artery, 3) from other source. We are reporting in the same cadaver two different categories stated by Merklin and Michel. On the right Merklin's and Michel category 1) and category 2) on the left side.

Virendra, et. al. (2013) reported in Indian population the incidence of additional renal arteries to be 62.2% cases(48.6% of aortic origin and 13.5% of renal origin) on the right and 56.8% cases(45.6% of aortic origin and 13.5% of renal origin) on the left. In 8.4% cases they observed supernumerary artery entering from the hilum. Talonic, et. al. (2007) reported in European population the incidence of supernumerary renal arteries originating from aorta as 30.76% cases and from renal artery as12.82% cases. The finding of the current study goes in accordance with the previous work done as we are reporting on the right an additional renal artery originating from aorta and on the left originating from the main renal artery.

The literature pertaining to renal vein is poor compared to renal artery (Satyapal, 1995). According to Nayak (2008) variations associated with renal vein are less compared to the renal arteries. Satyapal, et. al. (1995) and Janschek (2004) stated that, right renal vein is comparatively more variant than left renal vein. Satyapal, et. al. (1995) studied the frequency of multiple renal veins in Indian population and reported 26% on the right whereas 2.6% on the left. Janschek (2004) measured the incidence of multiple renal vein in European population and documented it on the right as 23% and on the left as 6.7%. In the current case, doubling of renal vein is seen on the right in accordance with the exising literature. However we are reporting two different venous variants one on each side in the same cadaver. An additional renal vein may provide alternate route for venous blood flow during inferior vena cava obstruction between the two renal veins, establishing a collateral circulation salvaging the kidney from congestive injury (Greweldinger, 1969).

The gonadal vessels have imperative role in thermo-regulation of testis hence variations in their course and branching patterns may help clinicians to make a provisional diagnosis of rare clinical presentation leading to infertility (Malar, 2016). Malar (2016) reported the occurance of double testicular vein on the right in 4% cases and on the left in 8% cases. According to Tubbs (2005) pre-operative awareness of the existence of multiple testicular veins reduce the chance of post-operative recurrence of varicocele. Malar (2016) also reported that in 4% cases right testicular vein terminated into renal vein. This variant termination of right testicular vein into right renal vein is a predisposing factor for right side varicocele. Authors have reported that gonadal vein may receive tributaries from other sites. Such tributaries may establish collateral circulation for the kidney during renal vein obstruction or portal hypertension (Bergman, 1992-2004 and Sofikitis, 1993).

Conclusion

The familiarity about the variations of reno-testicular vasculature is vital for the, radiologist to make the correct diagnosis and surgeons to plan the surgery to reduce the intra and post operative complications as well as potential failure of surgery due to anomalous anatomy.

Reference

1. Bergman R. A., Afifi A. K., & Miyauchi R. (1992-2004). Illustrated encyclopedia of human anatomic variation: opus II: cardiovascular system: veins: abdominal gonadal veins.
2. Greweldinger J., Coomaraswamy R., Luftchin S., Bosnaik M. A. (1969). Collateral circulation through kidney after inferior vena cava ligation. New England Journal of Medicine. 258. 541-54.
3. Gardner S. Unusual drainage of the right testicular vein: a case report. (2015) Case reports in clinical medicine. 4. 237-240
4. Janschek E. C., Rothe A. U., Holzenbein T. J., Langer F., Brugger P. C., Pokorny H., Domenig C. M., Rockenschaub S. R., Muhlbacher F. (2004). Anatomic basis of right renal vein extension for cadaveric kidney transplantation. Urology. 63(4). 660-664.
5. Malar D. (2016). A STUDY OF VARIATIONS OF TESTICULAR VEIN AND ITS CLINICAL SIGNIFICANCE. International Journal of Anatomy and Research. 4(1). 1985-87.
6. Merklin, R. J. & Michels, N. A. (1958 January). The variant renal and suprarenal blood supply with data on the inferior phrenic, ureteral and gonadal arteries: a statistical analysis based on 185 dissections and review of the literature. The Journal of the International College of Surgeons. 29. pp. 41-76.
7. Nayak B. S. (2008). Multiple variations in right renal vessels. Singapore Medical Journal. 49(6). 153-155.
8. Satyapal K. S. (1995). Classification of drainage pattern of renal veins. Journal of Anatomy. 186. 329-339.
9. Satyapal K. S., Rambiritch V., & Pillai G. (1995). Additional renal vein: incidence and morphometry. Clinical Anatomy. 8(1). 51-55.
10. Sofikitis N., Dritsas K., Miyagawa I., & Koutselinis A. (1993). Anatomical characterstics of the left testicular venous system in man. Archieves of Andrology. 30. 79-85.
11. Standring, S. (2016). Gray's Anatomy. (41 ed.). New York: Elsevier Churchill Livingstone. 1243-1273.
12. Tubbs R. S., Salter E.G., Oakes W.J. (2005). Unusual drainage of testicular veins. Clinical Anatomy. 187(4). 536-539.
13. Talovic, E., Kulenovic, A., Voljevica, A., & Kapur, E. (2007). Review of supernumerary renal arteries by dissection method. Acta Medica Academic. 36. 59-69.
14. Virendra, B., Rakhi, R., Vaibhav, A., Ramesh Babu, C. S., & Prabhat, G. (2013). Supernumerary Renal Arteries and Their Embryological and Clinical Correlation: A Cadaveric Study from North India. International Scholarly Research Network Anatomy. 2013. article id 405712.