VOLUME-6 | ISSUE-3 | MARCH - 2017 • ISSN No 2277 - 8179 | IF : 4.176 | IC Value : 78.46

Accessory spleen or supernumerary or splenunculi

Anatomy

KEYWORDS: Accessory spleen,Hilum,Anterior end,Posterior superior border,inferior border

Bala N

Sharma RK

Kullar JS

ABSTRACT

Accessory spleens are congenital and arise from the left side of dorsal mesogastrium during the embryological period of development. They are usually asymptomatic but might present clinically as an abdominal mass leading to complication such as torsion, spontaneous rupture, haemorrhage and cyst formations. Accessory spleen or Splenunculi are important in haematological disorders for which splenectomy is the treatment of choice. As such, variation of this kind is rare but has various important clinical implications in the field of surgery, radio diagnosis and gastroenterology. Accessory spleen may result in interpretation errors in diagnostic imaging or continued symptoms after therapeutic speenectomy

Material and method: The present study was conducted on 50 adult human cadaveric spleen with the aims and objective to find out anatomical basis of variations among normal study.

Results: The results obtained were three spleens out of fifty shows accessory spleen,they observed, analysed and compared to other literature

Conclusions: Knowledge of this variation of spleen is of fundamental importance to the surgeons while they perform surgical operation; so in splenectomy for non-haematologic causes accessory spleens should be preserved to prevent infection and sepsis after splenectomy.

Introduction: Accessory spleens are also known as supernumerary spleens, splenunculi, splenules or lenculi. These are small detached, roundish nodules occasionally found in neighbourhood of spleen and are similar to its substance.[1] They are always located on the left side of the abdomen after the rotation of spleen during embryogenesis[2]. The sites where accessory spleen is commonly found are hilum of the spleen (75%) and near the tail of pancreas (20%).[3] The other sites include gastrosplenic ligaments, walls of stomach, greater omentum or even in the pelvis and scrotum[4].

Material and methods: This anomalous spleen was detected during dissection for thesis work . Once the anomaly was identified, the spleen along with its arterial and venous supply was resected, including the stomach from the lower oesophageal junction, the duodenum, the short gastric vessels, pancreas, coeliac arterial trunk and mesenteric veins up to the formation of portal vein. All structures were removed out en block for permanent fixation and plastination. All material was made available by the Department of Anatomy, Govt. Medical College, Amritsar

Results: In the present study accessory spleens were present in 3 (6%) spleens, measuring 1.2×1.2×0.8cm,1.6×1.4×1.2and1.6×1.4×1cm shown in fig1,2 and 3.

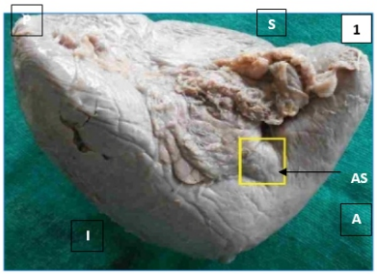

Fig1.Showing the visceral surface of spleen with accessory spleen ant end

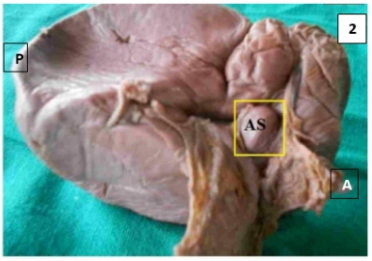

Fig.2 Showing visceral surface of spleen with accessory spleen at hilum of spleen

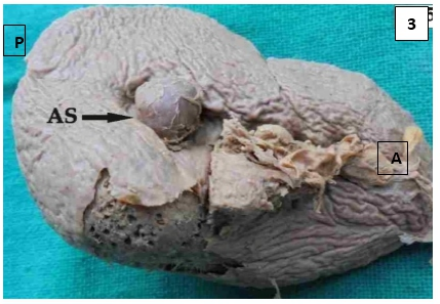

Fig3. Showing an accessory spleen at the posterior end of hilum

Discussion: Accessory spleens are the most common anomaly associated with the spleen and are identified in 10-30% of cadavers at autopsy (Dodds et al., 1990) Thanya et al (2011 Reported a case with four accessory spleens, two at the splenic hilum measuring 1 cm x 1.5 cm x 1 cm and 2.5 cm x 2cm x 1.5 cm in size which had dedicated arterial twigs ultimate branch and inferior polar arteries branching out of the main splenic artery and two others each of 1.5 cm x 1 cm x 1cm[4].

Rayhan et al (2011) The presence of an accessory spleen was also observed in situ. Accessory spleen was found in 24.28% of cases. but in present study accessory spleen was present only in 6% cases which was slightly lower may be due to ontogenic basis[4].

Ontogeny: Accessory spleens are congenital and arise from the left side of dorsal mesogastrium during the embryological period of development.,when some of the cells from the developing spleen are deposited along the path from midline,where the spleen forms,over its final location of abdomen by 9-11thribs.The most common location for accessory spleen are the hilum of the spleen and adjacent to the tail of the pancreas. They may be found anywhere along splenic vessels, gastrosplenic ligament, greater omentum and pelvis

Summary and conclusion: This case report addresses the clinical significance and developmental basis of accessory spleen. Accessory spleens resemble normal spleen in structure and in immunologic functions. Knowledge of this variation of spleen is of fundamental importance to the surgeons while they perform surgical operation; so in splenectomy for non-haematologic causes accessory spleens should be preserved to prevent infection and sepsis after

splenectomy. In addition, splenunculi can mimic tumours of the kidney, pancreas and pelvis. Thus it is important to identify splenunculi either by CT scan or by 99m Tc heat-denatured red blood cell scan.This will be helpful for radiologist and surgeons to avoid errors in interpretation and misdiagnosis and also in planning appropriate surgical approaches. This is very important for anatomists during routine cadaveric dissections

References:

1. Chhabra N, Shrivastava T, Garg L, Mishra BK. Accessory spleen and its clinical significance. Int J Anat Res. 2014; 2(2):325-7.
2. Nallathamby R, Avadhani R, Bhat S, Jacob M, Soman MA. Partially fused Splenic Lobule-A case report. Int Uni J Heal Scie.2014Vol4(3):2249-7100
3. Thanya LP, Mathew JB, Mark G, Mark RF, Sujeewa P.W.P.A rare anomally of human with nine notches associated with multiple accessory spleens. A case study, Hypothesis on origin and review of clinical significance. IJAE.2016;121:188-197.
4. Ara A, Rayhan MM, Ara ZG, Chowdhury AL, Begum T, Chowdhury MR, Fazilatunnesa. Incidence of accessory spleen in Bangladeshi cadaver. CBMJ;2012;17-19
5. M Harsh,Amanjit,Bhardwaj S,Handa U.Splenunculi-Report of Anat.Soc.India.2002;51 (1)70-1.
6. Nayak BS, Somayaji SN, Soumya KV. A study on the variation of size, shape and 9xternal feature of the spleen. Int J morphol. 2011;29(3):675-7.
7. Curtis GM, Movitz D. The surgical significance of the accessory spleen.Ann Surg. 1946 February; 123(2): 276-98.
8 Pushpalatha M, Sujana M, Sharmada K L. Accessory Spleen –a case report. Int J Cur Res.2012Nov;4(1):121-2.
9. Churei H, Inoue H, Nakajo M. Intrapancreatic accessory spleen:case report. Abdom Imaging 1998;23:191-3.