Volume : 4 | Issue : 6 | June 2015 • ISSN No 2277 - 8179

Research Paper

Medical Science

KEYWORDS : Tonsil, Actinomycosis, Abscess, Chronic tonsillitis, Reactive Lymphoid Hyperplasia.

Actinomyces Infection Leading to Abscess Formation in Chronic Tonsillitis

Sujatha Nagari — Tutor, Dept of Anatomy, Shri Sathya Sai Medical College & Research Institute, Ammapettai, Kancheepuram District, Tamilnadu.

Swayam Jothi S — HOD, Dept of Anatomy, Shri Sathya Sai Medical College & Research Institute, Ammapettai, Kanch eepuram District, Tamilnadu.

Hemanth Kommuru — Tutor, Dept of Anatomy, Shri Sathya Sai Medical College & Research Institute, Ammapettai, Kancheepuram District, Tamilnadu.

Manimaran M — Professor, Dept of Pathology, Shri Sathya Sai Medical College & Research Institute, Ammapettai, Kancheepuram District, Tamilnadu.

Kafeel Hussain A — Asst Professor, Dept of Anatomy, Shri Sathya Sai Medical College & Research Institute, Ammapettai, Kancheepuram District, Tamilnadu.

ABSTRACT

Actinomycosis of the tonsillar tissue is a rare pathological condition whose clinical significance has been disputed over by authors worldwide. Biopsy Specimen of chronic tonsillitis showing Actinimycoses leading to abscess formation were involved in this study. Actinomycosis is an uncommon, chronic bacterial infection that induces both suppurative and granulomatous inflammation13. The diagnosis of actinomycosis is challenging because the infection is rare, insidious, chronic, has nonspecific symptoms and imitates more common conditions such as malignancy and TB.

In the present study of tonsillar biopsy specimen showed 9 cases of Actinomycosis infection, in that one specimen showed actinomycoses, a rare occurrence of reactive actinomycotic tonsillar lesion leading to abscess formation in a 11-year-old girl. The histopathology of the tonsillectomy specimens revealed colonies of Actinomyces in tonsillar crypts, along with cryptitis, acanthotic squamous epithelium with intraepithelial inflammatory cells, ulceration, tonsillar fibrosis and reactive lymphoid hyperplasia.

INTRODUCTION:

The first reported case of human infection with Actinomycosis was by Von Langenbeck in 1845 and was attributed to a fungus. Harz, in 1877, named the infecting organism Actinomyces, which means ray fungus, reflecting the belief at the time that the organism was a fungus. Israel and Ponfick delineated the anaerobic nature of Actinomyces and isolated it from humans in 1891. In the 1960's Waksman showed that Actinomyces was actually a gram-positive bacteria. Since their proper identification in the 1960's, five species have been identified. The principal cause of human actinomycosis is A.israelii. The presence of Actinomycosis in the tonsils has been identified in 1896[11].

Actinomycosis is caused by the Gram-positive, non- acid fast, anaerobic, branching, filamentous bacteria which results in chronic suppurative inflammation of the organs involved. Normally the organism lives as a commensal in human oral cavity[12], colon and vagina. The disease is characterized by spread to contiguous tissues because of disruption of anatomical barriers by dental caries or trauma, surgery or another infection. Once it enters the tissues, it may form an abscess that develops into a hard red to reddish purple lump. When the abscess breaks through the skin, it forms pus-discharging lesions[14].

AIM:

To study Actinomycotic infection in chronic tonsillitis specimens & its sequelae leading to abscesses formation.

MATERIALS & METHODS:

One hundred and thirty palatine tonsils surgically removed by ENT Dept of Shri Sathya Sai Medical College, Ammapettai from 65 cases sent to the department of pathology which were reported as chronic tonsillitis were utilized for the study. Of them 9 cases showed Actinomycosis infection, in that one specimen showing actinomycoses with micro abscess formation was studied in detail.

Surgically removed bilateral tonsillar tissues were fixed in formalin, embedded in paraffin and prepared slides stained with H&E were studied. Serial sections were taken for those specimens showing Actinomycosis infection and the slides were stained with Gram Stain.

OBSERVATIONS:

In 9 cases of chronic tonsillitis with actinomycotic colonies presented neutrophilic infiltration cryptitis, reactive lymphoid follicular hyperplasia, and tonsillar fibrosis. Of them one of the excised bilateral tonsillar tissue showed the following observations.

- Sub epithelial fibrosis characteristic of chronic tonsillitis was also observed (Fig:1)
- Acanthotic squamous epithelium with intraepithelial inflammatory cells (Fig:2)
- Presence of multiple Actinomycotic colonies with dense neutrophilic infiltration with an outer zone of granulation tissue and a central zone of necrosis (Fig:3).
- Gram stain showed bacterial colonies in the crypt of tonsil (Fig: 4a & 4b)

DISCUSSION:

The presence of Actinomyces in normal and diseased tonsils and its clinical significance in tonsillar crypts are controversial in the available literature sources. Actinomycotic infection has been reported in a small percentage of people presenting with chronic tonsillitis[3]. The principal cause of human Actinomycosis is A.israelii. The Actinomyces are common saprophytic microorganisms which are found in the oral cavity and palatine tonsils[1] and are found in 2% -30% of subjects[1-3,7,10]. In the present study Actinomycosis infection was seen in 13.8% of specimens. Mucosal disruption of the tonsil is required for the bacteria to become infective in the tonsil.

Volume : 4 | Issue : 6 | June 2015 • ISSN No 2277 - 8179

Actinomycosis can be diagnosed by positive cultures, sulphur granules or on biopsy specimens[8].The typical findings on histological examination of the tissue is diagnostic with an outer zone of granulation tissue and a central zone of necrosis containing many granules that represent microcolonies of actinomyces[5]. The same findings were observed in present study.

Pransky et al [10] found that histological examination of the core tissues of the tonsils will accurately detect the presence of these organisms. Gaffney et al[7] reviewed 42 tonsils with Actinomycosis and found no correlation between the presence of Actinomycosis and tonsillar fibrosis or micro-abscesses, and concluded that Actinomycosis was present only as a saprophyte. Contrary to above report the present study showed Actinomycosis with tonsillar fibrosis and micro-abscess.

Van Lierop et al[16]examined 344 tonsils and found no tissue reaction due to Actinomyces colonies and hence reported that there was no correlation between tonsillar Actinomycosis and recurrent tonsillitis. Toh et al [15] examined 834 specimens and found no correlation between tonsillar hypertrophy and Actinomycosis. Both these reports showed no tissue reaction in spite of Actinomyces colonisation of tonsils. Contrary to the above reports, Aydin et al[2] analysed 1820 tonsillectomy specimens and reported that cryptitis was a common histopathologic indicator of tonsillar actinomycosis. In the present study, all biopsy specimens showed cryptitis as common histopathologic indicator. Assimakopoulos et al[1] studied the histopathological sections of 238 tonsils and concluded that Actinomyces colonisation of the tonsillar crypts was significant in causing chronic tonsillitis. The Present study showed cryptitis, presence of lymphoid hyperplasia, tonsillar fibrosis and Actinimycotic colonies giving a positive reaction in causing chronic tonsillitis.

Hematoxylin-eosin (H&E) staining has been shown to be highly effective in detecting Actinomyces colonies[7,10]. The presence of Actinomycosis can be recognized as aggregates of filamentous basophilic microorganisms arranged in a radial spoke-like fashion; the so-called **"ray-fungus"** appearance of an Actinomyces colony[3,7,10] as seen in the present study.

Localized swelling with suppuration, abscess formation, tissue fibrosis and draining sinuses characterize actinomycosis [4,13]. Actinomycosis can be acute, subacute or chronic. Chronic disease is typically a painless infiltrative indurating process that leads to the formation of multiple abscesses [6].

CONCLUSION:

Actinomycetes are anaerobes that release proteolytic enzymes which diminish oxidation-reduction potential and leads to proliferation of the organisms that invades the surrounding tissues[10]**.** This may lead to the colonisation of Actinomycotic organisms normally present within the tonsillar crypts[3,10]. The histopathological examination of tonsils in our case report also documents a definite tissue reaction to the Actinomyces colonies. To conclude that Actinomyces colonisation of the tonsillar crypts was significant in causing chronic tonsillitis. Though a known commensal, Actinomycosis may have an etiological role in long standing symptomatic tonsillar lesions refractory to antibiotic treatment. Increased awareness regarding actinomycosis and high degree of suspicion are required so that an early diagnosis is possible.

Definitive diagnosis of Actinomycosis is important as it helps in initiating appropriate antibiotic therapy early[9].

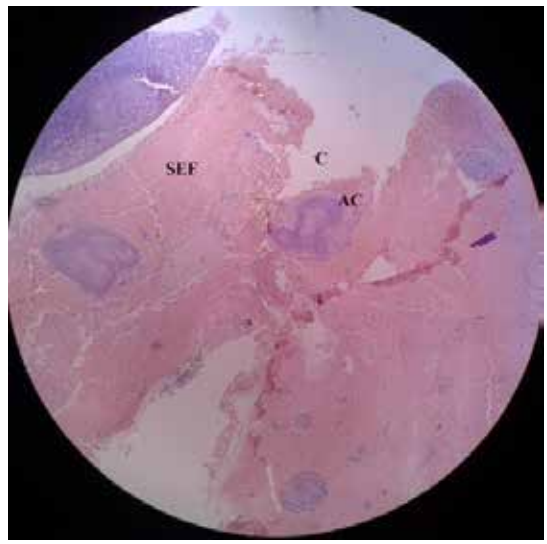

Fig: 1 - Subepithelial fibrosis characteristic of chronic tonsillitis due to Actinomycotic colonies is seen (H&E x4)
AC – Actinomycotic colony; C – Crypt; SEF – Subepithelial fibrosis

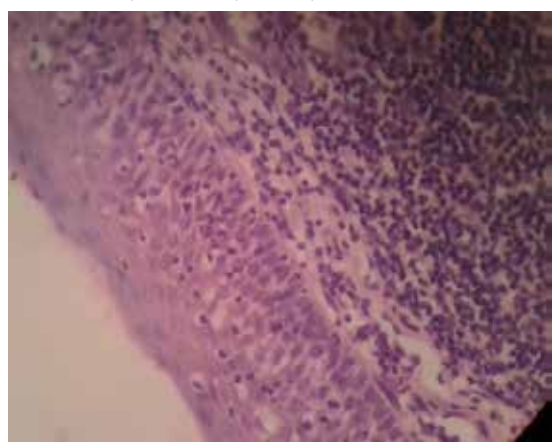

Fig: 2 shows Acanthotic squamous epithelium with intraepithelial inflammatory cells in chronic tonsillitis(H&Ex10)



Fig:3 Tonsil showing Actinomycotic bacterial colony with branching filaments with outer zone of granulation tissue surrounded by neutrophilic infiltration and central zone of necrosis (H&E x 40)

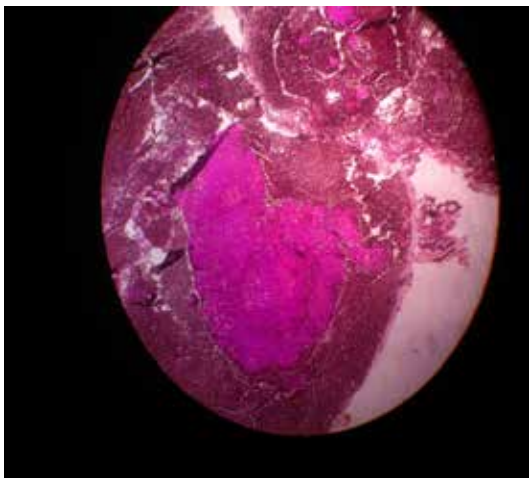

Fig4a: shows gram positive Actinomycotic bacterial colonies in the crypt of tonsil (Gram stain x10)

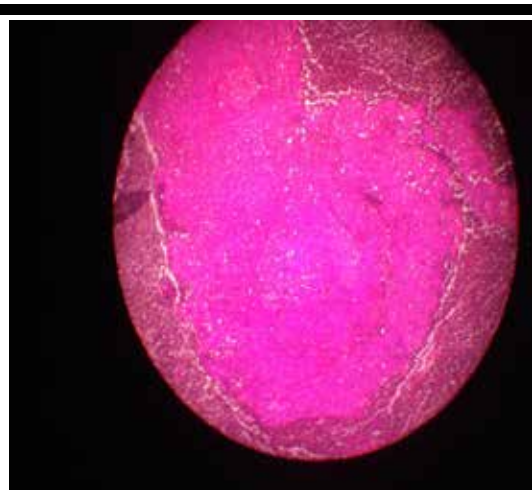

Fig4b: shows gram positive Actinomycotic bacterial colonies in the crypt of tonsil (Gram stain x40)

REFERENCE

1. Assimakopoulos D, Vafiadis M, Askitis P, et al. The incidence of Actinomyces israelii colonization in tonsillar tissue. A histopathological study. Rev Stomatol Chir Maxillofac 1992; 93:122–126. | 2. Aydin A, Erkiliç S, Bayazit YA, Koçer NE, Ozer E, Kanlikama M. Relation between actinomycosis and histopathological and clinical features of the palatine tonsils: a comparative study between adult and pediatric patients. Rev Laryngol Otol Rhinol (Bord) 2005;126:95-8. [16180348] | 3. Bhargava D, Bhusnurmath B, Sundaram KR, Raman R, Al Okbi HM, Al Abri R, et al. Tonsillar actinomycosis: a clinicopathological study. Acta Trop 2001; 80:163–168. | 4. Brook I. Actinomycosis: diagnosis and management. South Med. J. 101, 1019–1023 (2008).*- | 5. Brown JR. Human actinomycosis. A study of 181 subjects. Hum Pathol 1973 ; 4 : 319 – 30 . | 6. Chouabe S, Perdu D, Deslee G et al. Endobronchial actinomycosis associated with foreign body: four cases and a review of the literature. Chest 121, 2069–2072 (2002). | 7. Gaffney R, Harrison M, Walsh M, Sweeney E, Cafferkey M. The incidence and role of actinomyces in recurrent acute tonsillitis. Clin Otolaryngol Allied Sci 1993; 18: 268-271. | 8. Mohanty S. Actinomycosis of faucial tonsil masquerading as oropharyngeal malignancy. Indian J Otolaryngol Head Neck Surg 2006 ; 58 : 82 – 4 . | 9. Patnayak R, Jena A, Rukmangadha N, Chowhan AK, Phaneendra BV, Reddy MK, Sreenivas G. Reactive Actinomycotic tonsillar lesion. J Clin Sci Res 2012;2:39-41. | 10. Pransky SM, Feldman JI, Kearns DB, Seid AB, Billman GF. Actinomycosis in obstructive tonsillar hypertrophy and recurrent tonsillitis. Arch Oto- laryngol Head Neck Surg 1991; 117:883-5. [1892620] | 11. Rippon JW. Medical Mycology. W.B. Saunders: Philadelphia; 1974. p. 13–28). | 12. Schwartz HC, Wilson MC. Cervicofacial actinomycosis following orthognathic surgery: report of 2 cases. J Oral Maxillofac Surg 2001;59: 447-9. (1) | 13. Smego RA Jr, Foglia G. Actinomycosis. Clin. Infect. Dis. 26, 1255–1261 (1998). | 14. Stewart MG, Sulek M. Pediatric actinomycosis of the head and neck. Ear Nose Throat J 1993; 72:614–9. | 15. Toh ST, Yuen HW, Goh YH. Actinomycetes colonization of tonsils: acomparative study between patients with and without recurrent tonsillitis.J LaryngolOtol2007;121:775-8. | 16. Van Lierop AC, Prescott CA, Sinclair- Smith CC. An investigation of the significance of Actinomycosis in tonsil disease. Int J PediatrOtorhinolaryngol2007;71:1883-8. |