ORIGINAL RESEARCH PAPER

Volume-7 | Issue-5 | May-2018 | PRINT ISSN No 2277 - 8179

INTERNATIONAL JOURNAL OF SCIENTIFIC RESEARCH

ACUTE COLONIC PSEUDO-OBSTRUCTION (OGILVIE'S SYNDROME) AFTER HIP REPLACEMENT: CASE REPORT

Orthopaedics

Leonardi Francesco Operative Orthopedic Unit– Hospital of Savigliano (Italy)

Zorzan Alessandra* Operative Orthopedic Unit– Hospital of Savigliano (Italy) *Corresponding Author

Palermo Augusto Italian Auxologic Institute – IRCSS Capitanio – Milano (Italy)

Molfetta Luigi University of Genoa –Medical and Phamaceutic school–Research Center on Osteoporosis and Osteoarticular Disease – Genoa (Italy)

ABSTRACT

Summary

Ogilvie syndrome is characterized by clinical and radiographic evidence of severe intestinal obstruction, in the absence of mechanical causes, with ischemic and perforative innards manifestations and with high mortality rate. There are numerous predisposing diseases, such as infections, cardiopathies, vertebral and retroperitoneum traumas and hip surgery, especially prosthetics. It is characterized by an autonomous alteration of intestinal motility, with pseudo-obstruction and dilatation of the colon, correlated with a parasympathetic depression (which increases intestinal motility) or an activation of the sympathetic. The prognosis is affected by precocity of the diagnosis, but also influenced by many other factors, such as: age; general debilitated state; degree of cecal dilatation; anatomical state of the intestine; and delay in decompression. The most serious complication is the perforation of the colon. An appropriate and immediate pharmacological treatment can eradicate the complication that also makes use by surgical decompression aimed at avoiding the conditions of intestinal ischemia and / or perforation. The described case of a patient operated by hip arthroplasty that we describe is peculiar to the diagnostic difficulty and rapid evolution.

KEYWORDS

hip, arthroplasty; Ogilvie's syndrome.

Introduction

The syndrome of acute pseudo-obstruction of the colon (ACPO) is also called Ogilvie's syndrome defined by the first author who in 1948 described it in two cases of retroperitoneal malignancy with invasion of the celiac plexus (1). It is a rare disease, prevalent in males (60%), on average around 60 years of age; is characterized by clinical and radiographic evidence of severe intestinal obstruction, in the absence of obvious mechanical causes and can be complicated with ischemic manifestations and with innads perforation (3-15%). In the literature, the clinical picture and predisposing situations are widely described (2) as well as incidence in prosthetic surgery which is on average 1.3%. Diagnosis is not always easy and early, it is often delayed with a high complication rate and sometimes over 50% in mortality. Like literature showed since last 10 years ago, the case report of a patient operated by hip arthroplasty that we describe is peculiar to the diagnostic difficulty and rapid evolution desease.

Case Report

86-year-old woman, normotype, with severe left-sided coxarthrosis, is operated on total hip replacement. In anamnesis section the patient is in therapy for essential hypertension and hypercholesterolemia. The pre-operative ECG test documents a sinus tachycardia with left anterior hemiblock. Chest x-ray shows modest fibrosis with notes of emphysema and slight increase in the diameter of the thoracic aorta. Pre-operative hematochemical tests result in a slight anemia (Hgb 11.8) and a positive urine culture test for Escherichia Coli, negativized after antibiotic therapy. The anesthetic risk is judged to be equivalent to III ASA. The intervention under general anesthesia is with regular duration and course (PAO 105/65 mmHg, FC 100 / min, sO2 91%, diuresis 700 ml, blood loss 700 ml and then from the redon 450 ml). Morphine is infunded by control pain. On the first post-operative day from the tests there was a significant reduction in the Hgb value of 8.9 g / dL, thrombocytopenia (PLT 122 K / microl), mild kidney insufficiency (azotemia 63 mg / dL, creatininemia 2.28 mg / dL), reduction of prothrombin time (62%, INR 1.36). It is therefore transfused with 2 of concentrated blood cells bags, it continues both the post-operative hydration (1500 ml / 24h) and therapy with low molecular weight Heparin (EBPM) at the dosage of 4000 IU / 24h and standard prophylaxis with pantoprazole 40 mg / day and indomethacin 75 mg / day in 3 administrations to prevent periprosthetic ossifications, as well as anti-hypertensive home therapy. In the afternoon, however, develops nausea, painful abdominal distension with no intestinal transit. Also appears an alteration of the general state with agitation; hypoxia (oxygen saturation equal to 81.3% ambient air) and a metabolic acidosis (pH 7.086, pCO2 24.4 mmHg). It is transferred to intensive care. Therefore, a thoracic and abdominal CT scan is performed that shows a minimum amount of bilateral pleural effusion with disentilation of the adjacent parenchyma, but at the abdominal level the picture is dramatic: esophagus; stomach; duodenum and some ileal loops are markedly distended by fluid material with evidence of hydro-air levels in the absence of evident intrinsic or extrinsic stenosis. A gastroscopy is scheduled which is not performed due to the worsening of general clinical conditions. The metabolic acidosis is treated by bicarbonate and pharmacological coma is induced (curarized, sedated, ventilated) to better manage the pain and the general clinical conditions. In the meantime, an ST segment subdivision and bradycardia appear at the ECG; dopamine is administered, transfused with concentrated red blood cells and platelets.

Therefore, kidney function worsens (azotemia reaching 101 and creatininemia at 3.5 within 24 h), liver function (AST 2028, ALT 1204), and above all the values of some hematochemicals such as amylasemia at 1943, CK-MB mass > 300, CPK 13299, myoglobin> 3000, LDH 5380. The intensive care team continued therapy with dopamine; hydration and ventilation in a pharmacological coma up to the patient's exit which occurs about 48 hours after hip replacement surgery . The diagnostic check is not performed.

Discussion

Ogilvie's syndrome affects patients admitted to institutions for chronic patients or hospitalized in severe conditions. In surgery patients, the complication may start either within 24 hours of surgery or in the following 6 days with an average of 5 post-operative days. The pathogenesis, not entirely known, correlated in over 90% of cases with a series of concomitant and predisposing disease, such as : trauma (11%),;infections (10%), cardiopathies (10%); caesarean section; manipulations and /or vertebral trauma, retroperitoneum trauma (52%) (3) or with hip surgery, in particular prosthetic (4). In 70% of cases post-operative therapy included drugs or hydroelectrolytic imbalances. Abdominal pain and distension, nausea and vomiting (60-80% of cases) are associated with fever and leukocytosis; the acute abdomen of ischemia and / or intestinal perforation is characterized by a greater severity check.

The abdomen x-ray imaging is the first and most significant examination; confirms the degree of dilatation of the large intestine, in particular to splenic flexion and descending colon, sometimes with

dilatation of the small intestine. The complication must be differentiated from a CT scan or from the use of the contrast medium by a mechanical obstruction or by a toxic megacolon of Clostridium. The characterizing data are an autonomous alteration of intestinal motility, with pseudo-obstruction and dilatation of the colon, correlated with an alteration of the autonomic nervous system, with a parasympathetic depression (which increases intestinal motility) with atony, dilatation and intestinal obstruction or activation of sympathetic, which amplifies the inhibitory function on the large intestine. The intraparietal mechanoreceptors in intestine, stimulated by the distension, activated a further inhibition of the movement of the colon (5). In the case report showed, the complication was not identified, without any specific therapy, with treatment of the signs and symptoms that appeared in gradually way. Abdominal CT showed the marked visceral distention in colon site (Fig.1,2,3), without obvious mechanical obstructions; the image depicted for an Ogilvie syndrome. Abdominal pain (morphine was administered) was associated with the CT picture as well as the considerable distension of the loops, without an increase in temperature or white blood cells, which occurred only in the hours before death.

Prognosis is affected by the severity of syndrome, but also influenced by other factors such as :age;general debilitated state; degree of cecal dilatation; tanatomical state of the intestine; the delay in decompression. The most serious complication, like colon perforation, has a low incidence (3% according to Rex et al.) (6), while mortality is high, equal to 40% in the presence of ischemia or perforation; it is reduced to 12-13% in patients with a valid intestinal wall. Only with an early diagnosis is meant a correct conservative or endoscopic decompression therapy, for the degree of abdominal distension, peritonitis or perforation (7).

In several retrospective analyzes, it was possible to identify pathogenic prevalence factors, such as the cecal diameter of more than 12 cm, which was further denied by other revisions; a factor of greater prevalence is considered the duration of the extension, especially if greater than a week, as reported by Johnson et al. (8). Blind dilatation is related to mortality that doubles if it is greater than 14 cm or five times if the decompression delay exceeds 7 days. Supportive therapy requires first of all hydration e.v., correction of hydroelectrolytic imbalances, aspiration with nasogastric tube. Patient ambulation and mobilization are encouraged. Conservative treatment is therefore successful as a primary treatment in most patients. Sloyer et al.

report outcome of 25 patients with non-gastrointestinal cancer with ACPO; the mean diameter of cecum in the 25 patients was on average 11.7 cm (range: 9-18). 24 patients were treated conservatively, 23 (96%) improved clinical and radiological criteria with an average time of 1.6 days (mean: 3 days). There are no perforations or exitus related to ACPO. In another retrospective study group of 151 patients, 117 (77%) had a spontaneous resolution of ACPO with primary compensatory treatment aimed at eliminating or reducing known pathogenic factors. By increasing cecal distention (> 10 cm) or increasing the duration of time (> 3-4 days), persistent symptoms despite treatment after 24-48 hours of supportive therapy, such patients are candidates for further interventions (9). About the pharmacological therapy, Neostigmine, reversible acetylcholinesterase, were used intravenously thirty years ago by Neely and Catchpole in the paralytic ileus for stimulation action on the muscarinic receptors.

It has been shown to improve the motor activity of the colon, inducing its propulsion, with rapid onset (1-20 ') . In a double-blind, randomized, controlled versus placebo study, neostigmine was used in patients with ACPI with a cecal diameter greater than 10 cm and with a negative response after 24 h of conservative treatment. The clinical response was observed in 10 of 11 patients (91%) compared to placebo. The median time to the answer was 4 '; the diameter reduction of the average blind was 5 vs. 2 cm, while the abdominal circumference of 7 versus 1 cm. 8 patients not responding to the initial infusion were initiated for open-label treatment with neostigmine with abdominal decompression and 17 (94%) had prompt intestinal decompression. In absence of peritonitis or perforation signs, medical therapy with neostigmine should be considered the initial therapy of choice. There are only case reports about use of other prokinetics, such as Erythromycin, reported by Armstrong et al. in two oral patients (500 mg four times a day) for 10 days (10). Colon decompression is the initial invasive procedure of choice for patients with blind distension greater than 10 cm, lasting longer than 3-4 days, without response to supportive therapy after 24-48 hours or with contraindications to pharmacological treatment with neostigmine (11). The colonoscopy in particular is performed to prevent intestinal ischemia and perforation. Surgical therapy is reserved for patients with signs of ischemia or perforation, unresponsive to all pharmacological or colonscopic decompression treatments. Surgical therapy is burdened by a high mortality rate, given serious general conditions of departure. Cecostomy is the treatment of choice with a high rate of success, with low morbidity; colic resection is indicated in cases of severe perforation or extensive wall necrosis. In this case report, the non-specific diagnosis allowed to perform a correct therapy only in relation to hydration, without any other appropriated medical and surgical treatment, since dopamine could have worsened intestinal dilatation. In the surgeon practice of major orthopedic system and traumatologic surgery of the hip the possibility, although rare, of the onset of Ogilvie's syndrome or paralytic ileus of colon as a cause of abdominal distension and pain in the absence of evident obstructive causes should always be suspected. Early diagnosis and correct treatment (pharmacological and / or surgical) reduce high mortality rate (40%) that characterizes late diagnosed forms, often complicated by intestine ischemia or perforation .

Legenda

Fig.1 Abdomen x-ray: clearly considerable intestinal dilation
Fig.2: Transversal CT image: in evidence intestinal dilatation
Fig.3: CT enlarged image to confirm Ogilvie's Syndrome

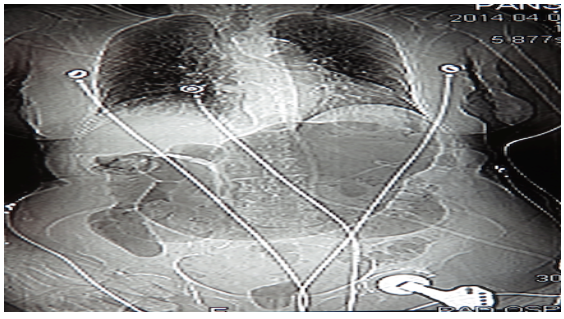

Fig.1

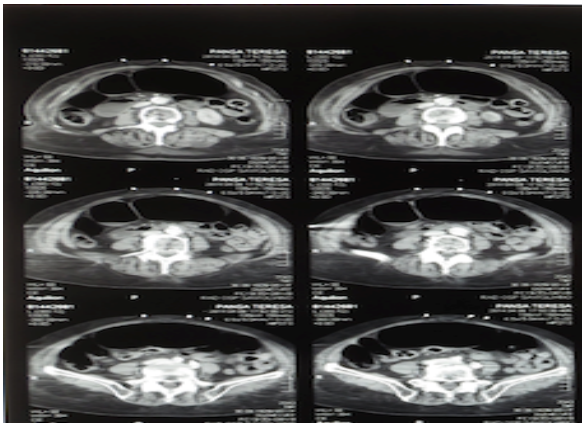

Fig.2

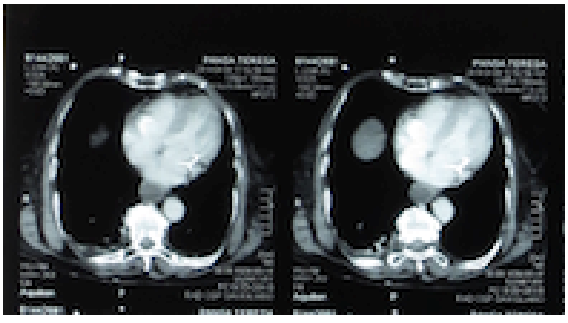

Fig.3

References

1) Ogilvie H. Large-intestine colic due to sympathetic deprivation; a new clinical syndrome.
Br Med J. 1948 Oct 9;2(4579):671-3.
2) Bernardi MP, Warrier S, Lynch AC, Heriot AG. Acute and chronic pseudo-obstruction: a current update. ANZ J Surg. 2015 Oct;85(10):709-14.
3) Saunders MD, Kimmey MB, Systematic review: acute colonic pseudo-obstruction. Aliment Pharmacol Ther 2005; 22: 917–925.
4) B. Deleanu, R. Prejbeanu, D. Vermesan, H. Haragus, I. Icma, V. Predescu Acute Abdominal Complications Following Hip Surgery. Chirurgia 2014; 109: 218-222
5) Tezval M, Sehmisch S,Dumont C. et al. Acute colonic pseudo-obstruction (Ogilvie's syndrome), a life-threatening complication after total hip replacement. Zentralbl Chitr. 2009; 134(3):263-6
6) Rex DK. Acute colonic pseudo-obstruction (Ogilvie'ssyndrome). Gastroenterologist 1994; 2: 233–8.
7) Ross SW, Oommen B, Wormer BA et al. Acute Colonic Pseudo-obstruction: defining the epidemiology, treatment and adverse outcomes of Ogilvie's syndrome. Am Surg 2016;82(2):102-111
8) Johnson CD, Rice RP. The radiographic evaluation of gross cecal distention. Am J Radiol 1985; 145: 1211–7.
9) Sloyer AF, Panella VS, Demas BE, et al. Ogilvie's syndrome.Successful management without colonoscopy. Dig Dis Sci1988; 33: 1391–6.
10) Armstrong DN, Ballantyne GH, Modlin IM. Erythromycin for reflex ileus in Ogilvie's syndrome. Lancet 1991; 337: 378.
11) Geller A, Petersen BT, Gostout CJ. Endoscopic decompression for acute colonic pseudo-obstruction. Gastrointest Endosc 1996; 44: 144–50.