ORIGINAL RESEARCH PAPER
Volume-6 | Issue-12 | December-2017 | ISSN No 2277 - 8179 | IF : 4.176 | IC Value : 93.98
INTERNATIONAL JOURNAL OF SCIENTIFIC RESEARCH

ADENOMATOID ODONTOGENIC TUMOR FOLLOWED BY PYOGENIC GRANULOMA: A CASE REPORT

Periodontology

Niyatee Varma* Senior Resident, N.S.C.B Medical College, Jabalpur, Madhya Pradesh, India
*Corresponding Author

Neeraj Agarwal Professor and Head, Department of Periodontology, Rishi Raj College of Dental Sciences, Bhopal, Madhya Pradesh, India

Bhavuk Vanza Senior Resident, Gandhi Medical College, Bhopal, Madhya Pradesh, India

ABSTRACT

Adenomatoid odontogenic tumor (AOT) is a very rare odontogenic tumor with an incidence of 1%. Overall it accounts for 9% of all odontogenic tumors. In most of the cases, AOT is misdiagnosed as an odontogenic cyst. Permanent dentition is affected more than the deciduous dentition. Intraoral periapical radiographs play a major role in the diagnosis compared to orthopantomogram because of its increased contrast. On the other hand, Pyogenic granuloma is one of the inflammatory hyperplasia seen in the oral cavity. Clinically oral pyogenic granuloma is a smooth or lobulated Exophytic lesion pedunculated or sometimes sessile base, which is usually hemorrhagic. In both the cases younger individuals are commonly affected and particularly in females because of the vascular effects of female hormones where excisional surgery is the treatment of choice for it. The purpose of the article is to describe a case of Adenomatoid Odontogenic Tumor followed by Pyogenic Granuloma.

KEYWORDS

Adenomatoid odontogenic tumor, Pyogenic granuloma, Benign neoplasm.

BACKGROUND

Adenomatoid odontogenic tumor (AOT) is a benign tumor of odontogenic origin. It was first described by Dreibaldt in 1907, as a pseudo-adenoameloblastoma and first reported by Harbitz in 1915 as a Cystic Adamantinoma. In 1971, Philpsen and Birn proposed the widely accepted and currently used name, Adenomatoid Odontogenic Tumor.[1]

It has a greater tendency to occur in anterior maxilla involving an unerupted permanent tooth, usually lateral incisor and canine and has a young female predilection. AOT usually appears as a well-defined radiolucent area, sometimes with a variable amount of radio-opacity of mineralization indicative of calcified areas within tumor tissue.[2]

AOT is also called 'two-thirds tumor,' because 2/3rd of adenomatoid tumors occur in the maxilla, 2/3rd occur in young females, two-thirds of the cases are associated with unerupted teeth, and two-thirds of the affected teeth are canines. AOT constitutes about 2.2 – 7.1% of the odontogenic tumors. The number of reported cases has increased in recent times probably due to the increased incidence of the tumor.[3]

Pyogenic granuloma is a relatively common, soft tissue tumor of oral cavity that is believed to be reactive and non-neoplastic in nature. The name pyogenic granuloma is a misnomer since the condition is not associated with pus and does not represent a granuloma histologically. Some authors use the term lobular capillary hemangioma for this lesion.

Clinically these lesions usually present as single nodule or sessile papule with smooth and lobulated surface. These may be seen in many sizes from few millimeters to several centimeters. As lesion matures, the vascularity decreases and the clinical appearance is more collagenous and pink. The peak prevalence is in teenagers, and young adults with female predilection of 2:1.

Pyogenic granuloma of the oral cavity is known to involve the gingiva commonly (75% of the cases). Uncommonly it can occur on the lips, tongue, buccal mucosa, palate and so on. This article report an unusual case of AOT which was surgically excised and later pyogenic granuloma was developed at the site of surgical of excision.[4]

CASE REPORT

A 27 year old female patient reported to the OPD of Department of Periodontics, Peoples Dental Academy, Bhopal (M.P) with a chief complaint of swollen gums on upper anterior region since six months. The patient was asymptomatic $1^{1}/_{2}$ year back. After that she noticed swelling and pus discharge from her gums in upper front tooth region. The patient visited local doctor for the same and got incision and drainage done for the swelling. After 6 months, the patient was operated for the same in that clinic which lead to extraction of the following teeth 22 and 23. (Figure 1(a) & (b). Histopathologic report of the excisional biopsy diagnosed it as AOT.

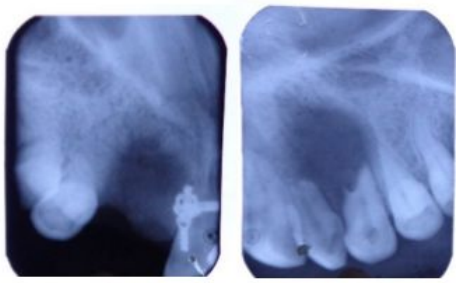

Figure 1 (a) before extraction (b) after extraction

After 6 months, she again observed a tiny, bright-red nodule in the same region which progressively increased to present size (Figure 2). There was no extraoral swelling present on the left front side of maxilla. On intraoral inspection, a solitary well defined localized growth was present in the interdental area between 22 and 23 covering more than 2/3rd of the facial aspect of the same region.



Figure 2: Present size

The growth was approximately 1x 0.5 cm in size and erythematous in color. Overlying mucosa was covered by necrotic slough. Texture seemed to be smooth and bleeding from the overlying skin was seen. On palpation, the lesion was soft in consistency, tender with pedunculated base, mobile and bled easily on provocation. The presence of lesion made it difficult for the patient to carry out the routine oral hygiene procedures leading to deterioration of the oral hygiene and thereby favoring the growth of the lesion. Width of attached gingiva was adequate. Intra-oral periapical radiograph revealed well defined unilocular radiolucency seen with respect to 22 and 23 region. Blood examination revealed normal values.

TREATMENT

Oral prophylaxis was completed and the lesion was excised under aseptic conditions using a scalpel and blade, followed by curettage (Figure.3). Sutures were placed and the patient was recalled after a week for the removal of the suture and checkup. The excised tissue was sent to the Department of Oral Pathology for histologic examination (Figure 4).

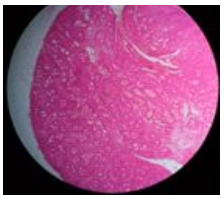

Figure 3: After excision



Figure 4: Excised tissue

Histopathologic examination revealed budding of endothelial cells along with the proliferation of fibroblasts. Parakeratinized stratified squamous epithelium overlying dense fibro cellular stroma was present. Numerous endothelial lined dilated blood vessels were also seen. Hemorrhagic areas were noted along with chronic inflammatory cells confirming the clinical diagnosis as pyogenic granuloma. (Figure 5: a & b).

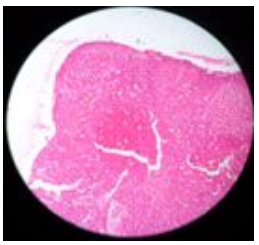

Figure 5 (a)



Figure 5 (b)

The postoperative course was favorable with no complications, and 6 months later, the patient reported no discomfort in the zone (Figure 6). At the most recent review (ten month after surgery), periapical X-ray demonstrated some radio-opacity in previous radiolucent area as suggestive of bone formation (Figure 7).



Figure 6: Six months postoperatively



Figure 7: Radio-opacity suggesting bone formation

DISCUSSION

AOT is a slowly growing lesion, with a predilection for the anterior maxilla (ratio of cases 2:1 relative to mandible) of young females. They are diagnosed in the second decade of life, and more than half occur during the teenage years. The female to male ratio for all age groups and all variants is close to 2:1 the lesions are typically asymptomatic, but growth of this type with central lesion results in cortical expansion. The involved teeth may be slightly displaced. It can cause a painless hard swelling, as in the case reported here. [10] AOT, accounting for approximately 3% of all odontogenic tumours, are less frequent than odontoma, cementoma, myxoma and ameloblastoma. It has been suggested that this tumo-r may be a hamartoma rather than a true neoplasm, but there is currently no evidence to resolve this dispute. In general, the tumor does not exceed 1-3 cm in greatest diameter.[5]

Pyogenic granuloma was first reported by Hullihens in 1844. [6] It is a kind of inflammatory hyperplasia used to describe a large range of nodular growths of the oral mucosa that histologically represents inflamed fibrous and granulation tissue. Surface is smooth lobulated, ulcerated & shows tendency for bleeding. Consistency is soft. [7] Its etiology is unknown. It was believed to be a botryomycotic infection but later suggested that it is caused by infection of streptococci & staphylococci. But now it is believed that low grade trauma or irritation, hormonal influences, viral oncogens, or certain kinds of drugs are the causative factors. Approximately one-third of the lesion occurs after trauma.[9]Poor oral hygiene may be the precipitating factor in many of these patients. Some factors such as inducible nitric oxide synthase, vascular endothelial growth factor or connective tissue growth factor are known to be involved in angiogenesis & rapid growth of pyogenic granuloma. Additionally certain drugs like cyclosporine have an important role in genesis of pyogenic granuloma.

In 1980, Davies et al found inclusion bodies in the fibroblast suggestive of disordered protein metabolism. They suggested that pyogenic granuloma constitutes a lesion produced by primitive organizer resulting from gene depression in papillary fibroblast perhaps as a result of c-type virus infection. Oral Pyogenic granuloma is the most common gingival tumor shows a striking predilection for the gingival accounting for 75% of all cases, where they are presumably caused by calculus or foreign material within the gingival crevice. Lesions are slightly more common in maxilla than in mandible; anterior gingiva is more affected than the posterior gingiva. Also the lesion is more common on facial aspect than on lingual or palatal. All the above-mentioned features were concurrent with our case.[8]

According to Vilmann et al. majority of the pyogenic granuloma are found on the marginal gingiva with only 15% on the alveolar part. The size varies in diameter from a few millimeters to several centimeters. Rarely does pyogenic granuloma exceed 2.5 cm in size & usually reaches its full size within weeks or months. Young Pyogenic granulomas are highly vascular in appearance because they are composed predominantly of hyperplastic granulation tissue in which capillaries are prominent. Whereas older lesions tends to become more collagenized & pink. Involvement of bone in pyogenic granuloma is rare, but was seen on our case. Treatment of pyogenic granuloma involves a complete surgical excision. Recurrence of pyogenic granuloma after excision is a known complication but can be prevented. Recurrence rate for pyogenic granuloma is said to be 16 % of the treated lesions and so re excision of such lesions may be necessary. Various other benign soft tissue lesions need to be differentiated from pyogenic granuloma. Few to name include peripheral giant cell granuloma, pregnancy tumor; conventional granulation tissue etc. Differentiation is done on clinical and histological features which help in adequate treatment and good prognosis.[6]

CONCLUSION

Pyogenic granuloma is benign in nature and usually do not attain unusually large size. Considering these characteristics, pyogenic granuloma can be adequately treated with correct diagnosis and proper treatment. A careful management of the lesion also helps prevent the recurrence of this benign lesion.

REFERENCE

1. Sushma P, Sowbhagya MB, Balaji P, Poornima C. Adenomatoid Odontogenic Tumor: A Case Report. IJSS Case Reports & Reviews 2015; 1(12):36-39.
2. Mhaske S, Moghe S, Yuwanati M, Bhatnagar N, Rawal M. An aggressive presentation of adenomatoid odontogenic tumor associated with calcifying epithelial odontogenic tumor: A hybrid variant. J Oral Res Rev 2015; 7:50-4.
3. Singh V, Bhaskar DJ, Agali C, Kishore M, Kadtane SS, Singh H. Adenomatoid Odontogenic tumour: Report of a Case and Review of Literature. International Journal of Scientifi c Study. 2014; 1(4):63-66.
4. Amrichaghmaghi M, Falaki F, Mohtasham N, Mozafari PM. Extragingival pyogenic granuloma: a case report. Biomed central Cases J 2008, 1:37(1):1-3.
5. Rashmi G, Santosh G, Harshavardhan S, Praveen KM. Adenomatoid Odontogenic Tumour. IJDA, 1(1), 2009:67-71.
6. Saikhedkar R, Shrivastava S, Melkundi M, Viswanathan V. Pyogenic granuloma – A Case Report. International Journal of Dental Clinics 2011:3(3):87-88.
7. Kurian B, Sasirekha, Ebenezer. Pyogenic Granuloma- a Case Report and Review. International Journal of Dental Sciences and Research 2014:2(3):66-68.
8. Sharma P, Khan MH, Kumar N, Samadi FM. Pyogenic Granuloma: A Case Report. Journal of dentofacial sciences 2013; 2(4): 9-11.
9. Chavda M, Lagdive SS, Sharma S. Oral pyogenic granuloma-a case report. Indian Journal of Basic and Applied Medical Research; December 2014: Vol.-4, Issue- 1, P. 375-379.
10. Baskaran P, Misra S, Kumar MS, Mithra R. Adenomatoid Odontogenic Tumor–A Report of Two Cases with Histopathology Correlation. J Clin Imaging Sci 2011:1:64.