ORIGINAL RESEARCH PAPER

Volume-7 | Issue-12 | December-2018 | PRINT ISSN No 2277 - 8179

INTERNATIONAL JOURNAL OF SCIENTIFIC RESEARCH

ADVANTAGE OF MAGNIFYING NARROW BAND IMAGING (NBI) ENDOSCOPY OVER CONVENTIONAL WHITE LIGHT ENDOSCOPY IN THE DIAGNOSIS OF HELICOBACTER PYLORI RELATED CHRONIC GASTRITIS.

General Surgery

Dr. Rahul B. Kadam Post Graduate student, Department Of General Surgery, Dr.D.Y.Patil Medical College and Hospital, Kolhapur

Dr. Abhay D. Chougale* Professor, Department Of General Surgery, Dr.D.Y.Patil Medical College and Hospital, Kolhapur. *Corresponding Author

Dr. Aniket Patil Assistant Professor, Department Of General Surgery, Dr.D.Y.Patil Medical College and Hospital, Kolhapur.

Dr. Abhinandan Kadiyal Assistant Professor, Department Of General Surgery, Dr.D.Y.Patil Medical College and Hospital, Kolhapur.

ABSTRACT

Helicobacter pylori is a vital human pathogen involved as a causative organism in chronic gastritis [1]. Peptic ulceration is a common complication of this infection. Several study shows direct association between H. pylori and gastric carcinoma. The upper Gastrointestinal Endoscopy is investigation of choice for the screening and diagnosis of Helicobacter pylori related chronic gastritis. As field of endoscopy is getting advanced some new techniques like NBI (Narrow Band Imaging) are developed. Due to better visualization of Subendothelial Capillary Network (SECN) by using lights of two different wavelengths NBI method it is more useful in visualization of affected area of gastric mucosa [2]. Total 100 cases of chronic gastritis were diagnosed using upper G.I .Scopy, Biopsies were taken using both NBI and WLE and results were compared using Rapid Urease kit. Narrow band imaging was found more effective than conventional white light endoscopy in the diagnosis of H. Pylori related chronic gastritis [3].

KEYWORDS

INTRODUCTION

Helicobacter pylori is a vital human pathogen involved as a causative organism for atrophic gastritis, gastro-duodenal ulcer, gastric cancer, MALT lymphoma, vitaminB12deficiency, idiopathic. thromboc ytopenic purpura, iron.deficiency anaemia [1]. The basic lesion of H.Pylori is progressive mucosal inflammation which may cause preneoplastic atrophic changes. The upper Gastrointestinal Endoscopy is investigation of choice for the screening and diagnosis of Helicobacter pylori related chronic gastritis. As the field of endoscopy is getting more and more advanced technologically the new techniques like narrow band imaging (NBI) are developed. The Narrow Band Imaging (NBI)system comprised of a sequential electronic endoscope system and light source which has narrow band filters, which helps in displaying distinct images of microvessels on mucosal surfaces [4]. Lights of specific blue and green wavelength are used to identify the detail of certain aspects of the surface of the mucosa. Switch in the endoscope activates a special filter leading to the use of ambient light of wavelengths of 415 nm (blue) and 540 nm(green) [5]. The maximum light absorption of haemoglobin occurs at these two wavelengths, blood vessels will appear very dark, allowing for their enhanced visibility of subendothelial capillary network (SECN) and in the accurate identification of other surface structures [6].

Helicobacter pylori is uraese producing organism [7]. Urease hydrolyzes the urea to produce ammonia and carbon dioxide [8]. The rapid urease test requires a sample of gastric mucosa or mucus that is added to a tube, gel, or other device which brings that sample into contact with urea and a method to detect the products of urea hydrolysis, ammonia or carbon dioxide [9]. The initial test used phenol red in which the colour indicator which turns pink from yellow as the pH increases. Other tests have used different indicators each with a potential advantage such as being able to start the reaction at a lower pH such as5.4 and thus reduce the activity of contaminating mouth bacteria many of which also contain abundant urease [10].

MATERIALS AND METHODS

The study is intended in Dr. D.Y.PATIL HOSPITAL AND RESEARCH INSTITUTE, Kolhapur under D.Y.PATIL UNIVERSITY, Kolhapur. A prospective cross sectional study of 100 patients male/female attending the outpatients department with signs and symptoms of chronic gastritis at the department of General surgery Dr D.Y.PATIL HOSPITAL AND RESEARCH INSTITUTE, Kolhapur

INCLUSION CRITERIA

1.Male/Female.

C/o 1. upper abdominal pain
2.indigestion
3.bloating
4.nausea
5. Loss of appetite.
6.Vomiting

EXCLUSION CRITERIA

- Patients who were not willing for any procedure or any invasive investigations.
- Patient who are not fit for procedure .
- Children (0-14 yrs)
- Pregnant women.
- Patient who are on Steroids/ Chemotherapy/Long term antibiotics/ NSAIDS
- Patients who are having symptoms suggestive of gastritis for less than 1 month (acute Gastritis).

- Total 100 patients were studied at D.Y. Patil Hospital Surgical Gastroenterology unit. Both IPD and OPD patients were studied.
- Upper G.I. Endoscopy was performed in patients after written, valid and informed consent .
- Two biopsies were taken from the stomach of each patients one using the conventional white light endoscopy and one using Narrow band Imaging .and where subcapsular endothelial capillary network (SECN) is more prominent.
- Biopsies were taken from the area which was red, inflamed and oedematous
- Both samples were tested with Rapid Urease Kit and results were compared after 15-20 Minutes , when the indicators colour turn pink from yellow it was considered as positive for H. Pylori. And when the yellow colour remained unchanged it considered as negative for H. Pylori Infection.
- The test considered to be false Positive if the indicator turn pink after 30 minutes, and patient advised check endoscopy after 1 month if symptoms still persist.

The test considered false negative with patients which had taken inadequate treatment and which were on long term PPI treatment , patient advised to stop PPI for 7 days and do a check endoscopy with biopsy for rapid urease test (RUT)

- White light imaging
- Narrow-Band imaging

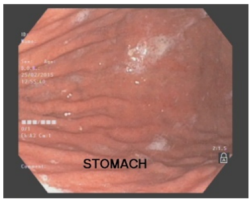

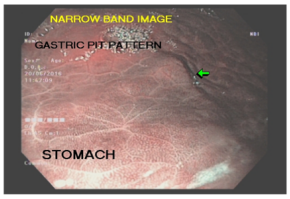

Chronic gastritis

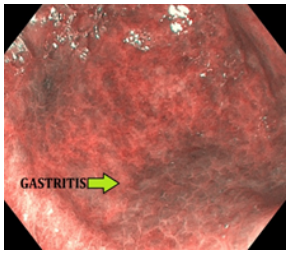

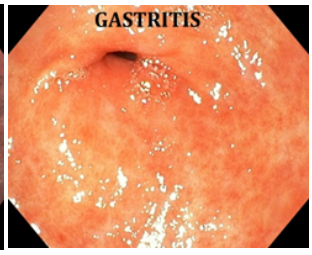

Narrow band Imaging **White Light Endoscopy**

Results : Graph No.1

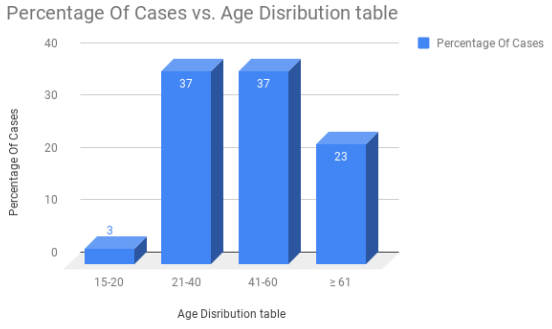

Table No.1

II / I	White Light + ve	White Light - Ve	Total Cases
NBI +ve	25	69	94
NBI - ve	6	0	6
Total Cases	31	69	100

Graph No.2

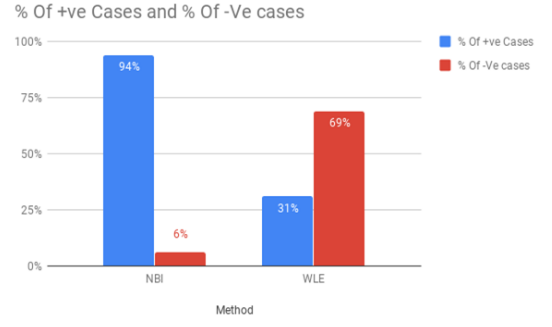

Discussion

- As Shown in Graph No.1 Out of total 100 patient of chronic gastritis 3 patients were between the age of 15-20, 37 patients were between the age of 21-40, 37 patients were between the age of 41-60 and 23 patients were above and equal to 61 yrs of age.

So there is no specific correlation found between age group and H.Pylori infection but it has slight preponderance towards the age group 20-60 yrs.This is consistent with study by Dr. Puneet Kumar Agarwal [11].

- As shown in Table no.1 and Graph No. 2 Out of 100 samples 69 samples were positive using Narrow Band Imaging Only and for these 69 patients Samples taken using white light endoscopy were Negative For H. Pylori.
- 6 cases where Samples were positive for biopsy was taken using white light endoscopy and for these 6 cases samples taken using narrow band imaging were Negative for H. Pylori.
- Out of 100 cases 25 cases in which sample is positive for biopsies taken using Narrow Band Imaging as well as White Light Endoscopy.
- the number of cases diagnosed by NBI is 94 that is 94% of total cases and total number of cases diagnosed by WLE is 31 that is 31% of total cases.
- Out of 100 cases 6 cases that is 6% were missed by NBI and 69 cases that is 69 % were missed by WLE.

CONCLUSION

In this study chronic gastritis is predominant in males than females. The mean age for this infection is 21-60yrs. Out of all symptoms abdominal pain was found to be the main symptom. 87% of patients were having mild to moderate pain and only 13 % of patients were having severe pain. Out of total cases Out of 100 cases studied 94 cases were diagnosed by Narrow Band Imaging and 31 cases were diagnosed by White Light Endoscopy. Only 6 cases were missed by Narrow Band Imaging and 69 cases were missed by White Light Endoscopy.

So in this study Narrow Band Imaging (NBI) was found useful and superior than the conventional White Light Endoscopy (WLE) in the diagnosis of Helicobacter pylori related chronic gastritis.

REFERENCES

1. Shiotani A, Cen P, Graham DY. Eradication of gastric cancer is now both possible and practical. Semin Cancer Biol 2013;23:492-501
2. Digestion. 2011;83(3):161-6. doi: 10.1159/000321799. Epub 2011 Jan . Usefulness of Magnifying Narrow-Band Imaging Endoscopy in the Helicobacter pylori-Related Chronic Gastritis
3. Diagnosis of Helicobacter pylori using the rapid urease test Takahiro Uotani, David Y. GrahamDepartment of Medicine, Michael E. DeBakey VA Medical Center and Baylor College of Medicine, Houston, TX 77030, USA
4. Sambongi M, Igarashi M, Obi T et al. Analysis of spectral reflectance of mucous membrane for endoscopic diagnosis. Med Phys 2000; 27: 1396
5. Asaka M, Kato M, Sakamoto N. Roadmap to eliminate gastric cancer with Helicobacter pylori eradication and consecutive surveillance in Japan. J Gastroenterol 2014;49:1-8.
6. El-Omar E, Penman I, Dorrian CA, et al. Eradicating Helicobacter pylori infection lowers gastrin mediated acid secretion by two thirds in patients with duodenal ulcer. Gut. 1993;34:1060–1065.
7. Graham DY, Go MF, Evans DJ Jr. Review article: urease, gastric ammonium/ammonia, and Helicobacter pylori--the past, the present, and recommendations for future research. Aliment Pharmacol Ther 1992;6:659-69.
8. McNulty CA, Wise R. Rapid diagnosis of Campylobacter-associated gastritis. Lancet 1985;1:1443-4.
9. Yao K. Gastric microvascular architecture as visualized by magnifying endoscopy: body and antrum without pathologic change demonstrate two different patterns of microvascular architecture. Gastrointest En− dosc 2004; 59: 596M597
10. Hazell SL, Borody TJ, Gal A, et al. Campylobacter pyloridis gastritis I: Detection of urease as a marker of bacterial colonization and gastritis. Am J Gastroenterol 1987;82:292-6.
11. Puneet Kumar Agarwal1, Mayank Badkur1, Richa Agarwal1, Seema Patel21Department of General Surgery, AIIMS, 2Department of Community Medicine, GMC, Bhopal, Madhya Pradesh, India.