VOLUME-6 | ISSUE-2 | FEBRUARY-2017 • ISSN No 2277 - 8179 | IF : 3.508 | IC Value : 78.46

Aggressive Angiomyxoma Of Cervix: A Case Report And Review Of Literature

Oncology

KEYWORDS: Aggressive angiomyxoma, cervix, soft tissue tumors, myxoid tumors

Yumkhaibam Sobita Devi	Department of Radiotherapy, Regional Institute of Medical Sciences, Imphal
Shoibam Subhaschandra	Department of Radiology, Regional Institute of Medical Sciences, Imphal
Nithin Raj D	Department of Pathology, Regional Institute of Medical Sciences,Imphal
Dulasiraman Ponnas	
Himadri Kr Daru	
L. Jaichand Singh	
Babina Sorokhaibam	

ABSTRACT

Background: Aggressive angiomyxoma is a distinct soft tissue tumor of the pelvis and perineum of adult women with a high risk of local recurrence. **Case:** A case of an aggressive angiomyxoma of cervix in a 73 year old lady is reported. The tumour was 4x4cm in size. Histologically, stellate and spindle cells were embedded in loosely collagenised matrix with scattered vessels. **Conclusion:** Aggressive angiomyxoma of the cervix must be distinguished from other benign and malignant myxoid tumours including myxoma, myxoid liposarcoma and other soft tissue tumors with secondary myxoid changes.

Introduction

Aggressive angiomyxoma is a rare locally invasive soft tissue tumour arising from the perineum. First reported by Steeper and Rosai in 1983, it is usually asymptomatic and presents as a mass in the perineum [1]. Aggressive angiomyxoma is thought to be estrogen progesterone sensitive and occurs usually in the reproductive age group with peak incidence during the third decade of life [2]. This mesenchymal tumor arises from connective tissue of lower pelvis or perineum and has a locally aggressive course[3]. The female to male ratio is 6:1. In women, vulval region is the most common site of involvement[3]. Here, we present a case with an uncommon origin of this rare tumour.

Case Report

A 73 year old gravid 4 para 4, post menopausal female hailing from Wangoo village of Thoubal district, Manipur came to Radiotherapy OPD with complaints of difficulty in initiation of micturition, strained micturition and the feeling of incomplete voiding of urine since 2 months. The symptoms have been insidious in onset and gradually progressive. There is no local swelling in perineum or discharge per vaginum. There is no associated abdominal pain. There is associated loss of appetite and weight since past 2 months.

She attained menopause at the age of 50 years and had regular menstrual cycles prior to menopause and no history of post menopausal bleeding. She got married at 18 years. First child birth was at 20 years and last child birth, at 28 years of age.

She is a non smoker, no alcoholic who occasionally chews tobacco with betel nut. No past history of any medical illness or surgical intervention.

On per vaginum examination, a cervical mass approximately 4 cm x 4 cm with extension to lateral pelvic wall with urinary bladder and rectal involvement (Fig 1). It is non tender and does not bleed on touch.

CECT abdomen and pelvis showed ill defined soft tissue mass lesion with marked contrast enhancement measuring 8 cm x 5 cm in axial dimension and 4 cm craniocaudally in pelvic cavity arising from cervix (Fig.2). Fat plane between the lesion, urinary bladder, rectum is lost. Lesion is extending to lateral pelvic wall bilaterally. Vagina is not well defined. Ovaries were not visualised. An 18 mm pelvic node is present. There is hydroureteronephrosis of left kidney.

Biopsy taken from the mass showed ectocervical tissue with subepithelium displaying slit like vessels with scattered stellate cells in myxoid stromal background. Mild mixed inflammatory cell infiltration is seen. Deeper areas show bundles of smooth muscles. Features show angiomyxoma, aggressive type (Fig. 3). Further studies were not possible due to lack of biopsy material and lack of consent from patient.

Other blood reports were within normal limits.

Discussion and Review of Literature

There are two types of angiomyxoma: Superficial angiomyxoma and aggressive. Superficial angiomyxoma is most likely to grow on the outside surface of the trunk and lower part of the body, the genitals (penis and vagina), and head and neck. The same number of men and women develop superficial angiomyxoma. It occurs most commonly in people between the ages of 40 and 60. Aggressive angiomyxoma tends to grow deeper into the tissue. They can also grow into the tissues around them. But they are very unlikely to spread to other parts of the body. It mostly develops between the legs or in the pelvis. More than 9 out of 10 people (95%) diagnosed with the aggressive type are women. Sites of involvement are pelvicoperineal, inguinoscrotal, and retroperitoneal regions.

Clinical features: Most patients with deep 'aggressive' angiomyxoma present with a slow-growing mass in the pelvicoperineal region that is either asymptomatic or associated with regional pain, dyspareunia, or a pressure-like sensation [4]. Aggressive angiomyxoma is a rare mesenchymal tumour that presents to the gynecologists as a growth/ mass arising from the vulva or perineum; mistaken as a lipoma, bartholin, gartner's cyst or labial mass and has no typical symptoms [2,3]. Patients are often asymptomatic and compression to urinary/intestinal systems occurs only when the tumour is large. Aggressive angiomyxoma is thought to be estrogen and progesterone sensitive and presents usually in the reproductive

age group, with some cases reporting growth of the tumour during pregnancy [2]. Because the bulk of the tumour is often concealed within the deep soft tissues and the process generally does not cause rectal, urethral, vaginal, or vascular obstruction, the majority of examples are quite large at the time of resection.

Common age of presentation is in reproductive age group but our patient presented in post menopausal age group. Most cases in the literature has mentioned that cases of angiomyxoma has a late stage presentation. Our patient too presented in a late stage. The mass was arising from cervix with lateral pelvic wall involvement along with bladder and rectal infiltration.

CT demonstrates a hypoattenuating or isoattenuating mass that tends to grow around pelvic floor structures, usually without causing significant disruption of the vaginal or rectal musculature. A high signal intensity is noted with T2-weighted MR images. Both T2-weighted MR and enhanced CT images also frequently demonstrate a swirled or layered internal structure [5].

An accurate diagnosis of aggressive angiomyxoma is based on histopathology evidence. Gross examination usually reveals a large mass, often greater than 10 cm and sometimes larger than 20 cm [1,4]. Small tumours under 5 cm in size are less frequent. The lesions frequently have a lobular contour with adherence to fat, muscle, and other regional structures. A soft, firm, or rubbery consistency may be present, and a glistening, myxooedematous, pink or reddish-tan cut surface is usually evident. Cystic change has occasionally been noted. Histopathology: The tumours are of low to moderate cellularity and are composed of relatively uniform, small, stellate and spindled cells, set in a loosely collagenous, myxoedematous matrix with scattered vessels of varying caliber and entrapped regional structures. The tumour cells have scant, pale, eosinophilic cytoplasm with poorly defined borders and relatively bland nuclei with an open chromatin pattern and a single, small, centrally located nucleolus. Multinucleated cells may rarely be observed. Mitotic figures are infrequent. A characteristic finding that is seen in most cases is the presence of loosely organized islands of well developed myoid (myofibroblastic or true smooth muscle) cells around the larger nerve segments and vessels. Although the tumour name implies abundant myxoid matrix, these neoplasms are usually only weakly positive for mucosubstances, a finding that suggests oedema fluid is a major component of the noncollagenous stroma. Immunophenotype The tumour cells of deep 'aggressive' angiomyxoma usually show diffuse immunoreactive for vimentin, moderate to diffuse (nuclear) immunoreactivity for oestrogen and progesterone receptor protein, and variable levels of immunoreactivity for actins and CD34 [4,6,7]. Desmin positivity can be identified in almost all cases. Immunoreactivity for S100 protein is absent. Ultrastructure Ultrastructural evaluation has revealed cells with fibroblastic, myofibroblastic, and smooth muscle features [1, 8, 9]. The tumour is usually positive for vimentin, desmin and negative for S-100 on imomunohistochemistry [8]. However, this immunoprofile is shared by superficial cervicovaginal myofibroblastoma [9]. Sparse cellularity, more infiltrative pattern and variability in distribution, size and wall thickness of vessels favour aggressive angiomyxoma.

Genetics Cytogenetic studies have revealed clonal chromosome abnormalities in five cases of deep 'aggressive' angiomyxoma, all affecting the female genital tract[10, 11]. Four tumours had abnormalities involving chromosome 12, including one case with monosomy 12 and three cases with structural rearrangements of 12q13-15. Molecular analyses of two of the cases with rearrangement of 12q13-15 identified HMGIC (a.k.a. HMGA2) as the target gene [10, 11]. In one case the rearrangement resulted in a fusion gene in which the first three exons of HMGIC were fused to ectopic sequences derived from a novel gene in 12p11.2 and in the other case the translocation breakpoint was located 3' of the gene leading to deregulation of HMGIC expression. Prognostic factors Deep 'aggressive' angiomyxoma has a local recurrence rate of approximately 30% [1, 2, 4, 6, 8], and such recurrences are usually controlled by a single re-excision. Thus, these tumours are less aggressive than was originally believed. These lesions have no metastatic potential.

Pathologically, aggressive angiomyxoma needs to be differentiated from angiomyofibroblastoma (AMF), myxoid leiomyoma, cellular angiofibroma, superficial myofibroblastoma, myxoid liposarcoma and other differentials that may mimic aggressive angiomyxoma and differ in the management, thus emphasizing the need for pre-operative diagnosis [12, 13]. Prior to definitive management, a pre-operative fine needle aspiration (FNA) may help exclude lymphoproliferative and metastatic pathologies [13]. Radiological assessment of extent of lesion using radiological modalities like ultrasound, computerized tomography (CT) and MRI should be considered to help plan surgery [12,14]. On CT, it is seen as a well-defined mass, hypodense as compared to the muscle. AAM is seen as a hypointense lesion on T1 weighted MRI images and hyperintense lesion on T2 weighted images [11].

Angiomyxoma is thought to displace rather than invade surrounding tissue. In the usual case of AAM presenting as a perineal mass, careful anatomic dissection should be done to avoid injury to anal sphincters and lower urinary system that may be in close proximity in an AAM [2,4].

Since our patient did not turn up for further management and the collected biopsy sample was inadequate, further marker and receptor studies couldn't be done.

Complete surgical excision is the gold standard, because of its tendency to recur locally. The recurrence rate is varies from 36-70%. There is no correlation between size of tumour and recurrence rate[2]. Surgery causes significant morbidity due to its frequent occurrence in lower pelvis and perineum with proximity to genitourinary and anorectal structures [16]. Most surgeons aim at complete resection (wide excision with tumour free margin), incomplete or partial resection is acceptable when high operative morbidity is anticipated and fertility is an issue [2]. Treatment with GnRH agonists in oestrogen and progesterone receptors positive tumours obviates repeat surgery for recurrence [17]. Radiation therapy also reduces such recurrences. In case of a cervical or uterine polyp, the complete removal of the polyp and the pedicle should be done to ensure disease free margins, which should be confirmed by histopathology, as in our case. Other therapeutic options could be used to preserve fertility. These include hormonal treatment with gonadotropin releasing hormone (GnRH) agonists or tamoxifen [3,14,21]. Leuprolide acetate administered intramuscularly in monthly doses of 3.75 mg has been used [18]. Tamoxifen has also been used in the treatment of aggressive angiomyxoma due to its antiestrogenic action [15]. These agents may help in reducing the extent of surgery by reducing the size of the tumour [14]. Even though radiotherapy and chemotherapy may seem to be less useful due to the low mitotic activity and low cellularity of the tumour, various reports have documented reduced recurrence with their use [12,19]. The presence of multiple feeding vessels also limits the use of embolization as a treatment modality [14]. Individualization of the treatment options and multimodal treatment seem to be the most appropriate [20,22].

AAM has high recurrence (36-72%), is locally invasive and few metastasis have been reported [2,3,14,15]. However, the chances of local recurrence are similar with complete tumour free margins and without [2,14]. Follow up assessment of treatment response should include clinical examination and CT/ MRI [2].

Our treatment plan was to conduct receptor and marker studies for confirmation and then go for surgery if feasible.

CONCLUSION

Angiomyxoma especially aggressive type should be kept as a

VOLUME-6 | ISSUE-2 | FEBRUARY-2017 • ISSN No 2277 - 8179 | IF : 3.508 | IC Value : 78.46

differential diagnosis of a cervical polyp. Treatment options include surgical resection and hormonal therapy like GnRH agonists and tamoxifen. In case of a recurrence, we may go for local resection or hysterectomy. Long term follow up is recommended.



Figure 1. Per speculum examination picture of the patient showing the cervical mass

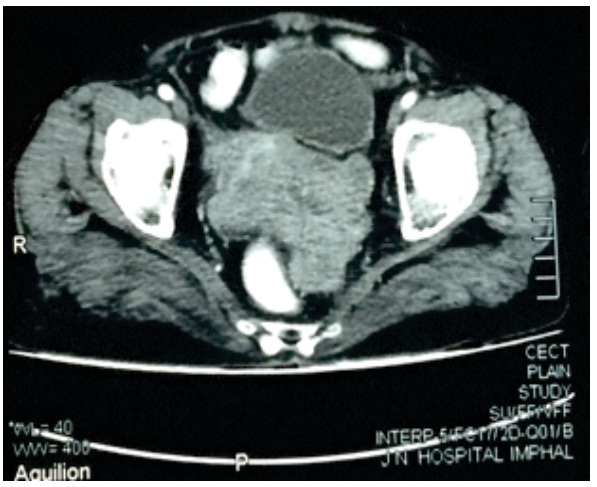

Figure 2. CT scan of pelvis showing cervical mass

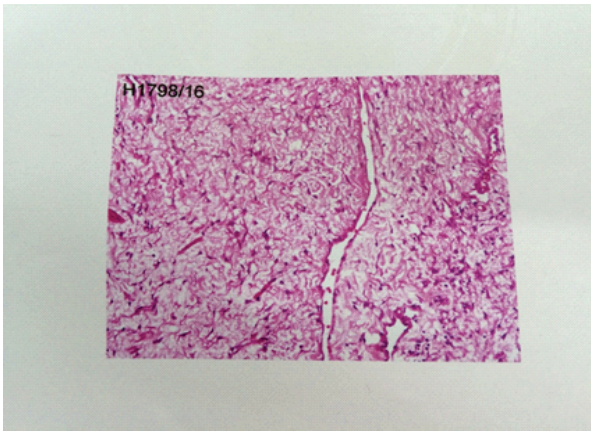

Figure 3. Microscopic Picture of the tumor

REFERENCES

1. Steeper TA, Rosai J. Aggressive angiomyxoma of the female pelvis and perineum. Report of nine cases of a distinctive type of gynecologic soft-tissue neoplasm. Am J Surg Pathol 1983;7(5):463-75.
2. Chan YM, Hon E, Ngai SW, Ng TY, Wong LC. Aggressive angiomyxoma in females: is radical resection the only option? Acta Obstet Gynecol Scand 2000;79(3): 216-20.
3. Abdul-Karim KW, Chang AE, Fletcher JA, Folpe AL, Geisinger KR, Gown AM, et al. Benign soft tissue tumors and pseudotumors of miscellaneous type. In: Weiss SW, Goldblum JR, editors. Enzinger and Weiss's Soft tissue tumors 2001;4:1419-81.
4. Fetsch JF, Laskin WB, Lefkowitz M, Kindblom LG, Meis-Kindblom JM.Aggressive angiomyxoma: a clinicopathologic study of 29 female patients. Cancer 1996; 78(1): 79-90.
5. Outwater EK, Marchetto BE, Wagner BJ, Siegelman ES. Aggressive angiomyxoma: findings on CT and MR imaging. AJR Am J Roentgenol 1999;172: 435-8.
6. Granter SR, Nucci MR, Fletcher CD. Aggressive angiomyxoma: reappraisal of its relationship to angiomyofibroblastoma in a series of 16 cases.Histopathology 1997; 30:3-10
7. McCluggage WG, Patterson A, Maxwell P. Aggressive angiomyxoma of pelvic parts exhibits oestrogen and progesterone receptor positivity. J Clin Pathol 2000; 53: 603-5.
8. Begin LR, Clement PB, Kirk ME, Jothy S, McCaughey WT, Ferenczy A. Aggressive angiomyxoma of pelvic soft parts: a clinicopathologic study of nine cases Hum Pathol 1985; 16: 621-8
9. Skalova A, Michal M, Husek K, Zamecnik M, Leivo I. Aggressive angiomyxoma of the pelvioperineal region. Immunohistological and ultrastructural study of seven cases. Am J Dermatopathol 15: 446-451. cases. Hum Pathol 1993; 16: 621-8
10. Kazmierczak B, Dal Cin P, Wanschura S, Bartnitzke S, van den, Berghe H, Bullerdiek J. Cloning and molecular characterization of part of a new gene fused to HMGIC in mesenchymaltumors. Am J Pathol 1998;152: 431-5.
11. Nucci MR, Weremowicz S, Neskey DM, Sornberger K, Tallini G, Morton CC, Quade BJ. Chromosomal translocation t(8;12) induces aberrant HMGIC expression in aggressive angiomyxoma of the vulva. Genes Chromosomes Cancer 2001;32: 172-6.
12. Bagga R, Keepanasseril A, Suri V, Nijhawan R. Aggressive angiomyxoma of the vulva in pregnancy: a case report and review of management options. Med Gen Med 2001; 9:16.
13. Layfield LJ, Dodd LG. Fine-needle aspiration cytology findings in a case of aggressive angiomyxoma: a case report and review of the literature. Diagn Cytopathol 1997;16: 425-9
14. Haldar K, Martinek IE, Kehoe S. Aggressive angiomyxoma: a case series and literature review. Eur J Surg Oncol 2010;36: 335-9.
15. Tsarpalis DC, Giannakopoulos CK, Lagadas AA, Toufexi EG. Aggressive angiomyxoma: case report and review of the literature. Eur J Gynaecol Oncol 2007; 28: 480-2.
16. Behrnwala KA, Thomas JM. Aggressive angiomyxoma: A distinct clinical entity. Eur J Surg Onco 2003; 29: 559-63.
17. Shinora N, Nonomura K, Ishikawa S, Seki H, Koyanagi T. Medical management of recurrent aggressive angiomyxoma with gonadotrophine releasing hormone agonist. Int J Urol 2004; 11:432-5.
18. Poirier M, Fraser R, Meterissian S. Case 1. Aggressive angiomyxoma of the pelvis: response to luteinizing hormone-releasing hormone agonist. J Clin Oncol 2003; 21: 3535-6.
19. Rhomberg W, Jasarevic Z, Alton R, Kompatscher P, Beer G, et al. Aggressive angiomyxoma: irradiation for recurrent disease. Strahlenther Onkol 2000;176: 324-6.
20. Coppola S, Desai A, Tzanis D, Honoré C, Bitsakou G, et al. Conservative en bloc surgery for aggressive angiomyxoma achieves good local control: analysis of 14 patients from a single institution. Int J Gynecol Cancer 2013;23: 540-5.
21. Lee CW, Yoon JH, Park DC, Lee SJ. Aggressive angiomyxoma of the vulva treated by using a gonadotropin-releasing hormone agonist: a case report. Eur J Gynaecol Oncol 2011; 32: 686-8.
22. Bai HM, Yang JX, Huang HF, Cao DY, Chen J, et al. Individualized managing strategies of aggressive angiomyxoma of female genital tract and pelvis. Eur J Surg Oncol 2013; 39: 1101-8.
23. Zhang P, Song K, Li L, Geng F, Li J, et al. Aggressive angiomyxoma with massive ascites. Gynecol Oncol Case Rep 2011;1: 12-3.
24. Laskin WB, Fetsch JF, Tavassoli FA.Superficial cervicovaginal myofibroblastoma: fourteen cases of a distinctive mesenchymal tumor arising from the specialized subepithelial stroma of the lower female genital tract. Hum Pathol 2001;32: 715-25.