ORIGINAL RESEARCH PAPER
VOLUME-6 | ISSUE-6 | JUNE-2017 | ISSN No 2277 - 8179 | IF : 4.176 | IC Value : 78.46
INTERNATIONAL JOURNAL OF SCIENTIFIC RESEARCH

An outbreak of Tungiasis in United Nations Peacekeepers deployed in Democratic Republic of Congo

Community Medicine

Dr Vishal Sharma MD Specialist Dermatology, Command Hosp, Udhampur
Dr Umesh Kapoor MD, Specialist Pathology, Indian Level III Hospital, Dem Rep of Congo, Africa
Dr Alok Gupta MD Specialist PSM, SHO(L), Garhi Cantt, Dehradun
Dr Balbir S Deswal Professor& Head, Dept of Community Medicine SGT Medical College, Gurgaon-122505
Dr S Syed Specialist (PSM) , CTC Pune

ABSTRACT

Background: Tungiasis is an uncommon parasitic skin disease which has been included in Neglected Parasitic Diseases (NPDs) by the World Health Organization (WHO). This ectoparasitosis is endemic in Sub-Saharan Africa & Latin America and is caused by sand flea Tunga penetrans (also known as jigger flea). Though usually found in people living in extreme poverty, we came across a sudden outbreak of Tungiasis in United Nations (UN) Peacekeepers deployed in Eastern Democratic Republic of Congo (DRC).

Methods: This descriptive study comprised of 45 cases of Tungiasis in UN soldiers who presented over a period of ten days from 23 May 2012 to 06 Jun 2012 following deployment in a remote village of DRC.

Result: All cases were detected in UN soldiers camped near Buleusa village in North Kivu Province of Eastern DRC during peacekeeping operations. A thorough epidemiological investigation was undertaken by the authors and the region was found to be endemic for Tungiasis. The affected soldiers were successfully treated for Tungiasis with removal of the adult worms, chemical cauterization of infected site with 70% Trichloracetic acid (TCA), oral Ivermectin and Albendazole.

Conclusion: All troops being deployed in the region need to be made aware of this condition prior to induction so that preventive measures can be initiated in order to reduce the associated morbidity.

KEYWORDS:

Tunga penetrans; ectoparasite; tungiasis; sand flea; jigger

INTRODUCTION

Tungiasis is an ecto-parasitic disease caused by sand flea "Tunga penetrans" commonly known as "Jigger flea".[1] A number of cases of tungiasis have been reported in literature among travellers and military contingents deployed or returning from endemic areas[2-4] We report an outbreak of tungiasis which occurred in 45 United Nations (UN) peacekeepers who were deployed in the remote jungles of Eastern Democratic Republic of Congo (DRC) between 23 May 2012 and 06 Jun 2012. The soldiers were camped in a small clearing of about 30 x 40 metres at the periphery of the village for a week. On the third day of deployment, the index case reported with blistering in both feet which was associated with burning sensation and mild pain. Over the next 8 days, 44 (58.7%) more soldiers reported similar lesions on their feet. During the drainage of the lesions, few black coloured particles were noticed and hence the possibility of an arthropod borne dermatoses was explored. The dermatological examination revealed pustules on both dorsum and plantar aspects of both the feet at the interdigital space and periungual areas. All the 45 (60%) affected soldiers were managed at the deployed area itself with local incision & drainage, chemical cauterization with TCA & oral antibiotics and none were admitted to the hospital. The event was investigated with the purpose of characterising the outbreak in terms of time, place and person, besides identifying the source of illness, isolating the causative agent and recommending measures for future prevention.

MATERIALAND METHODS

The study population comprised of a group of 75 UN Indian soldiers who were deployed for routine peacekeeping mission near village Buleusa located deep in the jungles of Eastern DRC on 21 May 2012. The following case defining criteria were used:

(a) **Fresh cases**: A 'fresh case' of the outbreak was defined as any person who had developed pain with burning sensations or skin lesions on the feet after at least four days of having moved bare feet in the deployed region.

(b) **Secondary cases**: All cases who presented with above mentioned signs & symptoms and again had additional similar lesions (fresh crop) in other areas of the feet.

(c) **Recurrent cases**: All cases who presented with above mentioned signs & symptoms and after healing of initial lesions again developed additional similar lesions.

Historical data pertaining to the outbreak was collected using an epidemiological case sheet containing relevant details of personal information, time of onset and presenting of symptoms, medical care provided and time required for recovery. Statistical analysis was carried out - risk ratio (RR) with 95% confidence interval (95% CI) was calculated to assess the risk of contacting the infection during the deployment at village Buleusa. Samples were taken from the lesions using iris forceps and transported in 10% Potassium Hydroxide (KOH). Examination of the samples was carried out under direct microscopy to look for eggs/ dead flea. The village headman and elders were taken into confidence and the local population was randomly screened for similar manifestations. 14 adults and 6 children with similar lesions were examined and samples collected. An environmental survey was also undertaken to investigate/ explore the presence of possible arthropods in the small camped ground, especially for mite islands. The camping area was sprayed with Malathion, to eradicate the sand flea population.

RESULTS

All the cases were UN soldiers who were deployed at Buleusa village located at an altitude of 2430 feet in Eastern DRC. The weather conditions were late monsoons to early autumn. The relative humidity was recorded to be from 74 % to 78 %. The focal outbreak lasted for about two weeks, from 21 May to 06 Jun 2012 while sporadic / recurrence of cases continued up to Sep 12. The first case occurred three days after troops reached the campsite. All others were infected within 6 days of reaching the site. The first 38 cases were clustered in time and space, probably forming a part of the initial outbreak. There was history of walking barefoot in camp area by the soldiers and presentation with blisters in plantar and periungual areas of the feet. Initially there was a pea sized swelling which formed an abscess with central black punctum and healed with crater like depression. There was pain in the lesion followed by burning sensation in 92% of cases. 8% patients were asymptomatic.

Clinically the most common site of presentation was mainly on the soles of feet and periungual area (**Fig 1**). The lesions healed with a crater like depression. Vesicles and pustules were seen in 88 % of patients. The lesions were confined only to the feet and were limited to the areas below the ankle joints. No lesions were present on the hands or on the covered areas. 97% had bilateral involvement and only 3% of the troops had solitary lesions (**Table 1**).

Attack rate amongst soldiers who were exposed and those who were not exposed (stayed in vehicles/Armed personnel carriers) to the vector was also estimated. The difference in attack rate between the two groups was statistically significant ($p<0.0001$) and the risk of contacting Tungiasis by walking bare feet in the said village area was real (**Table 2**).

Samples collected from active lesions (**Fig 2**) were examined under microscope and revealed adult flea of Tunga penetrans (**Fig 3**) with multiple eggs contained in the body cavity (**Fig 4 and 5**). The local population screened demonstrated similar findings. Time distribution graph of cases showed multiple peaks indicating common source repeated exposure nature of the outbreak (**Fig 6**).

DISCUSSION

Tunga penetrans is a flea belonging to order S*iphonaptera* of class *insecta*. At least 2500 species of flea have been described worldwide [5] Due to their life cycle, the flea of family tungidae are important as these are ectoparasites which enter human skin and cause various cutaneous manifestations. Tunga penetrans is endemic in tropical Africa, South and central America. This infection is occasionally reported in travellers returning from tropical areas.

Both sexes of this pathogenic flea require an occasional blood meal from a warm-blooded animal for maturation **6**. Due to the fleas' limited jumping ability, the most common location for bites are the feet. An impregnated female, rather than obtaining a blood meal, burrows headfirst into mammalian skin, engorging to become 1 cm in diameter. Via a central punctum that is always maintained, over a hundred eggs are discharged within 3 weeks. After reproducing, the female dies and its remains are eventually sloughed from the skin. The embedded flea acts as a foreign body with its hind part discharging eggs through skin sore thus acting as a route for bacteria causing secondary infection [7]. Bites of immature fleas cause no symptoms; however, the burrowing of the pregnant female sand flea into the skin in order to lay her eggs can cause some morbidity. The most common sites of disease are the soles, toes, toe webs, thighs, perineum and genitalia. The burrowing is initially asymptomatic however the rapidly enlarging flea releases tissue damaging proteolytic enzymes, inciting an inflammatory response in the skin resulting in pain and varying degree of pruritis [8].

The first sign of disease is a small black dot, which enlarges to become an inflammatory papule and then a nodule. A central punctum is always maintained through which the eggs are discharged. Although the majority of cases resolve without sequelae, ulceration, secondary infection and lymphangitis can accompany the infestation [9]. Rarely, serious complications that can occur include tetanus, gangrene and amputation of a digit [10]. The differential diagnosis includes myiasis, arthropod bites, verruca vulgaris, acute paronychia, mycotic granuloma and malignant melanoma.

All the cases reported in our study had history of camping in the endemic area and walking barefoot. Both acute & chronic inflammation occurred simultaneously in different topographical sites in same patient, resulting in polymorphous lesions. In our patients, no complications were seen except mild superficial infection in form of pustules (88%). There were crater like lesions in 92% of cases which indicates high infestation with sand flea. In various military campaigns in Africa, numerous reports of severe infestation with jigger fleas are reported, rendering troops unfit for military duties [11]. Recurrence was found in 11% cases indicating no role of local immunity.

Treatment in form of incision & drainage, local chemical cauterization 70% TCA cautery, oral administration of Tab Ivermectin 12 mg & Tab Albenazole 400mg along with tetanus prophylaxis was given to all cases. Even the residual lesions were cauterized with 70% TCA. Oral course of antibiotics was given to secondarily infected cases [12, 13]. All cases responded well to treatment. Various forms of treatment have been described in literature including oral Thiabendazole, Niridazole, Ivermectin and local therapy with topical Thiabendazole & Ivermectin cream.

In endemic areas, un-orthodox forms of treatment has been mentioned in literature which include local application of a mixture of candle wax & kerosene oil/ medicinal oils and extracts of volatile oils. In our study, local people were using a mixture of diesel and plant extract on the lesions [14] while we used a combination of chemical cauterisation with TCA and oral administration of Ivermectin and Albendazole - which proved highly effective.

CONCLUSION

Tungiasis is quite common in various areas of Congo hence awareness of the condition and its clinical features is of paramount importance. It becomes pertinent to be aware of this condition particularly for UN peacekeepers. The characteristic occurrence of lesions on feet and finally the knowledge of endemic areas will help clinician to arrive at a diagnosis. Simple preventive measures can help in reducing the morbidity from the disease.

Conflicts of Interest

None identified

Table 1
Clinico epidemiological profile of Tungiasis patients:

S No	Clinical features	No of cases (%)
1	Vesicles	40 (88)
2	Pustules	40 (88)
3	Pain and burning sensation	41 (92)
4	Crater like lesions	41 (92)
5	Black punctum	43 (96)
6	Bilateral lesions(feet)	44 (97)
7	Unilateral lesions(feet)	01 (3)
8	Web space lesions	15 (33)
9	Recurrent cases	05 (11)
10	Painless lesions	04 (9)
11	Deformity/ loss of nails	0

Table 2
Risk of contracting Tungiasis infection:

Exposure to the vector	Tungiasis		Total
	Present (%)	Absent (%)	
Present	36 (80)	09 (20)	45 (100)
Absent	09 (30)	21 (70)	30 (100)
Total	45 (60.0)	30 (40.0)	75(100)

$\chi 2$ (Chi square) = 18.75, df = 1, $p < 0.0001$, RR = 2.7, (95% CI of RR being 1.64 to 4.44)

ILLUSTRATIONS

Figure. 1 – Cutaneous lesions of Tungiasis.

Photograph demonstrating multiple cutaneous lesions on the toes of right foot with the characteristic black punctum.



Figure. 2 – Sample collection in Tungiasis. Photograph showing sample collection from an active lesion on the toe in a case of Tungiasis



Figure. 3 - Adult female of Tunga penetrans (direct examination x 10) Photomicrograph of Tunga penetrans flea as seen under direct microscopy



Figure. 4 - Squash preparation of adult flea (Direct x100)
Photomicrograph of squash preparation of an adult female flea expressed from an active lesion demonstrating multiple eggs in the body.



Figure. 5 - Eggs of Tunga penetrans (x 400) Photomicrograph demonstrating eggs of Tunga penetrans, direct examination under microscope



Figure. 6 - Epidemic curve demonstrating distribution of cases during the outbreak from 24 May 2012 to 06 Jun 2012

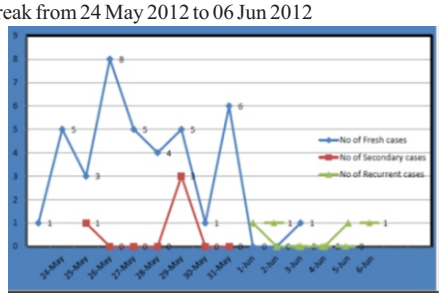

REFERENCES

1. Mehlhorn H. Tungiasis. In: Encyclopedia of Parasitology 3rd edn, Mehlhorn H,ed. New York: Springer, 2008; 1521-1526.
2. Sarvrenaz Z, Mum CD, Fung MA, Eisen DB. Nodule on the toe after travelling to Africa-Diagnosis. Arch. Dermatolol 2008;144(8):1051-1056.
3. Zalar GL, Walther R. Infestation by Tunga penetrans. Arch Dermatolol 1980;116:80-81.
4. Veraldi S, Valsecchi M. Imported Tungiasis: a report of 19 cases and review of the literature. Int J Dermatol 2007;46(10):1061-6.
5. Eckert J. Arthropods. In: Kayser Medical Microbiology 10th edn, Kayser FH, Bienz KA, Eckert J, Zinkernagel RM, eds. New York: Thieme, 2005; 618-20.
6. William DJ. Parasitic infestations, stings and bites. In: Andrew's Diseases of the Skin Clinical Dermatology 10th edn, William DJ, Timothy GB, Dirk ME, eds. Canada: Saunders, 2006; 450-51.
7. Hoiby N, Espersen F, Formsgaard A et al. Biofilm, foreign bodies and chronic infections. Ugeskr Laeger. 1994; 156:5998–6005.
8. Feldmeier H, Eisele M, Sabóia-Moura RC, Heukelbach J. Severe Tungiasis in Underprivileged Communities: Case Series from Brazil. EID 2003; 9(8).
9. Feldemeier H, Heukelbach J, Eisele M et al. Superinfection in Human Tungiasis. Tropical Medicine and International Health 2002; 7(7):559-564.
10. Tonge BL. Tetanus from Chigger flea sores. Journal of Tropical Paediatrics 1989;35:94-94.
11. Decle L. Three years in savage Africa. Metheun 1900.
12. Heukelbach J. Revision on tungiasis: treatment options and prevention. Expert Rev Anti Infect Ther 2006;4(1):151-157.
13. Elgart GW, Meinking TL. Ivermectin. Dermatolol Clin 2003;21(2):277-282.
14. Jong H, Fabiola A, Hesse G, Hermann F. Tungiasis: A neglected health problem of poor communities. Tropical Medicine And International Health 2001;6:267-272