ORIGINAL RESEARCH PAPER

Volume-7 | Issue-1 | January-2018 | PRINT ISSN No 2277 - 8179

INTERNATIONAL JOURNAL OF SCIENTIFIC RESEARCH

AN UNUSUAL CASE OF BUCKET HANDLE CERVICAL TEAR IN A PRIMIGRAVIDA

Gynaecology

Dr. Bhende Amruta Dilip* (Asst. Prof.) Hinduhridaysamrat Balasaheb Thackeray Medical College & Dr. R. N. Cooper Hospital. *Corresponding Author

Dr. Ganesh Shinde (Prof & Dean) Hinduhridaysamrat Balasaheb Thackeray Medical College & Dr. R. N. Cooper Hospital.

Dr. Sangeeta Upadhya (Asst. Hon) Hinduhridaysamrat Balasaheb Thackeray Medical College & Dr. R. N. Cooper Hospital.

Dr. Reena Wani (Addl. Prof. And Hod) Hinduhridaysamrat Balasaheb Thackeray Medical College & Dr. R. N. Cooper Hospital.

KEYWORDS

INTRODUCTION:
Clinically significant trauma to the cervix is seen in 0.2 – 1.7% of vaginal deliveries.(1) The risk factors associated with bucket handle tear are prolonged labour, scarred cervix, prostaglandin instillation, instrumental delivery and cervical encirclage.(2,3)

CASE:
Our case is that of a 21 year old primigravida who presented with prelabour rupture of membranes at 39 weeks gestation. She had a bucket handle tear of the posterior cervix during labour in the absence of any risk factors.

The patient was taken for an emergency cesarean section and delivered a healthy male infant following which the tear was sutured.

CONCLUSION:
Bucket handle cervical tear though rare in modern obstetrics is still a potential life threatening occurrence for the mother and child even in low risk patients. Untoward consequences can be averted with a high index of suspicion.

CASE:
A 21 year old primigravida, married since 1 year, with spontaneous conception, presented to the labour room at 39 weeks of gestation with complaints of leaking per vaginum. Her last menstrual period was on 12/2/16. She was registered at 5 months gestation with regular antenatal follow up and no high risk factors. There was no significant medical or surgical history in the past.

Her routine investigations were within normal limits- Blood group- B Rh positive HIV, HBsAg, VDRL- negative, OGTT- within normal limits. Anomaly scan done at 19 weeks was normal.

On Examination- Her general condition was fair. She was afebrile. Her vitals were stable. Systemic examination was normal.

On per abdomen examination, uterus was overdistended. Liquor was more than adequate. Cephal was floating. Fetal heart sounds were regular, 140/min. She had uterine activity of 1/10/15.

On per speculum examination (P/S), Cervix and vagina were healthy and there was no leak demonstrable.

On per vaginal examination (P/V), os was 3-4 cm dilated, 40% effaced, membranes were bulging, vertex was at station -3, pelvis was adequate for baby.

USG Obstetrics done 2 days prior was suggestive of corresponding growth with EFW of 3.5 kg and polyhydramnios (AFI-27cm). On admission, Hemoglobin -10gm%, Total leucocyte count- 8600, Platelets- 2.43 lakh.

In view of mild contractions, a controlled artificial rupture of membranes (ARM) was done to augment labour. Review examination was done 4 hours later. She was getting 2-3contractions every 10 minutes. On P/V- Os was felt to be 4-5 cm dilated, 50% effaced, vertex at station -2, liquor was clear. The anterior lip of the cervix felt edematous and thick. Hence a repeat P/S examination was done which showed a 4-5 cm curvilinear tear seen on the posterior cervical wall (4 O' clock- 8 O'clock) 2 cm proximal to the os. Vertex was seen through the tear. Cervical lip was displaced retropubically. Os was collapsed but stretchable to 3-4 cm.

She was taken for an emergency cesarean section and a healthy male infant of 3.294 kg was delivered. The operation was uneventful. After abdominal closure, patient was given lithotomy position, examination under anaesthesia and cervical tracing confirmed the pre-operative findings. There was no active bleeding from the tear. Cervical tear was sutured with continuous interlocking sutures with polyglactin 910 (vicryl) no.1

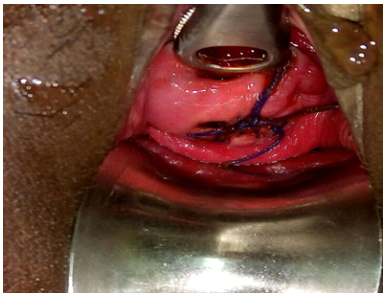

She was given antibiotics for 5 days. Post operative Hemoglobin was 9 gm%. Mother and baby were well and were discharged on day 5. At the 6 week follow up visit, she had no complaints. Examination confirmed that the tear had healed well.

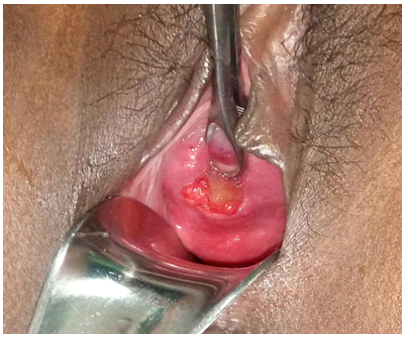

Discussion:
Clinically significant trauma to the cervix is seen in 0.2-1.7% of

vaginal deliveries.(1)

Risk factors associated with bucket handle cervical tear are-
- Scarred cervix
- Cervical encerclage
- Induction of labour
- Prostaglandin instillation
- Precipitate labour
- Prolonged labour
- Instrumental delivery

Most of the cases reported in literature have been associated with one of the risk factors.

No.	Name	Year	Diagnosis	Risk factor	Nature of tear	Dilatation of os	Outcome
1.	Oyelese et al(4)	2001	G2A1 with 38 weeks gestation	-Induction with 4 doses of 25 mcg misoprostol 3 hourly	Midline tear on posterior lip extending upto cul de sac	Fully dilated	3 kg baby delivere vaginally
2.	Uchil et al(5)	2006	G2A1 with 38 weeks gestation		Posterior tear 2.5 cm away from os extending to posterior fornix	5 cm	Baby delivered through the tear.
3.	Geeta Gurung et al(6)	2008	Primigravida with 41 weeks	-Inducton of labour with PGE2 -Precipitate labour	Posterior bucket handle tear	1.5 cm	3.5 kg baby delivered vaginally through the tear.
4.	VYT Chan et al(7)	2012	G5P1L1 MTP3 with 41 weeks gestation.	-H/o LEEP for CIN2 done a year back -3 doses of PGE2, 24 hours apart	4 cm tear at 3 O' clock position	0.5 cm	4.06 kg baby delivered vaginally through the tear.
5.	Djokovic et al(8)	2015	G2MTP1 with 41 weeks gestation	-h/o Dilatation Curettage for 6 weeks abortion 13 years back -Induction with PGE2 gel followed by 50 mcg misoprostol	Posterior bucket handle tear from 4 O'clock to 9 O'clock position	closed	3.3 kg baby delivered vaginally through the tear.
6.	Present case		Primigravida with 39 weeks gestation	None	4-5 cm posterior bucket handle tear from 4 O'clock to 8 O'clock position 2cm proximal to the os	3-4 cm	3.2 kg baby delivered by emergency LSCS

In all the cases reported above, the tears were diagnosed post delivery and the baby was found to have delivered through the tear. All the cases were associated with varying degrees of PPH which prompted a careful examination.

What makes our case interesting is that our patient presented in spontaneous labour. She had no history of trauma to the cervix. The tear was diagnosed in 1st stage of labour. Hence timely intervention was possible. The patient could be delivered by an emergency LSCS avoiding further maternal and fetal morbidity.

Conclusion

In modern obstetrics, cervical tear is rare but it is still a potential life threatening event.

Review of literature highlights the need to be more alert in cases of previous history of trauma to cervix. In cases of precipitate labour, one must keep in mind the possibility of delivery through an undiagnosed cervical tear. Prostaglandins for induction of labor should be used judiciously.

Our case highlights that it is important to have a high index of suspicion even in low risk cases. A simple P/S examination in our case helped us to diagnose the tear early and provide timely intervention.

References :

1. Landy HJ, Laughon SK, Bailit JL, Kominiarek MA, Gonzalez-Quintero VH, Ramirez M, et al. Characteristics associated with severe perineal and cervical lacerations during vaginal delivery. Obstet. Gynecol. 2011;117:627–635. [PMC free article] [PubMed]
2. Melamed N, Ben-Haroush A, Chen R, Kaplan B. Yogev Y. Intrapartum cervical lacerations: characteristics, risk factors, and effects on subsequent pregnancies. Am. J. Obstet. Gynecol. 2009;200:e381–e384. [PubMed]
3. Parikh R, Brotzman S. Anasti JN. Cervical lacerations: some surprising facts. Am. J. Obstet. Gynecol. 2007;196:e17–e18. [PubMed]
4. Oyelese Y, Landy HJ. Collea JV. Cervical laceration associated with misoprostol induction. Int. J. Gynaecol. Obstet. 2001;73:161–162. [PubMed]
5. Uchil D, Kumakech W. Jolaoso A. Spontaneous vaginal delivery through an unusual posterior cervical tear. J. Obstet. Gynaecol. 2006;26:263–264. [PubMed]
6. Gurung, Geeta, Sapana Amatya, Archana Amatya, Akanchya Rana, Ashma Rana, & Akinchan Kafle. "A baby chooses to emerge out from the posterior cervical tear in a prostaglandin induced labor." Nepal Journal of Obstetrics and Gynaecology [Online], 3.2 (2008): 57-58. Web. 6 Dec. 2017
7. Chan VYT, Lau WL. Leung WC. Delivery through a cervical tear in a patient with a history of loop electrosurgical excision procedure and intact cervical Os. Hong Kong J. Gynaecol. Obstet. Midwifery. 2012;12:86–88.
8. Djokovic D, Costa C, Martins A, Abushad S. Spontaneous delivery through a cervical tear without cervical os dilatation.Clinical Case Reports 2015; 3(1): 3–6.