Volume : 3 | Issue : 2 | February 2014 • ISSN No 2277 - 8179

An Unusual Case of Multiple Urethral Foreign Bodies

Medical Science

KEYWORDS : Urethra, foreign bodies.

Dr A.O.Noyda	Associate professor in General surgery, Room No 13, Housemen –B, M.P.Shah Medical College, Jamnagar,
Dr Nirav Satasia	Associate professor in General surgery, Room No 13, Housemen –B, M.P.Shah Medical College, Jamnagar,
Dr Gautam Ladumor	3rd year Resident in surgery, Room No 13 House man –B M.P.Shah Medical College, Jamnagar,
Dr Mohd Aizaz Khan	2nd year Resident in surgery, Room No 13, Housemen –B, M.P.Shah Medical College
Dr Kushal Kapasi	2nd year Resident in surgery, Room no 13, Housemen-B, M.P.Shah medical college
Dr Pramod Adiga	2nd year Resident in surgery, Room no 13, Housemen-B, M.P.Shah medical college

Case Report:
40 year male mentally retarded patient came in OPD with his care taker with complaining of raw area over the scrotum with coming out of maggots & discharge; care taker noticed raw area on same day. Proper history could not be evaluated as the patient was mentally retarded.

➢ **Local examination:**
On inspection two ulcers of approximately 2×1cm irregular in shape & margin over scrotum on both side along with serous discharge, maggots in ulcer & pale granulation tissue over it. Small nonulcerated fibrotic depression found over base of left side of srotum. Patient was able to pass freely thin stream of urine.

On palpation irregular tubular hard structure was palpated on scrotum to base of penile shaft supposed to be foreign body ,rest of examination were including penis, meatal opening, bilateral inguinal sites, bilateral testis were normal.

- Per rectal examination: NAD
- General examination: NAD
- Per abdomen examination: soft, non tender.

- **Investigation:**
- X-ray PBH: irregular shaped opacity noted in scrotal area.
- USG inguinoscrotal region: foreign body with maggots in subcutaneous tissue & thickened scrotal wall.
- Urine R/M : 3-4pus cell detected
- Urine C/S : negative

(As no urinary retention or difficulty in micturition complain so urethrography was not performed)

➢ **Management:** per-operative catheterization was tried with 16F, 14F Foleys catheter, K-90 urethral catheter & infant feeding tube but not negotiated beyond 9cm of meatal opening. Scrotal exploration was performed by putting of incision over feeling of most prominent part of foreign body likely & foreign body were retrieved from subcutaneous plane of peno-scrotal region, on exploration urethra was found already ruptured, most probably due to foreign body which has created false passage in urethra. Stenosis at proximal to bulb of urethra was found. Bellow mentioned objects were retrieved,

1. A wooden block of 10cm size.
2. A plastic tube of 3mm in diameters with 20cm in length.
3. A ball pen refill
4. A plastic plunger of insulin syringe
5. A folded cable wire of 20cm in size.
6. Two metals pins.
7. A safty pin.

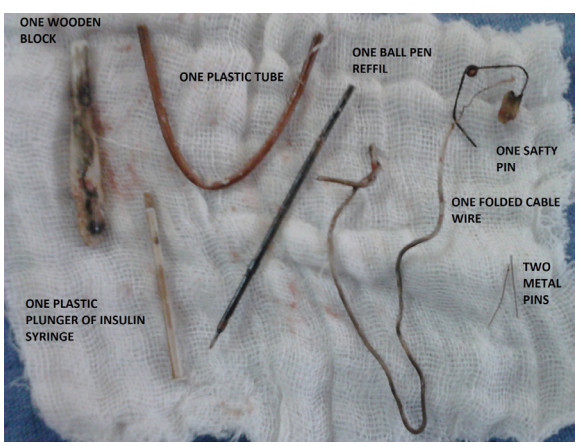

Open suprapubic cystotomy was performed & 18Fcatheter inserted for drainage of urine, daily dressing was done over raw area.

Discussion: Self-inserted intraurethral foreign bodies have been reported in psychiatric patients [4, 5]. Variety of foreign bodies; pencils, electric cables, thermometers, glass rods, candles, hairpins, wires, ampules, broken keys, plastic spoon handles, and pocket batteries [6, 7] been reported. These foreign bodies can cause lower urinary tract problems [7, 8]. Delayed treatment can cause complications, such as infections, urinary retention, squamous cell carcinoma, urethral stenosis, periurethral abscess and/or fistula, calcification and stone formation [5, 8].Optimal treatment depends on patient type, degree of urethral deformation, and shape of the foreign body. Correct treatment results in foreign body removal, most commonly by the endoscopic method, but sometimes requiring open surgery. Various methods of foreign body removal have been described such as meatotomy, cystoscopy, internal and external urethrotomy, and suprapubic cystotomy. Early and immediate removal of the urethral foreign body is recommended. To prevent recurrence patient be referred for psychiatric evaluation.

REFERENCE

1. Rahman nU, Elliott , McAninch : Self-inflicted male urethral foreign | a. body insertion: endoscopic management. BJU Int 2004; 94 (7): 1051-1053. | 2. Stravodimos , Koritsiadis , Koutalellis : Electrical wire as a foreign | a. body in a male urethra: J Med case Reports 2009; 3: 49. | 3. Sukkarieh, Smaldone , Shah B: Multiple foreign bodies in the anterior and posterior urethra. Int Braz J Urol 2004; 30 (3): 219-220 | 4. Walsh P, Moustafa . Retention of urethrovesical foreign bodies: J Emerg Med 2000; 19 (3): 241-243. | 5. granados EA, Riley, Rios gJ: Self introduction of urethrovesical foreign bodies. Eur Urol 1991; 19 (3): 259-261. | 6. Ayyildiz , g ürdal M, n uho ğ lu B et al: A foreign body self-inserted via theurethra into the bladder: pocket battery. Int Urol n ephrol 2003; 35 (2): 251-252. | 7. Ali Khan S, Kaiser cW, Dailey B et al: Unusual foreign body in the urethra. | a. Urol Int 1984; 39 (3): 184-186. |