ORIGINAL RESEARCH PAPER
VOLUME-6 | ISSUE-7 | JULY-2017 | ISSN No 2277 - 8179 | IF : 4.176 | IC Value : 78.46
INTERNATIONAL JOURNAL OF SCIENTIFIC RESEARCH

Analysis of cases of Endonasal dacryocystorhinostomy(DCR) performed at a tertiary eye care centre.

Ophthalmology

Dr Falguni A Chudasama M.B.B.S, M.S. Ophthalmology, FNERF(Vitreo-retina)

ABSTRACT

Purpose of study is to describe technique, success rate of endonasal DCRs and to report complications. Prospective, interventional consecutive study was performed at a tertiary eye care center. Total 40 patients were operated from August 2013 to April 2014. All patients were followed at 1 week, 1 month and 6 month postop. Anatomic success with a patent nasolacrimal duct was achieved in all 40 patients at post-op day 7 & post-op 1 month. Complications: Bleeding on first postop day was found in 3 patients and Was controlled with nasal packing. Late recurrence of epiphora in 4 patients at 6 months was corrected by revision endoscopic surgery successfully.

KEYWORDS:

Dacryocystorhinostomy (DCR), Nasolacrimal duct (NLD)

Introduction:

Dacryocystorhinostomy(DCR) is the procedure of choice for dacryocystitis.

Two major approaches are: external, via a transcutaneous incision and endonasal endoscopically guided. Endonasal dacryocystorhinostomy is less time consuming and safe procedure with almost equal anatomical success rate[1,2]. In principle the operation involves anastomosing the lacrimal sac to the nasal mucosa of the middle nasal meatus. Advantages of endonasal DCR include the lack of a skin incision, less operating time, less blood loss and less risk of cerebrospinal fluid leakage. There may be a need for additional procedures to allow adequate visualization such as correction of a deviated nasal septum.

MATERIAL AND METHODS:

A Prospective, non-comparative, interventional consecutive case series study was performed. A total number of 40 patients were operated at a tertiary eye care centre from August 2013 to April, 2014. All the patients were operated under local anesthesia with sedation using Storz 0 degree endoscope & camera. Surgery was advised in patients having Epiphora, (relapsing)Dacryocystitis, Dacryocele, Dacryolithiasis. Surgery was contraindicated for malignant tumour in proximity of NLD, tuberculosis, fungal infection, nasal Pathology e.g. Deviated nasal septum.

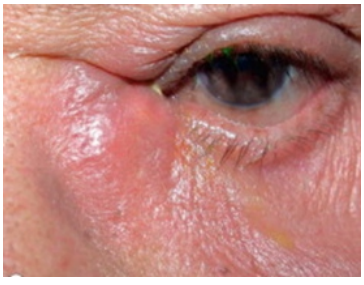

Figure 1: Photograph showing Dacryocystitis

Surgical Procedure

Preoperative fitness examination included routine blood tests including BT, CT, PT, APTT. Patients were advised 6 hours nil by mouth. Local Anaesthesia under controlled sedation was given by anesthetist. Local infiltration was done using 2% lidocaine with 1:200000 adrenaline and nasal packing with the same solution completed. The nasal mucosa is incised, elevated, and removed around the light spot with the use of a scalpel. The thin part of the lacrimal bone is punctured and enlarged with bone punches. The sac mucosa is opened, and a portion of the medial wall is excised. An average duration of surgery was 20 minutes on an average.(4,5) Post operative course of antibiotics, eye drops, nasal drops was given for 1 week. Patients were strictly instructed to clear nose proper by using buffered saline solution to clear crusts/clots. Patients were instructed to massage over sac area post operatively for at least 10 days. Patients were followed at post-operative day 7, 1 month and 6 months. On each follow up Sac syringing was performed to check the patency of nasolacrimal duct and complains of patient for any recurrence of epiphora were noted.

RESULTS

Average age was 50 years. Majority of patients, 25 out of 40 were female. Majority of patients, 90% presented with epiphora whereas rest 10% presented with mucocele. Anatomical Success with a patent naso-lacrimal system was achieved in all 40 patients at post-op day 7 & post-op 1 month giving anatomical success of 100%. 4 of these 40 patients had block at 6 months.

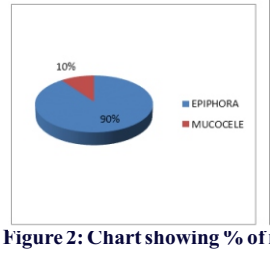

Figure 2: Chart showing % of mode of presentation

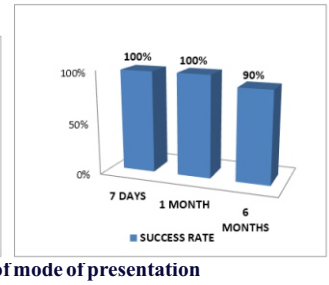

Figure 3: Chart showing success rate in %

Complications

Intraoperative bleeding was not as severe as in classical DCR. Immediate postoperative bleeding on first postop day was found in 3 patients and was controlled with nasal packing. Late postoperative recurrence of epiphora was found in 4 patients at 6 months and revision surgery was done endoscopically successfully.

Discussion

In our study we have good anatomical success rate almost equal to classical DCR.(5) Endonasal DCR can also be considered better than external DCR as majority of patients were females and cosmetically more conscious(3). A scar from classical DCR can be prevented over face. So, endonasal DCR will be a better option from cosmetic point of view. In classical DCR medial canthal ligament has to be incised so pumping mechanism of nasolacrimal complex will become compromised.

Conclusion

Endonasal DCR has a satisfactory success rate at our institute without potential complications. At postop day 7 and at the end of 1 month we could achieve a success rate of 100%. At the end of 6 months it was 90% which is comparable to anatomical success rate of external DCR. Complications from endonasal DCR may be comparable to or less frequent than those for external DCR. So, we can conclude that endonasal DCR is an

excellent technique in expert hands.

References:

(1) Sandeep Bharangar et al… Endoscopic Endonasal Dacryocystorhinostomy: Best Surgical Management for DCR…. Indian J Otolaryngol Head Neck Surg (October–December 2012) 64(4):366–369; DOI 10.1007/s12070-011-0345-0

(2) Tsirbas A et al… Endonasal dacryocystorhinostomy with mucosal flaps. Am J Ophthalmol. 2003 Jan; 135(1):76-83.

(3) Anniko M, Bernal-Sprekelsen M, Bonkowsky V(2009) Otorhinolaryngology, Head and Neck Surgery, pp 266–269

(4) Peter DJ (2006) Techniques in endonasal Dacryocystorhinostomy. Essentials in opthalmology, Part 3, 71–82, doi: 10.1007/3-540-29969-6-6

(5) Olver JM (2003) The success rates of endonasal Dacryocystorhinostomy. Br Journal of Opthalamol 87(11):1431

(6) Goyal R et al.. Analysis of 104 cases of endonasal dacryocystorhinostomy in a tertiary care hospital: a prospective study. Indian J Otolaryngol Head Neck Surg. 2014 Jan;66(1):102-5. doi: 10.1007/s12070-013-0693-z.

(7) David S, Raju R, Job A, Richard J (1999) A comparative study of external and endoscopic endonasal Dacryocystorhinostomy—apreliminary report. Indian J Otolaryngol Head Neck Surgery 52: 37–39. doi:10.10071BFO2996430