ORIGINAL RESEARCH PAPER
VOLUME-6 | ISSUE-6 | JUNE-2017 | ISSN No 2277 - 8179 | IF : 4.176 | IC Value : 78.46
INTERNATIONAL JOURNAL OF SCIENTIFIC RESEARCH

Analysis of Outcome and complication of short intramedullary nail in unstable proximal femoral fracture seven year retrospective study

Orthopaedics

Dr. Subhadip Mandal (MS orthopaedics, DNB (Ortho) MNAMS, Department of Orthopaedics, NRS Medical College and Hospital, 138 AJC Bose Road, Kolkata – 700014, India

Dr. H.Bala (MS Orthopaedics), Department of Orthopaedics, NRS Medical College and Hospital, 138 AJC Bose Road, Kolkata – 700014, India

Dr. U. Banerjee (MS Orthopaedics, DNB Ortho), Department of Orthopaedics, NRS Medical College and Hospital, 138 AJC Bose Road, Kolkata – 700014, India

Dr. A.S. Mukherjee (MS Orthopaedics), Department of Orthopaedics, NRS Medical College and Hospital, 138 AJC Bose Road, Kolkata – 700014, India

Dr. Nitin Kumar (MS Orthopaedics), Department of Orthopaedics, NRS Medical College and Hospital, 138 AJC Bose Road, Kolkata – 700014, India

Dr. Srikanta Kundu (MS Ortho), Department of Orthopaedics, NRS Medical College and Hospital, 138 AJC Bose Road, Kolkata – 700014, India

ABSTRACT

Purpose: Multiple studies have demonstrated efficacy of TFN and PFN in unstable trochanteric and sub trochanteric femur fractures respectively. But only a few have discussed on complications with a long term follow – up.

Methods: Retrospective study where we analyzed the results of two prospective studies (June 2009 to May 2016).

I. Fixation of comminuted unstable trochanteric fracture (AO 2.2 to AO 3.3) with Trochanteric Femoral nail (TFN). (n = 80) and

II. Fixation of sub trochanteric femoral fracture (AO 32 A.1 to AO 32 C.3) with Proximal Femoral nail (PFN). (n = 80).

Results: All fractures were united. Regarding Cleveland index in 70% (TFN) and 62% (PFN) of cases cephalic screws were in safe zones. Average Tip-apex distances were 12.5 mm (TFN) and 13 mm (PFN). About 36% (TFN) and 40% (PFN) cases showed a fracture gap on immediate post-operative x-ray which disappeared by impaction in next 6–8 weeks. Evaluation of HHS showed 86.25% (TFN) and 91.25% (PFN) cases in excellent to good category at the end of 6 months. Regarding complications, progressive varus collapse was noted in 3.75% cases (TFN). Delayed union was noted in 3.75% (TFN) and 6.75% (PFN) cases. Few cases with migration of screws (Z effect and reverse z effect), fracture shaft of femur and deep wound infection with osteomyelitis of proximal femur required re-operation later on.

Conclusion: Fixation by TFN and PFN are an effective treatment in unstable proximal femoral fractures; however meticulous preoperative planning, intraoperative wise decision making and regular follow up are the key to avoid the complications.

KEYWORDS:

Short femoral nails, Trochanteric femoral nail, Proximal femoral nail, Z and reverse Z effect, Proximal femoral fractures

Introduction

Hip fractures remain epidemic among the elderly population, with >300,000 new fractures worldwide occurring each year [1]. It has always been a controversial point of discussion regarding the management of comminuted unstable trochanteric and subtrochanteric fractures. Several implant designs have been developed in an attempt to aid fracture fixation, facilitate early ambulation, reduce the risk of complications and improve functional outcomes [2-4]. The screw-plate (extramedullary) and nailing systems (intramedullary) are the two basic osteosynthesis methods used in the management of aforementioned fractures.

Proximal Femoral nail (PFN) and Trochanteric Femoral nail (TFN) has been extensively used in the last decade in subtrochanteric and in comminuted unstable trochanteric fractures respectively [5 – 8]. There are several reports showing benefits of Proximal Femoral nails and Trochanteric femoral nails [5 - 8], but it is still associated with technical failures [9, 10].

The purpose of this study is to analysis the outcome of results in using these two types of implants in proximal femoral fractures and to discuss their complications in detail.

Material and Methods

Ethical Committee of the concerned Institution had granted Ethical approval for this study and all procedures performed in studies involving human participants were in accordance with the ethical standards of the institutional and/or national research committee and with the 1964 Helsinki declaration and its later amendments. Informed consent was taken in local, regional and national language from all patients prior to include them in study.

This is a retrospective study where we had analysed the results and the complications of two prospective studies conducted in our institution from June 2009 to May 2016.

I. Fixation of comminuted unstable trochanteric fracture (AO 2.2 to AO 3.3) with Trochanteric Femoral nail (TFN). (n = 80)
II. Fixation of subtrochanteric femoral fracture (AO 32 A.1 to AO 32 C.3) with Proximal Femoral nail (PFN). (n = 80)

Patients with pathological fracture, inability to walk before the fracture, associated neurological disorders, polytrauma patients, and dropped out patients during the study period were excluded.

Baseline characteristics were documented pre-operatively; outcome measures were subdivided into intra-operative, post-operative and follow-up data at six weeks, three months, six months, one year and then annually for at least next 3 years.

Surgical Procedure

Both of the implants used in the study were solid SS (316 LVM) nail; TFN is of 180 mm in length and PFN is of 240 mm. Both of them were available in 10, 11, and 12 mm diameter. Two cervical screws were inserted in the femoral head-neck fragment. These screws provide rotational stability. Both of them can be distally locked either dynamically or statically. Surgery was performed with the patient in the supine position on a fracture table, with the injured extremity slightly adducted to facilitate insertion of the nail.

Patient Assessment and Follow up

Intra-operatively, blood loss was measured from the swabs and the suction unit. The time required for closed reduction of the fracture, the operating time and the fluoroscopy time were recorded. The

demographic data (age and sex), perioperative information and length of hospital stay were recorded for each patient.

Follow-up evaluations consisting of clinical examination, assessment of functional outcome and radiographs were performed at 6 weeks, 3 months, 6 months and then annually. Patients were followed up for a minimum of 3 years. Functional outcomes were assessed using the Harris Hip scoring system. Patient outcome scores were categorized as excellent (≥ 90), good (89 – 80), fair (79 – 70) or poor (≤ 70). Radiographic evaluation was done for fracture union, extent of fracture collapse, medial displacement, neck-shaft angle alteration, implant failure and change in implant position. Radiographic fracture union was defined as the presence of bridging callus on antero-posterior and lateral radiographs. Additionally evaluation of Garden alignment index and Cleveland index, with measurement of Tip-apex distance and Fracture-gap were simultaneously done at each follow-up visit.

Results

In both of these studies all cases show union. Results in detail are shown in Table – I. Harris Hip Score of both the studies are depicted in Table – II. Complications encountered in both of these studies are enlisted in Table – III.

Discussion

The successful treatment of trochanteric and subtrochanteric fractures depend on many factors, including the patients factor (age, general health, time from fracture to treatment, comminution, bone quality, concurrent medical treatment), surgeon factor (competency, stability of fixation) and the implant factor [11]. Early reports on intramedullary implants have demonstrated substantial advantages in this type of fixation, including a minimally invasive surgical technique, shortened operating times, decreased blood loss, improved biomechanics, greater stability of fixation, earlier patient mobilization, and shorter lengths of stay [12-14]. Trochanteric Femoral Nail (TFN) and Proximal Femoral Nail (PFN) are the youngest members in this intramedullary group. A number of biomechanical and clinical studies have been published over its efficacy [5, 6, 7, 8, 15, 16, and 17]. But very few published data have been acquired regarding the detailed analysis of complications in using TFN and PFN in comminuted unstable trochanteric fractures and subtrochanteric fractures respectively [17].

In our study the parameters as: average duration of surgery, average time for image intensifier use, requirement of blood transfusion and average period of hospital stay were comparable with the standard literatures [18-24] [Table-I]. As the learning curve progress over time, the duration of surgery and the radiation exposure gradually decreases. Factors which had prolonged hospital stay were coexisting medical illness and the incidence of post operative complications specially infection. All of the fractures eventually united which is comparable with the studies by A. Lenich et al [25] and Ekstrom et al [26] [Figure-Ia and Ib]. Regarding Harris Hip Score [Table-III], our results were at par with the literature of Ruecker AH et al 2009 [HHS (75.1+/- 13.4) at 24 weeks] [27] and Loubignac F et al 2009 [mean HHS 80 at 24weeks] [28]. Patients with multiple co-morbidities, with associated post-operative complications, patients needed reoperations and those who did not performed rehabilitation exercises regularly in postoperative period had fair to poor results.

Garden alignment index has been used as a tool for judging the quality of the fracture reduction [25]. In both the studies, in average 42% cases we saw the result is very good, in 38% good, in 15% satisfying and in 5% bad results. Of note, we did not detect any implant related complications in the patient group with satisfying to bad results.

Regarding the Fracture gap and the low fracture site contact, no significant rotational instability or cutting out of the implant found in subsequent follow-up. We confer it as a sign for the strong stability of implant as suggested by Lenich et al 2006 [25]. In most of the cases, radiologic follow-up showed fracture impaction in next 6–8 weeks.

Because of the physiological 12 deg anteversion of the neck of femur, the Cleveland zones 5, 6, 8 and 9 are in an area of no rotation forces. We placed most of the tips of cervical screws in zone 5, 6, 8, 9 (average 66%) [29]. Implant tips placed in the zones 4 or 7, are from the bio-mechanical point of view in the area of rotational forces. This might account for rotation of the head and neck fragment with the effect of loosening or cutting out. Average 34% screws were mistakenly placed in the unstable zones but signs of loosening were seen in five cases only (05/160), 3.12%.

Baumgaertner described a lower complication rate for implant tips placed close to the subchondral bone of the femoral head [30]. Because of the good bone quality in this area, we tried to bring the tip of the cervical screw up to 5 mm close to the subchondral area. Regarding Tip - apex distance (TAD) measurement, we had four cases with TAD > 25 mm, and at the end of three years, incidence of loss of reduction (progressive varus collapse) happened in three of them (03/160), but no incidence of neck screw cut-out had been encountered.

Regarding complications [Table-III], about the *incidence of infection* our study was statistically similar with the study of S.H.Bridle et al [31]. Deep infection including osteomyelitis of proximal femur required repeated debridement which delayed post operative rehabilitation.

Progressive varus collapse was noted in unstable intertrochanteric fractures treated with TFN. This complication was typically encountered in fractures with posteromedial comminution, associated fractures of lateral femoral wall, and in fractures of reverse obliquity pattern. This observation was supported by a number of studies [32, 33]. We had encountered this complication in three cases of Trochanteric femoral nail. Among them, one case was further complicated by developing *Reverse Z deformity* – it was managed by removal of the protruded screw. Another patient with varus deformity had shortening of the limb by 2.2 cm. It was managed effectively with shoe raise. In a patient with PFN, he presented with deep infection, osteomyelitis of proximal femur, progressive varus collapse and reverse Z effect [Figure-II] whose management has been discussed later on.

Reduction in Coxa-valga position occurred in a case of TFN as the fracture gets stabilised in that position. But in long term follow – up the patient had not developed secondary osteoarthritis hip both clinically and radiologically.

Regarding *cut-out of the cephalic screws*, it is most commonly seen in osteoporotic bones [21, 34] possibly as the result of varus deviation and rotation. It mostly occurs in the superomedial quadrant of the femoral head which in many anatomical and biomechanical studies have shown to be the weakest part [35]. Surgical fault responsible for this failure is not following the tip apex distance concept. We had not encountered a single case of cut-out so far.

Regarding *breakage of hard-wires*, per-operative breakage of a guide wire within the femoral head-neck fragment happened during instrumentation of TFN. In primary attempts we failed to remove it and were decided to keep a regular vigil on it. But fortunately, even at the end of three years follow-up, the piece of wire is stationary as it was [Figure-III].

Our experience with *migration of screws* shows, regarding the Z – effect, we have encountered this complication in 2 cases of TFN [Figure-IV] and not in a single case of PFN. The Z-effect involves the lateral migration of the inferior screw and medial migration with or without perforation of the femoral head by the superior screw. According to Robinson et al [36] when the compressive forces on the femoral head were greater than those on the femoral neck, the inferior screw migrated laterally. In both of these cases, we removed the symptomatic inferior screw and in long term follow-up femoral head penetration by superior screw has not been observed. Regarding the reverse Z effect, it has been described as the lateral migration of the superior screw accompanied by the medial migration of the inferior screw. As per the available literature when the femoral neck presented with a lower bone density than the femoral head, which is typical of unstable fractures, there was a tendency for the inferior screw to migrate [36]. We had encountered reverse Z effect in two cases of PFN and in a case of TFN. A patient of PFN with this complication additionally developed severe osteomyelitis of proximal femur and progressive varus collapse. In long term, we have to sacrifice the infected bone and replaced it with long stem prosthesis. In other two cases we removed the symptomatic screws and observed regularly.

Fracture of the femoral shaft happened in a follow up case of PFN at around 4 months post-operative due to a domestic fall [Figure-V]. As

there was associated delayed union, re-fracture happened around the primary fracture site and the nail also broken at its weak part (hole for the bolt). It was managed by a revision surgery with femoral interlocking nail.

Technical difficulties with instrumentation (e.g. Dislodgement of the nail cap) happened in few cases which were effectively managed.

Reoperation needed in three cases (03/80); (3.75%) of PFN due to debridement of deep infection, osteomyelitis with reverse Z effect and for femoral shaft fracture.

Abductor lurch was observed in a few cases in both TFN and PFN group. Violation of abductor mechanism or fragmentation of greater trochanter may give rise to this abnormal gait. If healing of the trochanter takes place nicely, then the lurch gradually disappears. Progressive varus collapse can also lead to persistent abductor lurch. In our patients, effective abductor muscle strengthening with intensive physiotherapy solved the problem in most of them.

Limitations of our study are lack of control group and we have not analysed rate of refracture after implant removal.

Conclusion:
Although intramedullary fixation (both TFN and PFN) is an effective method for the treatment of unstable intertrochanteric and subtrochanteric fractures, it may evolve with complications. Meticulous preoperative planning, intraoperative wise decision making and regular follow up are the key to avoid the complications.

Conflict of interest statement:
The authors are hereby to declare that they have no conflict of interest related to the publication of this manuscript.

Ethical standard statement:
Ethical Committee of the concerned Institution had granted Ethical approval for this study and it has been performed in accordance with the Ethical standards of the 1964 Declaration of Helsinki as revised in 2000.The need for informed consent was waived by the ethical committee since rights and interests of the patients would not be violated and their privacy and anonymity would be assured by this study design.

Funding:
The author(s) received no financial support for the research, authorship, and/or publication of this article.

Acknowledgements :
My parents, teachers, the patients and finally my beloved better-half, my wife.

The author(s) received no financial support for the research, authorship, and/or publication of this article.

Table – I: Showing the results of operative fixation by TFN and PFN.

	Trochanteric Femoral Nail (TFN)	Proximal Femoral Nail (PFN)
Rate of Union	At 12 wks : 64% At 24 wks: 28% Beyond 24 wks: 8%	At 12 wks: 56% At 24 wks : 34% Beyond 24 wks: 10%
Average duration of surgery	88 min	92 min
Average time for image intensifier	135.5 seconds	130 seconds
Blood transfusion	60% cases	55%cases
Average Hospital stay	3.5 days	3 days
Cleveland Index	Zone (5,6,8 & 9): 70% Other zones : 30%	Zone (5,6,8 & 9): 62% Other zones : 38%
Average Tip – Apex distance	12.5 mm	13mm
Fracture gap on immediate post-operative x-ray	36% cases	40% cases

Table II: Evaluation of the functional outcome by Harris Hip Score done at 24 weeks (6 months) follow up.

Treatment given	Harris Hip Score			
	Excellent (≥ 90)	Good (89 – 80)	Fair (79 – 70)	Poor (≤ 70)
TFN (n = 80)	17	52	9	2
PFN (n = 80)	20	53	4	3

Table – III: complications encountered in patients treated with TFN and PFN in comminuted unstable intertrochanteric and sub-trochanteric fractures respectively.

Complications	Number of patients	
	TFN (n=80)	PFN (n=80)
Infection [A] Superficial Wound Infection [B] Deep including osteomyelitis of femur	3 cases nil	3 cases 2 cases
Thromboembolic phenomenon	nil	nil
Coxa - vara	3 cases	1 case
Coxa - valga	1 cases	Nil
Delayed union	3 cases	5 cases
Non - union	nil	Nil
Shortening (< 2 cm) (> 2 cm)	7 cases	5 cases
	1 case	1 case
Breakage of Implant	1 case	Nil
Migration of screw [Z – effect] [Reverse Z effect]	2 cases 1 case	nil 2 cases
Cut - out	Nil	Nil
Technical Difficulties regarding Instrumentation	5 cases	1 case
Femoral shaft fractures	nil	1 case
Penetration of screw in hip joint	nil	Nil
Re - operation	nil	5 cases
Abductor lurch	3 cases	2 cases

FIGURE LEGENDS

Figure Ia:
A case of post-traumatic bilateral unstable intertrochanteric fracture femur, treated with Trochanteric Femoral Nail (TFN): Follow – up radiograph at the end of one year

Figure Ib:
A case of post-traumatic sub-trochanteric fracture femur, treated with Proximal Femoral Nail (PFN): Follow – up radiograph at the end of one year

Figure II:
A follow-up case of Proximal Femoral Nail complicated with persistent deep tissue infection, osteomyelitis of proximal femur, reverse Z effect of cephalic screws and proximal migration of nail.

Figure III:
Implant Breakage (guide wire) in the femoral head. No incidence of migration of the implant was noted at the end of 3 years.

Figure IV:
Migration of screw = 'Z – effect' phenomenon (medial migration of the superior screw and lateral migration of the inferior screw).

Figure V:
A follow-up case of PFN in delayed union, presented with refracture with broken nail at 4 months post-op period after a domestic fall

Figure Ia:
A case of post-traumatic bilateral unstable intertrochanteric fracture femur, treated with Trochanteric Femoral Nail (TFN) : Follow – up radiograph at the end of one year



Figure Ib:
A case of post-traumatic sub-trochanteric fracture femur, treated with Proximal Femoral Nail (PFN) : Follow – up radiograph at the end of one year.



Figure II:
A follow-up case of Proximal Femoral Nail complicated with persistent deep tissue infection, osteomyelitis of proximal femur, reverse Z effect of cephalic screws and proximal migration of nail

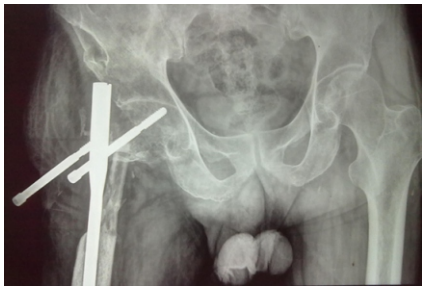

Figure III:
Implant Breakage (guide wire) in the femoral head. No incidence of migration of the implant was noted at the end of 3 years



Figure IV:
Migration of screw = 'Z – effect' phenomenon (medial migration of the superior screw and lateral migration of the inferior screw)



Figure V:
A follow-up case of PFN in delayed union, presented with refracture with broken nail at 4 months post-op period after a domestic fall



References

1. Rubenstein L. Hip protectors—a breakthrough in fracture prevention. N Engl J Med. 2000; 343:1562-1563.
2. Utrilla AL, Reig JS, Munoz FM, et al. Trochanteric gamma nail and compression hip screw for trochanteric fractures: a randomized, prospective, comparative study in 210 elderly patients with a new design of the gamma nail. J Orthop Trauma. 2005; 19: 229 – 233.
3. Lunsjo K, Ceder L, Stigsson L, et al. Two-way compression along the shaft and the neck of the femur with the Medoff sliding plate: one-year follow-up of 108 intertrochanteric fractures. J Bone Joint Surg Br. 1996; 78: 387 – 390.
4. Simmermacher RK, Bosch AM, Van derWerken C. The AO/ASIF-proximal femoral nail (PFN): a new device for the treatment of unstable proximal femoral fractures. Injury. 1999; 30: 327 – 332.
5. L. Pearce McCarty, III MD, John Wixt ed, MD, Mark Vrahas, MD and R. Malcolm Smith, MD, FRCS Use of the Long Trochanteric Fixation Nail for Unstable Intertrochanteric and Subtrochanteric Fractures; Massachusetts General Hospital
6. The Perry Initiative, Module: #10 - Trochanteric Fixation Nail Author(s): Jenni Buckley, PhD Date Created: April 10th, 2011
7. A. Lenich Æ E. Mayr Æ A. Ru¨ ter Æ Ch. Mo¨ ckl B. Fu¨ chtmeier, First results with the Trochanter Fixation Nail (TFN): a report on 120 cases. Arch Orthop Trauma Surg (2006) 126: 706–712 DOI 10.1007/s00402-006-0117-6.
8. W. M. Gadegone & Y. S. Salphale et al; Proximal femoral nail – an analysis of 100 cases of proximal femoral fractures with an average follow up of 1 year.; International Orthopaedics (SICOT) (2007) 31:403–408, DOI 10.1007/s00264-006-0170-3.
9. R. E. S. Pires, E. O. Santana, L. E. N. Santos, V. Giordano, D. Balbachevsky, and F. B. dos Reis, "Failure of fixation of trochanteric femur fractures: clinical recommendations for avoiding Z-effect and reverse Z-effect type complications," Patient Safety in Surgery, vol. 5, no. 1, article 17, pp. 1–6, 2011.
10. T. Pavelka, J. Mat˘ejka, and H. ˇ Cervenkov´a, "Complications of internal fixation by a short proximal nail," Acta Chirurgiae Orthopaedicae et Traumatologiae Cechoslovaca, vol. 72, no. 6, pp. 344–354, 2005.
11. M. S. Butt, S. J. Krikler, S. Nafie, and M. S. Ali, "Comparison of dynamic hip screw and gamma nail: a prospective, randomized, controlled trial," Injury, vol. 26, no. 9, pp. 615–618, 1995.
12. Davis J, Harris MB, Duval M, D'Ambrosia R. Pertrochanteric fractures treated with the Gamma nail: technique and report of early results. Orthopedics. 1991;14:939-42.
13. Lindsey RW, Teal P, Probe RA, Rhoads D, Davenport S, Schauder K. Early experience with the gamma interlocking nail for peritrochanteric fractures of the proximal femur. J Trauma. 1991;31:1649-58.
14. Boriani S, De Iure F, Bettelli G, Specchia L, Bungaro P, Montanari G, Capelli A, Canella P, Regnoli R, Triscari C. The results of a multicenter Italian study on the use of the Gamma nail for the treatment of pertrochanteric and subtrochanteric fractures: a review of 1181 cases. Chir Organi Mov. 1994;79:193-203.
15. M. J. Parker and H. H. Handoll, "Gamma and other cephalocondylic intramedullary nails versus extramedullary implants for extracapsular hip fractures in adults," Cochrane Database of Systematic Reviews, vol. 16, no. 3, Article ID CD000093, 2010.
16. H.W. Jones, P. Johnston, and M. Parker, "Are short femoral nails superior to the sliding hip screw? A meta-analysis of 24 studies involving 3,279 fractures," International Orthopaedics, vol. 30, no. 2, pp. 69–78, 2006.
17. Michael J. Gardner, MD; Mohit Bhandari, MD; Brandon D. Lawrence, MD; David L. Helfet, MD; Dean G. Lorich, MDTreatment of intertrochanteric hip fractures with the AO Trochanteric Fixation Nail Healio Orthopaedics February 2005 – Volume 28 • Issue 2.
18. Celebi L, Can M, Muratli HH, et al. Indirect reduction and biological internal fixation of comminuted inter-trochanteric fractures of the femur. Injury. 2006;37:740-750.
19. Kostal R, Dousa P, Bartonicek J. The proximal femoral nail(PFN)—another alternative for osteosynthesis of trochanteric fractures, Rozhl Chir 2003 Jan; 82 (1) : 28 - 31.
20. Pavelka T, Kortus J, Linhart M. Osteosynthesis of trochanteric fractures using proximal femoral nails, Acta Chir Orthop Traumatol Cech, 2003; 70 (1): 31-8.
21. J. Pajarinen, J Lindahl, O Michelson, E Hirvensalo(2005): Pertrochanteric femoral fractures treated with a dynamic hip screw or a proximal femoral nail; jbjs, vol 87-B, 76-81.
22. Hu W, Luo Y, Fang H(2006): comparision of various kinds of internal fixation in unstable intertrochanteric fracture; Zhongguo Xiu Fu Chong 2006 July;20(7): 690-4.
23. H M Klinger, HM Baums, M Eckert, and R Neugebauer(2005): A comparative study of unstable per and intertrochanteric femoral fractures with DHS and PFN and TSP; Zentralbl chir, 2005 130.
24. Di Monaco M, Vallero F, Tappero R(2007); Hip fracture does not affect the functional outcome after acute in patient rehabilitation. Euro Medicophys 2007 oct 23.
25. A. Lenich , E. Mayr et al ; First results with the Trochanter Fixation Nail (TFN): a report on 120 cases.. Springer-Verlag aug 2006.
26. Ekstrom W, Karlsson-Thur C, Larsson S, et al. Functional outcome in treatment of unstable trochanteric and Subtrochanteric fractures with the Proximal femoral nail and

Medoff sliding plate. J Orthop Trauma. 2007;21:18-25.
27. Ruecker AH, Rupprecht M, Gruber M, Gebauer M, Barvencik F, Briem D, et al. The treatment of intertrochanteric fractures: results using an intramedullary nail with integrated cephalocervical screws and linear compression. J Orthop Trauma 2009; 23: 22-30.
28. Loubignac F, Chabas JF. A newly designed locked intramedullary nail for trochanteric hip fractures fixation: results of the first 100 trochanteric implantations. Orthop Traumatol Surg Res. 2009; 95(2):139–144 doi:10.1016/j.otsr.2009.01.002
29. Cleveland M BDM, Thompson F R, Hudson J, Wilson J, Ishizuka Tadao (1959) A ten year analysis of intertrochanteric fractures of the femur. J Bone Joint Surg 41-A:1399–1408.
30. Baumgaertner MR, Curtin SL, Lindskog DM, Keggi JM (1996) The value of the tip-apex distance in predicting failure of fixation of peritrochanteric fractures of the hip. J Bone Joint Surg Am 78(9):1058–1064.
31. Bridle SH, Patel AD, Bircher M, et al. Fixation of intertrochanteric fractures of the femur. A randomised prospective comparison of the gamma nail and the dynamic hip screw. J Bone Joint Surg Br. 1991; 73: 330 – 334.
32. Palm H, Jacobsen S, Sonne-Holm S, Gebuhr P, and the Hip Fracture Study Group. Integrity of the lateral femoral wall in intertrochanteric hip fractures: an important predictor of a reoperation. J Bone Joint Surg (Am) 2007; 89: 470-5.
33. Haidukewych GJ, Israel TA, Berry DJ. Reverse obliquity fractures of the intertrochanteric region of the femur. J Bone Joint Surg Am. 2001;83:643-50.
34. Schipper IB, Steyerberg EW, Castelein RM, et al. Treatment of unstable trochanteric fractures Randomised comparison of the gamma nail and the proximal femoral nail. J Bone Joint Surg Br. 2004; 86: 86 – 94.
35. Brown TD, Ferguson AB. Mechanical property distributions in the cancellous bone of the human proximal femur. Acta Orthop Scand. 1980; 51: 429 – 437.
36. Robinson Esteves Santos Pires,corresponding author1,2 Egídio Oliveira Santana, Júnior,1 Leandro Emílio Nascimento Santos,1 Vincenzo Giordano,3 Daniel Balbachevsky,4 and Fernando Baldy dos Reis; Failure of fixation of trochanteric femur fractures: Clinical recommendations for avoiding Z-effect and reverse Z-effect type complications; Patient Saf Surg. 2011; 5: 17.