Research Paper

Volume : 5 | Issue : 3 | March 2016 • ISSN No 2277 - 8179 | IF : 3.508 | IC Value : 69.48

# Anatomical Study of Coronary Dominance and Variations of Posterior Interventricular Artery in Cadaveric Human Heart

Medical Science

**KEYWORDS :** Coronary artery, Balanced or co-dominance, posterior interventrucular artery, posterior right diagonal artery,

**Dr. Ranjana Agrawal** — Senior Resident, Department of Anatomy All India Institute of Medical Science Bhopal. (M.P.)

**Dr. Ranjit Singh Arya** — Assistant Professor, Department of Anatomy Gandhi Medical College, Bhopal (M.P.)

## ABSTRACT

*Coronary insufficiency and disturbances of coronary circulation are among the most frequent causes of death in developed countries. The Presence of coronary artery anomalies may, at times, create challenges during coronary angiography, percutaneous coronary interventions, and coronary artery surgery. Therefore normal anatomy of coronary artery and its common variations are very important when considering various surgical intervention and should be well known by cardiologist. This study is therefore aim to focus on pattern of coronary dominance and variations of posterior interventricular artery in cadaveric human heart. Present study included 50 human hearts. The origin of posterior interventricular artery is taken as the basis of dominance. The course of posterior interventricular arteries were traced by micro dissection under water method. The PIS was divided into three segments from the crux cordis to the notch of the cardiac apex according to the American Heart Association classification and the artery or arteries supplying each segment were record. it was found that there was right dominance in 86% specimens , in 8% specimens left dominance was found, co-dominance was also found in one specimen and in 4% specimens no dominance was noticed. So it may be said that there is balanced circulation found in 6% specimens. In 26% specimens Posterior Right Diagonal Artery (PRDA) was present. These observations are of practical importance as the PRDA along with the LAD together irrigate the inferior zone of the PIVS and its adjacent area .Frequency of PRDA is found greater in the present series as compared to the previous works that leads us to consider this finding as an ethnic characteristic.*

**Introduction**: In human body special circulatory organs (The heart and vascular system) are developed for transport and distribution of blood, ensuring that it is made available to all the cells in the body. Coronary arteries supply blood to the heart muscle. Greek word ko-ro-ne means anything hooked or curved and coronary means encircling in a manner of crown"[1].normally there are two coronary arteries the right and left .they arises from ascending aorta right from anterior and left from left posterior aortic sinus. The two arteries form an oblique inverted crown, in which an anastomotic circle in the atrioventricular groove is connected by marginal and interventricular (descending) loops intersecting at the cardiac apex. The main arteries and major branches are usually subepicardial, but those in the atrioventricular and interventricular grooves are often deeply sited and occasionally hidden by overlapping myocardium or embedded in it. The left coronary artery divides into left Anterior interventricular (Lt. anterior descending) artery and circumflex artery, supplies blood to Most of the left ventricle, A narrow strip of right ventricle, anterior two-thirds of the interventricular septum,Most of the left atrium, SA node(in approximately 40% cases), AV node (in approximately 20% ) .The right coronary artery branches are Conus artery, Atrial branches, Artery of the sinu-atrial node, Ventricular branches Right marginal artery ,posterior interventricular (descending) artery ,Septal branches .the area of distribution of rca are Right ventricle (except a small region to the right of the anterior interventricular groove) , posterior third of the interventricular septum, right atrium and part of the left atrium., SA node(in approximately 60% cases), AV node (in approximately 80% cases)[2]

It has been observed that the distribution of the coronary arteries in the wall of the heart does not follow a uniform pattern in all hearts and the patterns of coronary blood supply have been classified into three types viz. balanced circulation, right coronary dominance and left coronary dominance[3]. The term dominant coronary artery was introduced by Schlesinger (1940)[4]who used it to indicate the areas of heart supplied by each artery. The term right or left coronary dominance was used to show which coronary artery irrigates the heart`s diaphragmatic surface,based on the origin of the post interventriculer artery[4]. sometimes the posterior descending artery arises from right coronary artery or proximal to the acute margin of the heart and this is known as early origin of the posterior descending artery. At the crux, a characteristic inverted "U" shaped course of the right coronary artery seems as it passed over the coronary sinus and continues in the posterior atrioventricular groove to send branches to the posterior wall of the left ventricle. At this situation, the right coronary artery referred as the 'Dominant' artery.[5]

Variations in the coronary arterial system mainly affect the diaphragmatic aspect of the ventricles and reflect the relative 'dominance' of supply by the left or the right coronary artery. The term is misleading, because the left artery almost always supplies a greater volume of tissue than the right. In 'right dominance', the posterior interventricular artery is derived from the right coronary artery; in 'left dominance' it is derived from the left coronary artery. In the so called 'balanced' pattern, branches of both arteries run in or near the posterior interventricular groove. Approximately 85% of the general population is right-dominant, 8% are left-dominant, and 7% are co-dominant[6]. The heart with a balanced circulation suffer least, the left dominate most and right dominance occupy an intermediate status between the other two in coronarydisease.[7]

The RDPA or PRDA (infrequently pattern), originates from the RCA near of the acute margin of the heart and adopt an oblique path on the posterior wall of the right ventricle to reach the middle third of posterior interventricular groove contributing to the irrigation of the lower segment of the diaphragmatic heart surface.[8,9,10] .

When the PRDA originated directly from the RCA, the RMA appeared underdeveloped; the PRDA always occupied the inferior part of the PIS and appears either as continuation of a short PDA or as a replacement for a long PDA from the point where this artery leaves the PIS to enter the posterior wall of the left ventricle. The PDRA when present serves as a bridge between the RCA and the left anterior descending artery[11]

The above parameters were used in present study to determine coronary dominance. Incidences of PRDA were noted and results compared with other scholars.

**Material & Methods:** The heart specimens for this study were obtained from cadavers in the department of Anatomy of NSCB medical college, Jabalpur, India. The sample size for this study

was 50 heart specimens.

The ribs and sternum were cut, thus opening the thoracic cavity. All the great vessels were legated by thread at two places and cut in between. The parietal pericardium was incised and the heart was taken out of the pericardial cavity.

The specimens were numbered from 1 to 50 and preserved in 10% farmaldehyde solution. The dissection was done under water. The visceral pericardium was removed and by micro dissection the RCA and LCA was exposed. Then, their origin, course & the branching pattern, mainly the branch which supplied posterior interventricular septum i.e. PIVA, & its variations were noted. Red acrylic colour was used to paint the arteries to give contrast in photographs. Photographs of specimen were taken by Sony digital camera of 20.2 megapixels and labeled.

**Result:-**

**Table – 1**

**Origin of Posterior Interventricular Artery**

**N=50**

| Origin from | Number and percentage of specimens | |
|---|---|---|
| | No. | % |
| RCA | 43 | 86 |
| LCA | 4 | 8 |
| Both | 1 | 2 |
| No PIVA | 2 | 4 |

Table No. 1 shows the observation about the origin of Posterior interventricular artery to find the predominance of heart revealed that in 86% specimen, posterior interventricular artery was found to arise from Right coronary artery. In 8% specimens, (Specimen No. 5,19,23&27), it was seen to arise from Left coronary artery and in 2% specimen (Specimen No. 15) it was seen to arise from both RCA and LCA. However, in 4% specimens,(Specimen No 49&40) specimens no Posterior interventricular artery was found.

**Table – 2**

**Level of termination of Posterior Interventricular Artery**

**N=50**

| Point of termination of | Number and percentage of specimens | |
|---|---|---|
| | No. | % |
| RCA | | |
| ¼ way down PIVS | 8 | 16 |
| ½ way down PIVS | 13 | 26 |
| ¾ way down PIVS | 15 | 30 |
| At apex | 8 | 16 |
| LCA | | |
| ¼ way down PIVS | 1 | 2 |
| ½ way down PIVS | 1 | 2 |
| ¾ way down PIVS | 3 | 6 |
| At apex | 0 | 0 |

As mentioned earlier in table No. 1, PIVA originates from RCA in 86% specimens. Table No. 2 shows that the points of termination of posterior interventricular artery provided by RCA were as follows:

It was seen to terminate in 16% specimens, at a point ¼way down posterior interventricular septum. In 26% specimens, it was seen to terminate at a point½way down PIVS. In 15 (30%) specimens, it was seen to terminate at a point¾ way down PIVS and in 8 (16%) specimens, it was seen to terminate at the Apex.

The points of termination of posterior interventricular artery provided by LCA were as follows:

It was seen to terminate in 3 (6%) specimens, at a point3/4 way down PIVS; in 1 (2%) specimen it was seen to terminate at a point½ way down PIVS and in 1 (2%) specimen it was seen to terminate at ¼ ways down PIVS.

In the specimens No.6, 8, 9, 10, 24, 25, 28, 29, 32, 33, 45, 47 and 48 a different pattern of blood supply to PIVS was noted. Here upper ¼ or ½ of PIVS was supplied by posterior interventricular artery and middle & lower ¾ part of PIVS was supplied by the right posterior diagonal artery arising either from RCA or from Right marginal artery. This branch after origin was seen to run horizontally or obliquely over right posterior ventricle and divided into 2-3 branches to supply PIVS.

**Table-3**

**Coronary Artery Dominance**

**N=50**

| Coronary Artery Dominance | Number and percentage of specimens | |
|---|---|---|
| | No. | % |
| Right Dominance | 43 | 86 |
| Left Dominance | 4 | 8 |
| Co- Dominance | 1 | 2 |
| No Dominance | 2 | 4 |

Table No. 3 shows the result of the dominance of coronary arteries. It was found that there was right dominance in 43 (86%) specimens. In 4(8%), specimens left dominance was found. Co-dominance was found in 1 (2%) specimen and in 2 (4%), specimens no dominance was noticed.

**Discussion:-**

**Table-4**

**Cardiac dominance (In %)**

| Author | Cardiac Dominance | | |
|---|---|---|---|
| | Right | Left | Balanced |
| Schlesinger (1940)[4] | 48 | 18 | 34 |
| Cavalcanti (1995) [13] | 88.18 | 11.82 | - |
| B.K. Omer (1977) [12] | 53.3 | 16.7 | 30 |
| K.V. Venkateshu(2005)[14] | 68.75 | 16.66 | 14.58 |
| Fazliogullari (2010)[15] | 42 | 14 | 44 |
| Vasudeva Reddy (2013)[16] | 86.25 | 11.25 | 2.5 |
| Present study | 86 | 8 | 6 |

As shown in table No. 4, in the present study, it was found that there was right dominance in 86% specimens. Right dominance in the present study is found to be more than that of by Schlesinger (48%)[4], B. K. Omer (53.3)[12] K. V. Venkateshu (68.75%)[14.] and Fazliogullari (42%)[15]. It was found to be less than that of by Cavalcanti (88.18%)[13] and almost similar to Vasudeva Reddy[16]

Left dominance, in the present study was noted in 8% specimens and it was found to be less than that of by all the scholars listed in the table.

Co-dominance was found in 2% specimens and in 4% specimens no dominance was present. In cases of no dominance PIVA was absent and PIVS was supplied by a network of small branches from RCA and Left circumflex artery passing obliquely. Thus in the present study in 6% specimens balanced circulation (2% co-dominance and 4% no dominance) was found. Balanced dominance, in the present study, found to be less than that of by all the scholars shown in table except Vasudeva Reddy[16]. Left dominance was found to have significantly higher mortality than right dominance and mixed types[17]. Dominance also plays important role in inferior wall infarcts of the heart. Inferior wall infarcts although less extensive than anterior infarcts, are more important as they can cause various degrees of atrioventricular blocks in approximately 30% of cases. The dominant right coro-

Volume : 5 | Issue : 3 | March 2016 • ISSN No 2277 - 8179 | IF : 3.508 | IC Value : 69.48

nary artery usually supplies atrioventricular node. Therefore an inferior wall infarcts caused by occlusion right coronary artery will have higher risk of AV blocks [18]

**Table –5**
**Termination of posterior Interventricular Artery**

| Point Of Termination | James 1961[19] | Sabnis A.S. (2013)[20] | Present study |
|---|---|---|---|
| | No. (%) | No. (%) | No. (%) |
| Right Coronary Artery | | | |
| ¼ way down PIVS | 2(2) | 19(17.59) | 8(16) |
| ½ way down PIVS | 27(25) | 4(3.70) | 13(26) |
| ¾ way down PIVS | 39 (37) | 60(55.55) | 15(30) |
| At apex | 28(26) | - | 8(16) |
| Total | 96(90) | 83(76.84) | 44(88) |
| Left Coronary Artery | | | |
| ¼ way down PIVS | - | 1(0.92) | 1(2) |
| ½ way down PIVS | 5(5) | 2(1.85) | 1(2) |
| ¾ way down PIVS | 3(3) | 17(15.74) | 3(6) |
| At apex | 2(2) | - | - |
| Total | 10(10) | 20(18.51) | 5(10) |

PIVA originates from RCA in 86% specimens. It terminated in 16% specimens at a point ¼way down posterior inter-ventricular septum. In 26% specimens it terminated at a point ½ way down PIVS. In 30% specimens it terminated at a point ¾ ways down PIVS and in 16% specimens it terminated at Apex.

The points of terminations of posterior inter-ventricular artery provided by LCA were as follows:

It terminated in 6% specimen at a point ¾ ways down PIVS, in 2% specimens it terminated at a point ½ way down PIVS and in 2% specimens it terminated at a point ¼ way down PIVS.

**Table-6**
**Presence of Posterior Right Diagonal Artery (PRDA)**

| Author | Cases (in %) |
|---|---|
| Margaris et al (1997)[9] | 13.66 |
| Ballesteros LE et al (2011)[21] | 17.20 |
| Present Study | 26.00 |

In 13 (26%) specimens (Specimen Nos. 6, 8, 9, 10, 24, 25, 28, 29, 32, 33, 45, 47 and 48) a different pattern of blood supply to PIVS was noted, in these specimens upper ¼ or ½ of PIVS was supplied by posterior interventricular artery and middle & lower ¾ part of PIVS was supplied by the posterior right diagonal artery which arose either from RCA or from Right marginal artery. This branch after its origin was seen to run horizontally or obliquely over right posterior ventricle and divided into 2-3 branches to supply PIVS.

Nerantzis et al (1994)[11] & Margaris et al (1997)[9] also observed the presence of PRDA in hearts they studied. However they did not observed PRDA in hearts with left dominance. Ortale et al (2004) reported presence of PRDA in all the three types of coronary circulations.

According to Margaris et al (1997),[9] PRDA was present in 13..34 % cases with right dominant coronary circulation &in 0.32% cases with balanced coronary circulation and in none with left dominant coronary circulation.

Ballesteros LE et al (2011)[21] also noted incidence of posterior right diagonal artery in 17.2% of cases studied by him .The PDRA when present serves as a bridge between the RCA and the left anterior descending artery. When there is no RPDA, the posterior wall of the right ventricle is irrigated by small branches arising from the RCA. Remarkably, in angiographic studies RPDA can be confused with an accessory interventricular branch.

Sabnis A.S.(2013)in their study conducted on 108 hearts noted the termination of PIVA when it was b/o RCA and when it was b/o LCA in PIVS in upper one third in 19 hearts and 1 heart, at middle part in 4 and 2 hearts and at apex in 60 and 17 hearts respectively.[20]

**Conclusion:**
In present study reveals the majority of the cases observed with right coronary artery dominance (86%) compared to left coronary artery dominance (8%), co-dominance in 2% and no-dominance in 4% cases. While performing angioplasty and coronary artery bypass grafting, knowledge of dominance of artery becomes very helpful. The degree of severity of myocardial infarction is more and may lead to death in single attack if there is obstruction in the left coronary artery.

In 26% specimens Posterior Right Diagonal Artery (PRDA) was present. These observations are of practical importance as the PRDA along with the LAD together irrigate the inferior zone of the PIVS and its adjacent area. In the presence of an occlusive event of the LAD, PRDA represents a bridge that can irrigate the inferior third of the heart diaphragmatic area limiting the possibility of ischemic processes. Frequency of PRDA is found greater in the present series as compared to the previous works that leads us to consider this finding as an ethnic characteristic.

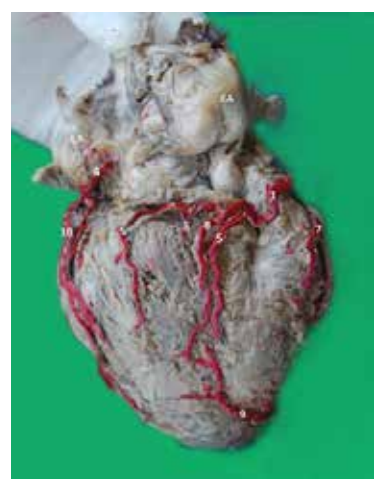

**Photograph No. 1– Posterior view. (PIVA arising from RCA)**

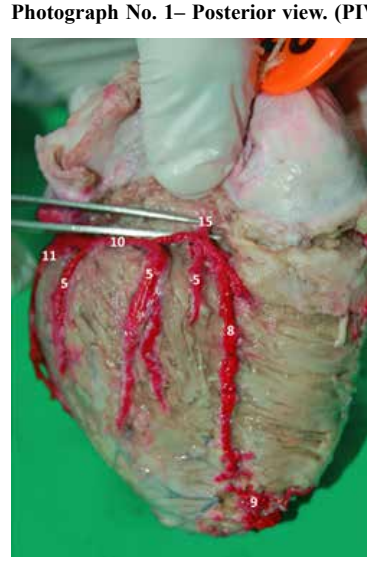


**Photograph No.2– Left dominant pattern of heart. (Posterior view)**

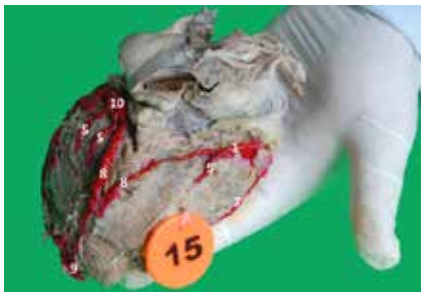


**Photograph No.3– PIVA arising from RCA & LCA both (Co-dominance)**

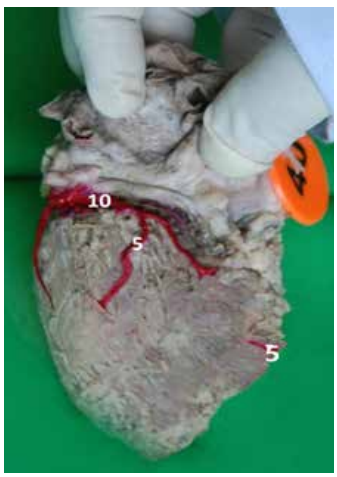


**Photograph No.4 – Absence of Posterior interventricular artery. (No dominance)**

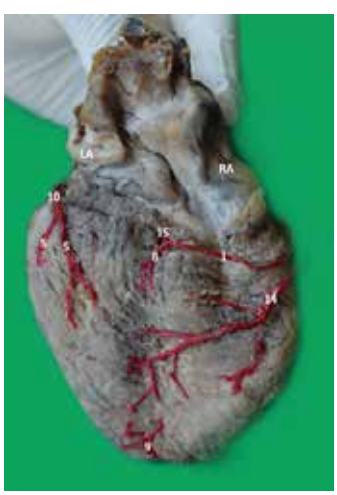


**Photograph No.5– Presence of Posterior Right Diagonal Artery. (Posterior view)**

**Key to Photographs**

1 - Right Coronary Artery
2 - Left Coronary Artery
3 - Right Conus Artery
4 - Atrial branch
5 - Ventricular branch
6 - Sinu-atrial Nodal Artery
7 - Right Marginal Artery
8 - Posterior Interventricular Artery
9 - Left Anterior descending Artery (Anterior Interventricular Artery)
10 - Left Circumflex Artery
11 - Left Marginal Artery
12 - Left Diagonal Artery
13 - Intermediate artery/ Ramus diagonalis/ Median artery
14 - Posterior Right Diagonal Artery
15 - Atrioventricular Nodal Artery
16 - Third Coronary Artery
17 - Fourth Coronary Artery
RA - Right Atrium
LA - Left Atrium
AA - Ascending Aorta
PT - Pulmonary trunk
AAS - Anterior Aortic Sinus
PAS - Posterior Aortic Sinus

**REFERENCES**

1. Co-ro-ne. Dorland's illustrated medical dictionary. 30th ed.Philadelphia: Saunders; 2000:420.
2. Standring S. The anatomical basis of clinical practice. 39th ed. Philadelphia: Elsevier Churchill Livingstone; 2005:1014-18
3. Allwork SP. The applied anatomy of the arterial blood supply to the heart in man.Anat Soci Great Britain and Ireland. 1987 August;153.
4. Schlesinger MJ. Relation of anatomic pattern to pathological conditions of the coronary arteries. Arch. Path. 1940; 30:403-415.
5. Putman CE, Ravin CE. Textbook of diagnostic imaging. 2nd ed. Philadelphia:W.B. Saunders Company; 1988:1715-22.
6. Gensini GG. Coronary Arteriography. Mount Kisco NY: Futura Publishing Co; 1975:260–274.
7. Ayer AA, Rao YG. A radiographic investigation of the coronary arterial pattern in human hearts. J Anat Soci Ind. 1957 Jun;6(1):63-67
8. Smith GT. The anatomy of the coronary circulation. Am J Cardiol. 1962;9:327-42.
9. Margaris NG, Kostopoulos KG, Nerantzis CE, Filippatos GS, Kardaras FG, Salahas AI, et al. Posterior right diagonal artery. An angiographic study. Angiology. 1997;48(8):673-7.
10. Ortale JR, Keiralla LC, Sacilotto L. The posterior ventricular branches of the coronary arteries in the human heart. Arq Bras Cardiol. 2004;82(5):468-72.
11. Nerantzis CE, Gribizi JE, Margaris NG, Antonelis JP, Salahas TI, Koroxenidis GT. Posterior right diagonal artery. Anat Rec. 1994;238(4):528-32.
12. Omar BK. Coronary artery predominance – A new parameter for its study. J AnatSoci Ind. 1977;26(2):85-90-
13. Cavalcanti JS. Anatomical variations of the coronary arteries. Arq. Bras ardiology. 1995; 65 (6): 489-92. SurgRadiol Anat. 2003;25(1):42-9.
14. Venkateshu KV. A study of arterial supply of SA node and AV node. AnatKarnataka. 2006 July;2(2):21-24
15. Fazliogullari Z, Karabulut A K, UnverDogan N, Uysal L. Coronaryartery variations and median Artery in Turkish cadaver hearts.SingaporeMed J. 2010; 51(10): 775-80
16. Vasudeva Reddy J1, Lokanadham S2 coronary dominance in south indian population. Ijmrhs. 2013; Volume 2 Issue 1 Jan-Mar 2013
17. Goldberg A, Southern D, Galbraith PD, Traboulsi M, Knudtson ML, Ghali WA. Coronary dominance and prognosis of patients with acute coronary syndrome. Am. Heart J. 2007 Dec;154(6):1116-1122
18. Amin K, Javed M, Mehmood A, Zakria M. Acute inferior wall myocardial infarction :frequency of AV block s. The Pro fessional. 2004 Jan, Feb ,March;11(1):31-37.)
19. JAMES, T. N.: Anatomy of the Coronary Arteries, New York, 1961, PaulB. Hoeber.1961
20. Sabnis AS. Morphology of posterior interventricular artery. World Research Journal of Anatomy. 2013;1(1):07-10.
21. Luis Ernesto Ballesteros, Luis Miguel Ramirez, Ivan Dario Quintero. Right coronary artery anatomy: anatomical and morphometric analysis.Brazilian Journal of Cardiovascular surgery. 26 Número 2, Abril - Junho, 2011 ISSN (Impressa): 0102-7638.