ORIGINAL RESEARCH PAPER

Volume-8 | Issue-1 | January-2019 | PRINT ISSN No 2277 - 8179

INTERNATIONAL JOURNAL OF SCIENTIFIC RESEARCH

ASSESMENT OF INCIDENCE AND RISK FACTORS OF PNEUMOTHORAX IN CT GUIDED TRANSTHORACIC BIOPSY/FNAC

Radiodiagnosis

Dr. P.balakrishna Nizam's Institute Of Medical Sciences.

Dr.k.tejasimha* Nizam's Institute Of Medical Sciences. *Corrosponding Author

Dr. Sujata Patnaik Nizam's Institute Of Medical Sciences.

Dr. Rammurti .S Nizam's Institute Of Medical Sciences.

ABSTRACT

INTRODUCTION: CT guided transthoracic biopsy/FNAC is integral in the diagnosis and treatment of many thoracic diseases, and is an important alternative to more invasive surgical procedures. Complications include pneumothorax, haemoptysis, haemothorax, infection, and air embolism, with the most common complication as pneumothorax.

AIMS AND OBJECTIVES: To know the incidence and risk factors of pneumothorax in patients undergoing CT guided transthoracic biopsy/FNAC at our institute.

MATERIAL AND METHODS: Retrospective analysis of 100 patients presented with lung and mediastinal mass lesions who underwent CT guided transthoracic biopsy/FNAC was done. Out of 100 cases, male patients were 75 and female patients were 25 with maximum number of cases in age group of above 60 years and 40 to 60 years respectively. Out of 100 cases, 93 patients presented with lung lesions and 7 patients with mediastinal lesions. Based on the size of lesion, number of cases with size less than or equal to 3 cm were 12, between 3-6 cm were 39 and above 6 cm were 49.

RESULTS: Out of 100 cases, 22 patients developed pneumothorax post procedure and all were those presented with lung lesions. No patient presented with mediastinal lesion developed pneumothorax. Percentage of cases that developed pneumothorax with size of the lesion less than 3 cm were 33 %, between 3-6 cm were 18 % and above 6 cm were 22.4 %. Maximum number of cases that developed pneumothorax were in elderly age group and in lesions that are in close contact with the chest wall.

CONCLUSION:

·Overall incidence of pneumothorax encountered in our study is around 22%

·Risk factors associated with pneumothorax are categorized as patient factors, lesion factors and technical factors. Among patient factors; elderly age group, history of smoking and known COPD cases; Among lesion factors; smaller lesions(<3cm), increased needle course in the lung ; Among technical factors; increased pleural punctures in single biopsy and repeat biopsies are associated with higher risk of developing pneumothorax.

KEYWORDS

INTRODUCTION :

CT-guided percutaneous trans thoracic needle biopsy is an established and effective procedure in selected patients with suspected lung pathology . With recent advances in imaging technology, biopsy technique, yield and efficacy of percutaneous needle biopsy of the lung (PCNB) has also improved (1,2). PCNB offers advantages over bronchoscopy guided biopsy especially when lesions are peripheral and less than 2cm in diameter. Extensive experiences documented that PCNB as a safe and accurate procedure with limited morbidity and rare mortality. Recent advances in treatment options for lung cancer requires detailed histopathologic as well as immunohistochemistry evaluation of the lung lesions. Therefore an accurate biopsy sampling is essential and in order to ensure proper targeting of the lesion, image guidance is necessary.

Per cutaneous trans thoracic needle biopsy, depending on type of needle used and material provided, categorized as fine needle aspiration cytology (FNAC) providing samples for cytology, which can accurately diagnose malignancy, and core needle biopsy (CNB), providing histological material, for further evaluation of lesion by immunohistochemistry and cytochemistry; thus improving overall diagnostic accuracy (3-5).

FNAC needles are usually 20-25 gauge and provide material for cytological and microbiological examination. Core biopsy needles provide linear tissue sections which are suitable for histological evaluation. These are larger in caliber than aspiration needles; however, nowadays small caliber (18-20 gauge) automated cutting needles are also available. Earlier most CT-guided lung biopsies were performed by fine-needle aspiration and were useful in differentiating benign and malignant lesions. Recently, the use of tissue core biopsy utilizing an automated cutting needle has been implemented in an attempt to further enhance the diagnostic accuracy (6,7). The diagnostic accuracy of FNAC is almost as good as core biopsy in the diagnosis of malignant lesions, especially if an onsite cytopathologist is present. However, for the diagnosis of benign lesions and lymphoma, core biopsy is preferred (8).

Per cutaneous needle aspiration/ biopsy is an out patient procedure , although the reported complication rate varies greatly (9,10). Complications were classified as minor or major according to the Society of Interventional Radiology (SIR) Guidelines (11). Minor complications consisted of pneumothorax without need for intervention, ground glass opacity around the target diagnosed as pulmonary hemorrhage, and transient hemoptysis. Major complications consisted of pneumothorax requiring intervention, hemothorax, air embolism, needle tract seeding, and death. Among these, pneumothorax is the most frequent complication.

Pneumothorax is defined as any visible retraction of the pleural surface from the parietal pleura detected on CT scans or chest radiographs. Pneumothorax detected immediately after the biopsy while the patient was still on the CT scan table was graded as mild (lung surface retraction < 2 cm), moderate(lung surface retraction 2– 4 cm),or severe (lung surface retraction > 4 cm)(12). If a pneumothorax was identified and the patient was asymptomatic, aspiration was performed by reinsertion of the coaxial needle guide. Symptomatic pneumo- thoraces with lung surface retraction of > 2 cm were treated by chest tube insertion.

Our study is mainly to find the incidence of pneumothorax in patients undergoing CT guided FNAC/biopsy at our institute and to analyse the risk factors for developing pneumothorax.

MATERIALS &METHODS :

The study was conducted in the Department of Radiology and Imageology, Nizam's Institute of
Medical Sciences, Hyderabad.

STUDY DESIGN

It is a retrospective study.

STUDY PERIOD AND DURATION

Over a period of 9 months (November 2017 to August 2018)

SOURCE OF DATA
The patients who were referred to the Department of Radiology and Imageology, Nizam's Institute of Medical Sciences over a period of 9 months (November 2017 to August 2018) wereincluded.

CT images were retrieved from the imaging database and imaging findings were reviewed by a radiologist with expertise in lung imaging.

SAMPLE SIZE
A total of 100 cases are included in the study

INCLUSION CRITERIA
All the patients with lung lesions referred for CT guided biopsy who were -cooperative and able to hold breath for a short while.
had no bleeding tendency or coagulopathy.

EXCLUSION CRITERIA
Pregnant womenUncorrected coagulation abnormalities
Inaccessible lesions with a high risk of pneumothorax/hemothorax.

ETHICAL CLEARANCE
The study was conducted in the Department of Radiology and Imageology, Nizam's Institute of Medical Sciences, Hyderabad, following approval of institutional scientific and ethics committee.

PREPARATION OF THE PATIENT
After careful review of existing contrast CT images of chest; patients were selected and given appointment for CT guided lung biopsy.

A good quality baseline contrast-enhanced CT was reviewed before the procedure for the lesionsize, location, lesion vascularity, and important structures located in the biopsy path. Thecondition of the underlying lung is evaluated for the presence of emphysema and bullous lesions.

INFORMED CONSENT
Patients fulfilling selection criteria were informed about the procedure and its complications and a written informed consent was obtained.

PRE-PROCEDURE WORKUP AND INVESTIGATIONS
Screening with the following tests was performed for every patient before taking up forbiopsy
Human immunodeficiency virus (HIV)
Hepatitis B surface antigen (HbSAg)
Hepatitis C Virus (HCV)
Activated partial prothrombin time (aPPT)
Prothrombin time (PT)
International normalized ratio (INR)
Bleeding time
Clotting time
Only if the tests were normal ,the procedure was undertaken.

PROCEDURE
CT guided biopsy of all lung lesions were performed by Radiologists in the Department of Radiology and Imageology at Nizam's institute of medical sciences .

EQUIPMENT USED
16 slice MDCT scanner (Brilliance16, Philips medical systems, Cleveland, USA)

BIOPSY REQUISITES
Biopsy tray : sterile fenestrated drape, guaze, cotton swabs, sponge holder forceps Betadine solution1-2% Lignocaine Automated Bard biopsy gun 18/20g Coaxial needle Hypodermic needles Syringes Sample bottles with Formaline

MONITORING AND RESUSCITATIVE MEASURES:
Sphygmomanometer.
ECG monitor.
Pulse oximeter.
Working IV line - for administration of emergency medication.
Oxygen.
Suction equipment.
Oral and nasal airways.
AMBU bag.
Instruments for management of pneumothorax- Chest tubes, connectors and tubings.
Resuscitation cart.

PATIENT POSITIONING AND INSTRUCTIONS
As patient comfort is essential for maintaining a designated position which is crucial for accurateneedle placement, supine/prone positioning with arms by the side was preferred depending on the position of the lesion and planned approach route. Decubitus position was chosen only ifabsolutely necessary as patients drift out of position easily.

IMAGING TECHNIQUE:
A scanogram /topogram of the chest was obtained and the region of interest scanned by using ashort helical scan during breath hold to identify and target the lesion. The lesion was further assessed for its feasibility.

FEASIBILITY OF LESION:
Size and location of the lesion - Small lesion in favourable location was preferable to a largerlesion in less desirable location.. Favourable locations for lesion selection included :
Pleural based lesions - as aerated lung is not violated.
Upper lung zone lesion - as they move little with respiration.
Relatively peripheral lesion - perpendicular puncture directed at centre as lung at the puncture site is ventilated as lesion itself will probably have obstructed direct bronchial supply to portion of lung immediately peripheral to nodule.

NON FEASIBILITY OF LESION:
The following were considered as non-feasible lesions for CT guided biopsy Small lesions abutting the heart - cardiac motion.Nodules in superior portion of right middle lobe just under the dome shaped minor fissure.Small lesions deep in costophrenic angles - as respiratory movement is more, thereforedecreases chances of accuracy.

AREAS THAT WERE AVOIDED DURING CT GUIDED BIOPSY INCLUDED:
Areas of necrosis or adjacent post obstructive pneumonitis.
Crossing of fissures.
Blebs and bulla - due to increased risk of pneumothorax.
Large vessels.

TECHNIQUE:
Table position of the most suitable axial image was noted for marking the biopsy plane .Thepatient was moved in the CT gantry at the same table position and this level was marked usingmettalic marker with the help of a laser light emitted from the scanner. The computer's cursor was used to measure the lesions dimensions and its distances to the metallic marker positioned atthe skin surface. The exact place of the needle introduction was obtained through a superficial marking with surgical pen, correlating the metallic marker and the laser ray that marks the site onpatients, with axial tomographic cuts. Local area was cleaned with betadine solution and draped.Local anesthesia with 1% lidocaine was applied. After positioning the needle, computed tomography scanning was done to confirm or modify the needle position in relation to thelesion.

In our institute, we used the coaxial biopsy set containing a 16 or 19-gauge guiding needle withan 18 or 20-gauge automated biopsy gun respectively for obtaining tissue cores. Needle lengthwas selected depending on depth of lesion from the skin. The guiding needle was placed in thesoft tissue of the chest wall and all necessary adjustments were done to align the needle perfectlywith the target lesion prior to piercing the pleura. Then, the parietal pleura passed with a singlepuncture and the needle was placed into lesion. Then, the inner part of the coaxial needle was removed. Then, the biopsy gun needle was inserted into the lesion through the coaxial needle.Then, multiple “tru-cut” core specimens (at least 3) were obtained and sent in 10% formaline solution for histopathological examination.

POST PROCEDURAL CARE
Immediate post procedure compression was given for 5 minutes at the site of intervention to stop bleeding and a dressing was applied . The patient was reassured and blood pressure , pulse rate and respiratory rate were monitored. In case of pain oral analgesics were given. Check CT images were obtained to detect any post biopsy complication.

The patient was kept for observations for 3hours . If there found to have small pneumothorax asecond control CT scan was performed 1 h after the procedure. All cases of pneumothoraxresolved with conservative management and did not required ICD tube placement.

OBSERVATION AND ANALYSIS

A total of 100 cases are included in the study, of which 72 cases underwent core biopsy and 28 cases FNAC. Of 72 biopsy cases; 6 are repeat biopsies. Pneumothorax is noted in 22 cases and all are managed conservatively.

DEMOGRAPHICS :

Of the 100 patients, 75 are males and 25 females with M:F = 3:1. The age of the patientsranged from 16yrs to 80yrs with a mean age of 48yrs. Most of the subjects are in 6th to 7thdecade of their life.

The age, gender distribution of the patients and percentage of pneumothorax is provided in the Table.1

Age (in years)	Males	Females	Total	Pneumothorax	Percentage
0-20	4	2	6	0	0
21-40	6	6	12	2	16.6
41-60	25	13	38	6	15.7
60-80	40	4	44	14	31.8
Total	75	25	100	22	

Among 100 patients ,number of cases with history of smoking (for > 10 pack years), known COPD and percentage of pneumothorax are depicted in table no.2

	No. of cases	Pneumothorax	Percentage
Smoking	34	14	41.1
COPD	18	12	66.6

LESION DATA :

Lesion data are provided in table no.3

	No. of cases	pneumothorax	percentage
1.Lung lesions Mediastinum lesions	93 7	22 0	23.6 0
2. Distribution of lung lesions a)sub pleural b)intra parenchymal	32 61	4 18	12.5 29.5
3. lesion size <3cm 3-6cm >6cm	12 39 49	4 7 11	33.3 17.9 22.4
4. depth of lesion from skin surface 1-4cm >4cm	21 89	2 20	9 22.4
5. type of PCNB FNAC Core biopsy	28 72	6 16	21.4 22.2
6. no. of pleural punctures One Two three	62 34 3	9 10 3	14.5 29.4 75

Among 22 cases presented with pneumothorax; 15 had mild (<2cm), 5 had moderate (2-4cm) and 2 had severe (>4cm) pneumothorax. Mild and moderate pneumothorax are managed conservatively in the CT observation room by adequate oxygenation and appropriate positioning. 2cases of severe pneumothorax are referred to EMD for further management by respiratory medicine and both are also managed conservatively. No case of pneumothorax encountered in our study required chest tube insertion.

RESULTS :

Of total 100 cases, pneumothorax is seen in 22 cases with an incidence of 22%. Based on our study, we are able to categorize the risk factors responsible for development of pneumothorax as patient factors, lesion factors and technical factors.

PATIENT FACTORS :

Elderly individuals, patients with h/o smoking (>10pack years), and known COPD cases are at higher risk of developing pneumothorax. No association between gender and development of pneumothorax noted.

LESION FACTORS :

In our study; of total 100 cases, 93 had lung lesions and 7 had mediastinal lesions. Pneumothorax is seen in only lung lesions. Incidence is more in intraparenchymal lesions when compared with subpleural lesions. As depth of lesion from skin surface increases, risk of developing pneumothorax also increased. Smaller lesions of <3cm showed relatively higher risk of developing pneumothorax .

TECHNICAL FACTORS :

Repeat biopsies and increased pleural punctures at single biopsy showed higher risk of developing pneumothorax. In our study both FNAC and core biopsy showed relatively similar incidence of pneumothorax.

DISCUSSION :

Incidence of pneumothorax in our study is 22% which is with in the range of 17-24.4% reported in the literature(13-16).

The results of our study showed that elderly individuals and patients with past history of smoking or known COPD cases are at higher risk of developing pneumothorax after percutaneous needle biopsy. In a study conducted by chor-shin lim et al in 2014 stated that The presence of chronic obstructive pulmonary disease and a history of unilateral surgery both have been shown to increase the rate of pneumo- thorax after CT-guided biopsy (17). These authors also found that increased age, supine position, and history of smoking all were associated with increased rate of pneumothorax.

Our results indicated that lesion size <3cm and depth of lesion >4cm from skin surface was associated with an increased risk of pneumothorax rate.. Prior studies stated that the greater lesion depth and smaller lesion size are associated with increased risk of pneumothorax(18,19, 20–23). Nakatani etal(24) reported that smaller lesion size and greater lesion depth were associated with a higher incidence of pneumo- thorax. Guptaetal(25) reported that lesions < 2 cm contacting the pleura were associated with a pneumothorax rate of about 63%. Kakizawaetal(26) examined the severity of pneumothorax after CT-guided biopsy; on multivariate analysis, lesionlocation, pleural contact, number of pleural punctures, and number of samples obtained were associated with the severity of pneumothorax. Minetal(27) found that lesion size and distance from the pleura were associated with pneumothorax risk. Liet al(28) found that a lesion-pleural distance < 2.1 cm was correlated with the highest rate of pneumothorax. It has been suggested that an increase of pneumothorax rate associated with small lesions is likely due to the up-and-down movement of the needle tip during aspiration, which results in unintentional laceration to the surrounding lung tissue.

Our study showed that there is no significant difference in incidence of pneumothorax between FNAC and core needle biopsy. Yao et al. (29) concluded in a systematic review comparing FNA with core biopsy that no significant difference in complication rate between these techniques exists. They also concluded that core biopsy is generally reported to have a somewhat higher diagnostic performance compared to Fine Needle Aspiration, especially in identifying histological subtypes; the evidence is insufficient to support a difference.

LIMITATIONS :

- Presence of underlying lung disease except for emphysema is not recorded.
- We cannot draw any conclusion regarding needle size; because 18 gauze was used in all cases of core biopsies and 22 gauze is used in all FNAC cases.
- Comparison of complication rates with non coaxial technique cannot be performed as all cases are performed with co-axial technique.

CONCLUSION :

- Overall incidence of pneumothorax encountered in our study is around 22%
- Risk factors associated with pneumothorax are categorized as patient factors, lesion factors and technical factors. Among

patient factors; elderly age group, history of smoking and known COPD cases; Among lesion factors; smaller lesions(<3cm), increased needle course in the lung ; Among technical factors; increased pleural punctures in single biopsy and repeat biopsies are associated with higher risk of developing pneumothorax.

ILLUSTRATIONS

CASE 1 :

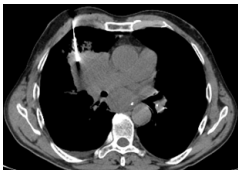
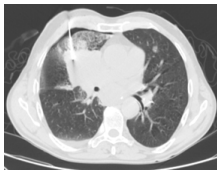
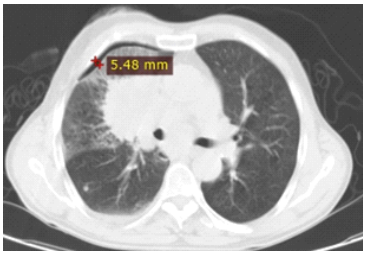

CT guided FNAC of right hilar mass in a 60Y/M patient complicated with mild pneumothorax which was managed conservatively. HPE revealed SQUAMOUS CELL CARCINOMA.

CASE 2 :


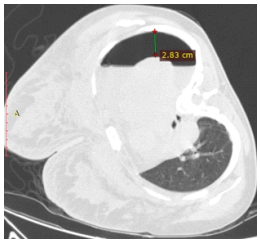

CT guided biopsy of consolidation in right upper lobe in 31Y/F; complicated with moderate pneumothorax. HPE revealed non specific pathology

CASE 3 :


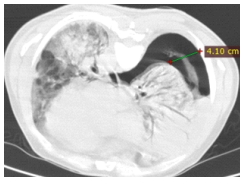

55Y/M presented with bilateral non resolving pneumonia. CT guided biopsy of consolidation in right lower lobe complicated with severe pneumothorax. patient shifted to EMD & managed conservatively. HPE revealed organizing pneumonia

CASE 4:

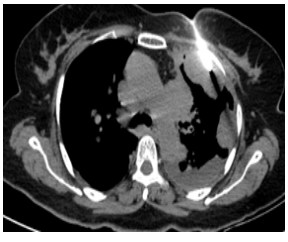
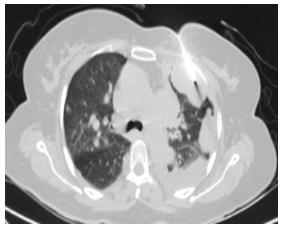

CT guided biopsy of pleural based nodule in left upper lobe is done. No pneumothorax is noted. HPE revealed metastasis from ovarian carcinoma.

CASE 5 :

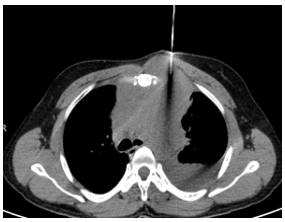
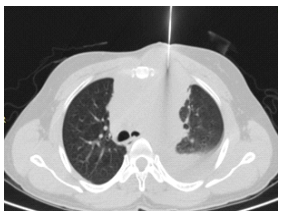

CT guided biopsy of anterior mediastinal mass in 32Y/M is done. No pneumothorax is noted. HPE revealed lymphoma.

CASE 6 :


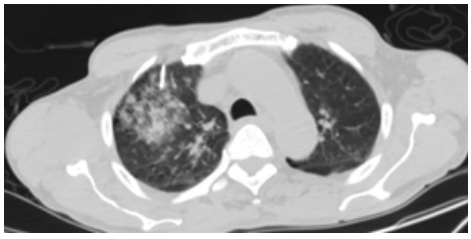
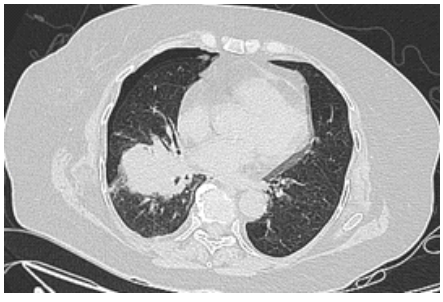

50Y/M, K/C/O COPD presented with non resolving pneumonia in right upper lobe. CT guided FNAC complicated with mild pneumothorax.

REFERENCES :

1. LaurentF,LatrabeV,VergierB, MontaudonM,Vernejoux JM, Dubrez J. CT-guided trans thoracic needle biopsy of pulmonary nodules smaller than 20mm:resultswithanautomated20-gaugecoaxialcuttingneedle. Clin Radiol2000;55:281–287.
2. GuimarãesMD,deAndradeMQ,daFonteAC,ChojniakR,Gross JL.CT-guided cutting needle biopsy of lung lesions—an effective procedure for adequate material and specific diagnosis. EurJRadiol 2011;80:e488–e490.
3. Komiya T, Kusunoki Y, Kobayashi M, et al. Transcutaneous needle biopsy of the lung. Acta Radiol 1997;38:821-5.
4. Westcott JL, Rao N, Colley DP. Transthoracic needle biopsy of small pulmonary nodules. Radiology 1997;202:97-103.
5. Greif J, Marmur S, Schwarz Y, et al. Percutaneous core needle biopsy vs. fine needle aspiration in diagnosing benign lung lesions. Acta Cytol 1999;43:756-60.
6. Boiselle PM, Shepard JA, Mark EJ, et al. Routine addition of an automated biopsy device to fine needle biopsy of the lung: a prospective assessment. AJR Am J Roentgenol 1997;169:661-6.
7. Klein JS, Salomon G, Stewart EA. Transthoracic needle biopsy with a coaxially placed 20-gauge automated cutting needle: results in 122 patients. Radiology 1996;198:715-20.
8. Cham MD, Henschke CI, Yankelevitz DF. Biopsy procedures of the lung, mediastinum, and chest wall. Handbook of interventional radiologic procedures. Wolters Kluwer/Lippincott Williams & Wilkins, 2011:478-85.
9. Cardella JF, Bakal CW, Bertino RE et al (1996) Quality improvement guidelines for image-guided percutaneous biopsy in adults: society of cardiovascular & interventional radiology standards of practice committee. J Vasc Interv Radiol 7:943–6
10. Manhire A, Charig M, Clelland C et al (2003) Guidelines for radiologically guided lung biopsy. Thorax 58:920–36
11. Sacks D, McClenny TE, Cardella JF, Lewis CA (2003) Society of interventional radiology clinical practice guidelines. J Vasc Interv Radiol 14:S199–202.
12. Yeow KM,SeeLC,LuiKW,etal.Riskfactorsforpneumothoraxand bleedingafterCT-guidedpercutaneouscoaxialcuttingneedlebiopsyof lung lesions.JVascIntervRadiol2001;12:1305–1312.

13. Covey AM, Gandhi R, Brody LA, Getrajdman G, Thaler HT, Brown KT. Factors associated with pneumothorax and pneumothorax requiring treatment after percutaneous lung biopsy in 443 consecutive patients. J Vasc Interv Radiol 2004; 15:479–483
14. Saji H, Nakamura H, Tsuchida T, et al. The incidence and the risk of pneumothorax and chest tube placement after percutaneous CT-guided lung biopsy: the angle of the needle trajectory is a novel predictor. Chest 2002; 121:1521–1526
15. Yeow KM, Su IH, Pan KT, et al. Risk factors of pneumothorax and bleeding: multivariate analysis of 660 CT-guided coaxial cutting needle lung biopsies. Chest 2004; 126:748–754
16. Khan MF, Straub R, Moghaddam SR, et al. Variables affecting the risk of pneumothorax and intrapulmonal hemorrhage in CT-guided transthoracic biopsy. Eur Radiol 2008; 18:1356–1363
17. Chor-Shen Lim,MD,Lan-EngTan et al. Risk Factors of Pneumothorax after Computed Tomography–Guided Coaxial Cutting Needle Lung Biopsy through Aerated versus Nonaerated Lung. http://dx.doi.org/10.1016/j.jvir.2014.03.031
18. Cox JE, Chiles C, M cManus CM, Aquino SL, Choplin RH. Transthoracic needle aspiration biopsy: variables that affect risk of pneumothorax. Radiology1999;212:165–168.
19. Laurent F, MichelP, LatrabeV, TunondeLaraM, MarthanR. Pneumo- thoraces and chest tube placement after CT-guided transthoracic lung biopsy using a coaxial technique: incidence and riskfactors. AJR AmJ Roentgenol 1999;172:1049–1053.
20. KazerooniEA, LimFT, MikhailA, MartinezFJ. Risk of pneumothorax in CT-guided trans thoracic needle aspiration biopsy of the lung. Radiology 1996; 98:371–375
21. Ko JP, ShepardJO, DruckerEA, etal. Factors influencing pneumo- thorax rate at lung biopsy: are dwell time and angle of pleural puncture contributing factors? Radiology2001;218:491–496. 22. Yeow KM, SuIH, PanKT, etal. Risk factors of pneumothorax and bleeding: multivariate analysis of 660CT-guided coaxial cutting needle lung biopsies. Chest 2004;126:748–754.
23. Yeow KM, SeeLC, LuiKW, etal. Risk factors for pneumothorax and bleeding after CT-guided percutaneous coaxial cutting needle biopsy of lung lesions. J Vasc Interv Radiol 2001;12:1305–1312.
24. Nakatani M, TanigawaN, KariyaS, KomemushiA, YagiR, Sawada S. Analysis of factors influencing accuracy and complications in CT- guided lung biopsy. Minim Invasive Ther Allied Technol 2012;21: 415–422.
25. GattinoniL, CaironiP, PelosiP, GoodmanLR. What has computed tomography taught us about the acute respiratory distress syndrome? Am J Respir CritCare Med2001;164:1701–1711.
26. Kakizawa H, ToyotaN, HiedaM,etal. Risk factors for severity of pneumothorax after CT-guided percutaneous lung biopsy using the single-needle method. Hiroshima J Med Sci 2010;59:43–50.
27. Min L, XuX,SongY, etal. Breath-hold after forced expiration before removal of the biopsy needle decreased the rate of pneumothorax in CT-guided transthoracic lung biopsy. Eur J Radiol 2013;82: 187–190.
28. Li Y,DuY, YangHF, YuJH, XuXX. CT-guided percutaneous core needle biopsy for small (<20 mm) pulmonary lesions. Clin Radiol 2013;68: e43–e48.
29. Yao X, Gomes MM, Tsao MS, Allen CJ, Geddie W, Sekhon H (2012) Fine-needle aspiration biopsy versus core-needle biopsy in diagnosing lung cancer: a systematic review. CurrOncol 19:e16–27.