ORIGINAL RESEARCH PAPER

Volume-8 | Issue-4 | April-2019 | PRINT ISSN No 2277 - 8179

INTERNATIONAL JOURNAL OF SCIENTIFIC RESEARCH

ASSESSMENT OF POTENTIAL RISK OF LINGUAL PLATE PERFORATION ON VIRTUAL IMPLANT PLACEMENT IN POSTERIOR MANDIBULAR REGION : A COMPUTER SIMULATION STUDY.

Clinical Research

Dr. Namrata Trivedi PG Student, Department of Periodontology and Implantology, CDSRC, Ahmedabad.

Dr. Anita Panchal* MDS, HOD and Professor, Department of Periodontology and Implantology, CDSRC, Ahmedabad. *Corresponding Author

Dr. Riddhi Gandhi MDS, Senior Lecturer, Department of Periodontology and Implantology, CDSRC, Ahmedabad.

Dr. Pritesh Ruparelia MDS, Professor, Department of Oral Medicine and Radiology, CDSRC, Ahmedabad.

Dr. Bhaumik Nanavati MDS, Reader, Department of Periodontology and Implantology, CDSRC, Ahmedabad.

ABSTRACT

Background: Dental implant therapy has become an accepted and predictable treatment modality for replacement of missing teeth. Anatomical features such as lingual undercut is common finding in the posterior mandibular region which is difficult to manage at times. This computer simulation study investigates incidence of lingual plate perforation in posterior mandibular edentulous first molar region and the risk of perforation in the area of lingual concavity by virtual implant placement. Methods: 102 CBCT were selected from the image database. Implants of different dimensions were placed using computer software and proximity between implant tip and lingual plate was measured using digital calliper for three types of mandibular cross sectional morphology (undercut(U), parallel(P) and convergent(C)) to assess incidence of lingual plate perforation.
Results: 110 sites were available for analysis. The overall probability of perforation was 1.3% to 1.4%. Most implants which were within 1 mm from lingual plate occurred in sites with lingual concavity in type U-ridge.
Conclusion: With proper diagnosis and treatment planning with the help of CBCT, most implant surgeries can proceed uneventfully and fulfill functional and esthetic demands.

KEYWORDS

lingual concavity, lingual plate perforation, Cone beam computed tomography, dental implant, posterior mandible

INTRODUCTION:

With the introduction of dental implant and the emergence of concept of osseointegration, it has become an acceptable and predictable treatment modality for replacement of missing teeth. Cross sectional images of CBCT make the identification of undercuts in the alveolar bone easy.[1] Zarb et al. suggested that, for the mandibular posterior region diameter of implant should be atleast 4 mm wide to withstand sufficient bite load.[2]

Dental implant position follows the long axis of occlusal forces so as to place the implant in the ideal prosthetically driven position in the posterior mandibular region, because bone can resist compression forces better than tensile and shear stresses.[3,4] Lingual undercut is common finding of the posterior mandibular region which is difficult to manage at times.[5] CBCT is a vital tool for computer guided implant surgeries which provides with high resolution.[6,7]

METHODS:

Source of Patients and Image Data: The cone beam computed tomography images used in this study were sourced from the patients who were advised implant retained restorations in College of Dental Sciences And Research Centre from June 2017 to July 2018 and underwent CBCT assessment. The study was approved by institutional review board.

Image Acquisition and Patient Confidentiality: The CBCT scans of each individual were made anonymously and transferred to a secured file in a password protected personal desktop computer equipped with an implant planning software programme (CS 3D Imaging V3.5.18). No patients were required to take the CBCT images deliberately for this study. The imaging parameters were set at 90 kvp, 10 mA, scan time 20 seconds, resolution 0.4 mm, and a field of view that varied based on the region scanned. A list with codes and corresponding names were created and and saved in encrypted file. Thus the patients confidentiality was protected and yet retrievable if needed.

Image data to be included in the study met the following criteria: The outline of the mandible and inferior alveolar canal had to be easily identified. The patient should have one missing mandibular first molar. The adjacent teeth present (second premolar and second molar) to the missing molar had to be fully erupted and normally positioned (the imaginary line connecting the cusp tips of canines, central groves of premolars, and molars was generally smooth). In order to provide information for proper implant angulation, maxillary teeth opposing the missing mandibular first molar must be present. The edentulous mandibular first molar region must have sufficient horizontal bone width (at minimum one site along length of available bone) for implant placement. (for example, for implant placement of 5 mm the horizontal bone width must be >7 mm). The edentulous mandibular first molar region must have sufficient vertical bone height (measured from virtual implant platform to the superior border of inferior alveolar nerve canal) for implant placement. (for example, for the implant placement of 9 mm and 11 mm the vertical bone height must be >11 mm and >13 mm respectively so as to leave the safety margin of 2mm between the implant and superior border of inferior alveolar nerve canal.)

Image data are excluded under following conditions: Unclear or unrecognizable data due to scattering or beam hardening artefacts or other reasons.

The tooth region being studied has no sufficient room (inter-dental space) or bone mass to support implant cultivation as mentioned in the inclusion criteria. A pathologic lesion found in posterior mandibular region. The adjacent teeth to missing mandibular first molar (mandibular second premolar and mandibular second molar), was not fully erupted and not in normal position.

Virtual Implant Placement and Measurement: In the present study, mandibular first molar, edentulous region was the site of interest. Based on inclusion and exclusion criteria, images were selected. All of the image data analysis and measurements were inspected by 2 calibrated examiners. After calibration, and disagreement in CBCT scan, selection was resolved through discussion.

Parallel root form implant were selected from the implant database

available within the software (CS 3D imaging) which was 4 and 5 mm in diameter for first molar. The implants of different dimensions were placed at the same site depending on the ridge width and height. The implant was virtually placed on the basis of the following criteria to ensure the reproducibility of orientation and rigid implant placement, without considering lingual ridge boundaries. Bucco-lingually, the virtual implant centre was positioned along an imaginary connection line of the central fossa of each existing adjacent tooth or mid-crestal ridge. Mesio-distally, implant was placed 3 mm away from the roots of the second premolar in the middle of the edentulous ridge. The mesio-distal and bucco-lingual angulation depended on the axis of virtual implant parallel to the long axis of the existing tooth, perpendicular to the curvature of the mandibular occlusal plane. The functional cusps of the opposing teeth were placed in the centre of the implant so as to avoid placing the virtual implant lateral or medial to Inferior Alveolar Canal(IAC), which given a large mandibular width is possible. The implant position was verified from three dimensional and different cross sectional views.

The distance between the implant tip and the lingual plate(S) was measured with a digital calliper accurate to two decimals. Lingual perforation was determined when the implant was out of the plate. This was calculated for each implant dimension.

Mandibular Cross-sectional morphology assessment and position of lingual concavity: On the selected cross-sectional image, only the region above a horizontal line 2mm coronal to the superior border of the Inferior Alveolar Nerve(line A) was evaluated because the implant is generally recommended to be placed with at least 2 mm above the IAN (Sammartino et al. 2008).[8] Point A was the intersection be between line A and the lingual plate. For morphologic characterization of this area, the bucco-lingual width 2mm apical to the alveolar crest and at the level of line A was measured. The vertical distance from alveolar crest to line A was also measured. All variables were measured by a digital ruler provided by the same software.

In order to identify the mandibular ridge shape on the axial sections, three types of mandibular morphology were determined in the axial section: Convergent (C) type: the base of the ridge was wider than its crestal part. Parallel (P) type: a more or less parallel ridge form. Undercut (U) type: a ridge with a narrow base to a wider crest with a prominent point on the lingual plate, thus causing a lingual undercut.

Mean and Standard deviation of each measurement was calculated. To compare among the three different types of morphology, one way analysis of variance test was used. The level of statistical significance was set at $P<0.05$. All statistical analysis were performed using a statistical software.

RESULTS:

The study comprised of 158 CBCT obtained from the image database of the patients who were screened, out of which 102 CBCT matched the inclusion and exclusion criteria consisting of 34 males and 68 females. Out of 102 CBCT, 110 sites were available for analysis, because of the presence of bilateral missing mandibular first molars. Four different dimensions of implants were virtually placed. 4x9 mm, 4x11 mm, 5x9 mm, 5x11 mm. When 4x9 and 5x9 mm implants were selected no perforation occurred. However, when implants of 4x11 and 5x11 mm implants were placed 1 perforation occurred in undercut(U) type ridge as shown in Table 1.The incidence of lingual plate perforation was 1.3% to 1.4%. Frequency distribution of implant position relative to lingual plate i.e, <2mm, <1mm, <0mm with different implant size and threshold among three morphology types is shown in table 1. Most of the implants, which were <1mm from the lingual plate were found in U type, the incidence being 3.9% to 8.5%. In the undercut type, the lowest mean distance was found in the U type being -----which did not reach statistical significance ($P>0.05$).

DISCUSSION:

The presence of deep lingual concavity in the posterior mandibular region presents the risk of lingual cortical bone perforation during implant placement needs special attention. In the present study the predicted risk of lingual plate perforation depending on the diameter and height of implant was estimated to be 1.3 to 1.4%. In a study by Huang et al. in 2015, Computed tomographic images of 300 patients (1,279 teeth) were analyzed in regard to the shape of the mandible (convergent, parallel, or undercut type), dimensional parameters of lingual concavity (angle, height, depth) and its relation to the inferior alveolar canal (zones A, B, C), distance from root apex to inferior alveolar canal, and probability of LPP. Risk of lingual plate perforation in the first molar region was found to be 2.1%, most common in the undercut ridge when implant of 5 mm in diameter was placed.[6] A similar study was carried out by Chan et al. in 2011 in 103 subjects, for easier identification of ridge shape and identifying potential perforation risk.[9] The risk of lingual plate perforation was 1.1% to 1.2% which occurred in the undercut ridge when parallel implants were placed with 4-5 mm width and 10-12 mm length were placed in edentulous ridges >5-6 mm in width and >12-14 mm in height.[10]

The most common ridge form was undercut type in the present study with the prevalence rate of 56% (undercut type), 27.27% (parallel type), and 16.36% (convergent type). Similarly ridge morphology in a study by Huang et al. in 2015, U-type ridge was more prevalent than P and C types which comprised of 46.3%, 32.7% and 21.0% respectively. According to outline of buccal and lingual plates Watanabe et al. in 2010 gave A, B and C types in posterior mandibular cross sectional morphology in 79 japanese patients. Type A is round on buccal side and concave on lingual side. Type B concave on buccal side and round on lingual side. Type C as round shaped on both sides. In the results type C was the most common type-59-61% and it was followed by type A-36-39%.[4]

Moreover palpating the lingual side of the ridge for detection of lingual concavity before implant treatment planning is advisable along with radiographic assessment. A study by Leong et al. in 2011 in human cadaver, reported that lingual plate perforation was found to be 0.053% if a regular 3.7 mm tapered implant was used.[11] Tapered implants can be used instead of parallel ones, and placing the implants off axially in case where concavity is encountered and further placement of angled abutment prosthesis reduces the chances of lingual plate perforation after axial placement

CONCLUSION:

The potential risk assessed in the present study by virtual implant planning at mandibular first molar region is negligible, 1.3% to 1.4%. Here it is important to report that despite the undercut type ridge being most common (56%), the low rate of perforation is credited to knowledge of bone type, shape and dimensions derived from preoperative CBCT scanning. Future research should aim at applying method of computer simulation before implant placement to achieve clinical rate of success.

ACKNOWLEDGEMENT:

We would like to acknowledge Department of Oral Medicine and Radiology, CDSRC, Ahmedabad for providing us with CBCT scans necessary for the study.

No conflict of interest.

Table 1: Number and Dimensions of Implants placed, incidence of Implant position relative to Lingual Plate and its Threshold among three morphology types.

Implant size/Threshold		C Type	P Type	U Type	Total	Percent%
4x9 mm	N	18	30	62	110	
	≤2 mm	0	1	14	14	12.7
	≤1 mm	0	0	4	5	4.5
	<0 mm	0	0	0	0	0
4x11 mm	N	8	16	52	76	
	≤2 mm	0	1	14	15	19.7
	≤1 mm	0	0	3	3	3.9
	<0 mm	0	0	1	1	**1.3**
5x9 mm	N	20	24	61	105	
	≤2 mm	0	3	19	22	20.9
	≤1 mm	0	0	3	3	2.8
	<0 mm	0	0	0	0	0
5x11 mm	N	10	13	47	70	
	≤2 mm	0	4	13	17	24
	≤1 mm	0	1	5	6	8.5
	<0 mm	0	0	1	1	**1.4**

Table 2: Mean Distance with Standard Deviation between Implant Tip and LinguaL Plate among Three Morphology Types.

Implant Size(mm)	Mean Distance in Millimeters(SD)		
	C Type	P Type	U Type
4x9 mm	3.54(0.22)	3.32(0.32)	2.96(0.40)
4x11 mm	3.47(0.17)	3.23(0.55)	2.63(0.53)
5x9 mm	3.33(0.28)	2.95(0.16)	2.85(0.36)
5x11 mm	3.23(0.41)	2.88(0.36)	2.41(0.49)

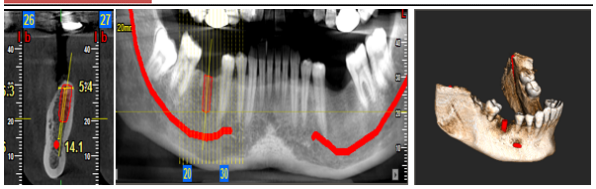

Figure 1: Virtual implant placement using implant planning software and the implant position is verified using reconstructed panoramic and three dimensional images. The distance between implant tip and lingual plate is measured using a digital caliper.

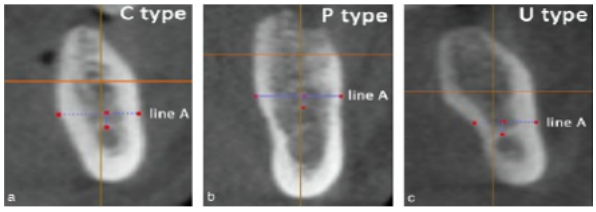

Figure 2: Posterior mandibular cross sectional morphology, three types- C (convergent), P (parellel) & U(undercut) type . Line A is the reference line 2mm above or superior to inferior alveolar canal.

REFERENCES:

1. Stuart Froum, Leticia Casanova, Sara Byrne, Sang Choon Cho. Risk Assessment Before Extraction for Immediate Implant Placement in the Posterior Mandible: A Computerized Tomographic Scan Study. J Periodontol 2011;82:395-402. (https://doi.org/10.1902/jop.2010.100360)
2. Zarb GA, Schmitt A. The longitudinal clinical effectiveness of osseointegrated dental implants in posterior partially edentulous patients. Int J Prosthodont. 1993;6:189-196. (https://www.ncbi.nlm.nih.gov/pubmed/8329097)
3. Lílian Azevedo de Souzaa, Neuza Maria Souza Picorelli Assis, Rosangela Almeida Ribeiroc, Antônio Carlos Pires Carvalhod, Karina Lopes Devito. Assessment of mandibular posterior regional landmarks using cone-beam computed tomography in dental implant surgery. Annals of Anatomy 2016; 205: 53–59. (https://doi.org/10.1016/j.aanat. 2016.01.006)
4. Watanabe H, Mohammad Abdul M, Kuryabayashi Aoki H. Mandible size and morphology on a premise of dental implant operation. Surg Radiol Anat 2010; 32:343-349. (https://doi.org/10.1007/s00276-009-0570-3)
5. Hsun-Liang Chan, Erika Benavides, Chu-Yuan Yeh, Jia-Hui Fu, Ivan E. Rudek, and Hom-Lay Wang. Risk Assessment of Lingual Plate Perforation in Posterior Mandibular Region: A Virtual Implant Placement Study Using Cone-Beam Computed Tomography.J Periodontol 2011; 82: 129-135. (https://doi.org/10.1902/jop.2010.100313)
6. Ren-Yeong Huang, David L. Cochran, Wan-Chien Cheng, Ming-Hung Lin, Wen-Hui Fan, Cheng-En Sung, Lian-Ping Mau, Po-Hsien Huang, Yi-Shing Shieh. Risk of lingual plate perforation for virtual immediate implant placement in the posterior mandible: A computer simulation study. JADA 2015: 146(10): 735-742. (https://doi.org/10.1016/j.adaj.2015.04.027)
7. Schneider D, Marquardt P, Zwahlen M, Jury RE. A systemic review on accuracy and the clinical outcome of computer guided template based implant dentistry. Clinic Oral Implant Res 2009; 20(suppl. 4):73-86. (https://doi.org/10.1111/j.1600-0501.2009.01788.x)
8. Misch CE, Perel ML, Sammartino G, Galindo-Moreno P, Steigmann M. Implant success, survival and failure: The international Congress of Oral Implantologists(ICOI) Pisa Consensus Conference Implant Dent 2008. (HYPERLINK "https://doi.org/10.1097/ID.0b013e3181676059" \t "_blank" 10.1097/ID. 0b013e31816 76059)
9. Chan H-L, Brooks SL, Fu J-H, Yeh C-Y, Rudek I, Wang H-L. Cross-sectional analysis of the mandibular lingual concavity using cone beam computed tomography. Clin. Oral Impl. Res., 2011; 22: 201–206. (https://pdfs.semanticscholar.org/7a14/1156a5581f67a5dfd99872771358764682c2.pdf)
10. Chan HL, Erika Benavides, Chu-Yuan Yeh, Jia-Hui Fu, Ivan E- Rudek, Hom-Lay Wang. Risk Assessment of Lingual Plate Perforation in Posterior Mandibular Region: A Virtual Imlant Placement Study using cone beam computed tomography. J Periodontal 2011; 82:129-135. (https://doi.org/10.1902/jop.2010.100313)
11. Daylene Jack-Min Leong, Hsun-Liang Chan, Chu-Yuan Yeh, Nikplas Takarakis, Jia-Hui Fu, Hom Lam Wang. Risk of Lingual Plate Perforation during Implant Placement in the Posterior Mandible: A Human Cadaver Study. Implant Dentistry 2011; 20(5):360-363. (10.1097/ID.0b013e3182263555)