Research Paper

Volume : 3 | Issue : 6 | June 2014 • ISSN No 2277 - 8179

Audiological Findings in a Child With Ependymoma Extending to Internal Auditory Meatus: A Case Study

Medical Science

KEYWORDS : Ependymoma, Cerebral ventricles, Audiological Evaluation, Neural hearing loss

V Jaya — M.Sc (Speech and Hearing)1, Speech Pathologist and Audiologist, Madras Medical College and Rajiv Gandhi Government General Hospital, Chennai, Tamil Nadu, India

S.S. Vignesh — M.Sc (Audiology)2, Speech Pathologist and Audiologist, Madras Medical College and Rajiv Gandhi Government, General Hospital, Chennai, Tamil Nadu. Pin code: 600 003

ABSTRACT

Ependymoma is a Common childhood tumor. Hearing loss associated with ependymoma is rare. Extension of the tumor into the internal auditory meatus can cause neural type of deafness in children. The audiological findings in a 3 year female child with ependymoma extending into internal auditory meatus is reported in this article.

Introduction

Ependymoma a common childhood tumor, generally appears in the membranous lining of the posterior fossa and the cerebral ventricles. This tumor tends to be slow growing and can be benign or malignant. The fourth ventricle is the most common site (Russell and Rubinstein, 1989).

Incidence of ependymoma is reported to be high between 3-7 years of age (Delong and Adams, 1975). Naidich and Zimmerman (1984) reported a higher incidence in male children. However, west et al (1985) observed more females in a group of 25 patients with ependymoma.

The tumor reoccurs in approximately 30% of the patients (Delong and Adams, 1975; Pierre- Kahn *et al.,* 1983; Ross and Rubinstein, 1989). If tumor recurrence does occur it is usually identified within 4 years of the initial diagnosis (Salazar *et al.,* 1983). Clinical symptoms of the childhood ependymoma depend on the location and size of the tumor. At early stages of tumor first symptoms to occur are increasing head size, irritability, sleeplessness and vomiting. In the later stages of the tumor children may develop balance problems, gait disturbances, weakness in one side of the upper limb and lower limb. Hearing loss associated with ependymoma is rare. Extension of the tumor into the internal auditory meatus can cause neural type of deafness in children. Here, we report audiological findings in a case with ependymoma extending to internal auditory meatus.

Case Report

A 3year old female child with the medical diagnosis of ependymoma extending into the right internal auditory meatus was referred from Department of Neurology for Audiological Evaluation to our department. Parents have reported to the hospital with the complaint of sudden onset of difficulty in walking steadily and difficulty in turning her head suddenly towards left side since 20days. 1.5T MRI Scan of Brain with contrast and spine screening revealed a well defined heterogenous enhancing mass lesion in the right CP angle cistern with extension in to the forth ventricle, foramen luska and foramen magnum and upper cervical canal along the right lateral aspect up to the C3 vertebral body level. Obliteration of the 4th ventricle with triventricular hydrocephalus was observed. The lesion measured 5.2x5.7.x4.7cms and minimal extension in to the right Internal Auditory Meatus noted as seen in Figure 1. Child underwent Left VP shunt surgery using medium pressure valve thereafter.

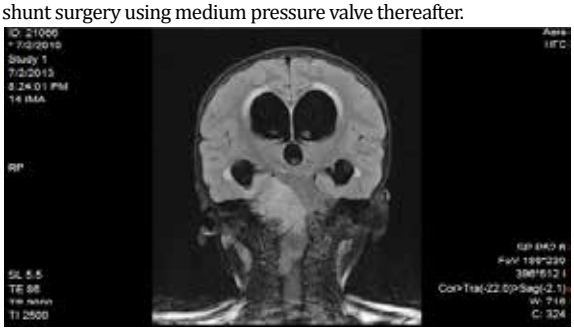

Fig 1: shows 1.5T MRI Scan of Brain with contrast showing extension of tumor into the internal auditory meatus.

Method

Audiological Evaluation was carried out using Visual Reinforment Audiometery, Impedance Audiometry, Otoacoustic emissions and Auditory Brainstem responses.

Visual Reinforcement Audiometry was done using Inventis piano VRA plus Audiometer with animated toys and free field speakers placed at 45 degree angle. The sound field testing results obtained from the child for each frequency is shown in Table 1.

Table 1: shows threshold levels obtained under sound field testing using visual reinforcement audiometry

Frequency	250 Hz	500 Hz	1K Hz	2K Hz	4K Hz	8K Hz
Threshold	30 dB HL	25 dB HL	25 dB HL	25 dB HL	30 dB HL	40 dB HL

Tympanograms and acoustic reflex testing were carried out for both the ears using Inventis flute Impedance Audiometer. A type tympanograms were obtained in both ears with compliance of 0.67ml in right ear and 0.54ml in left ear which showed intact mobility of tympanic membrane and ossicles. Acoustic stapedial reflexes were absent in right ear over ipsilateral, contralateral stimulation. They were present over left ear ipsilateral stimulation and absent over contralateral stimulation suggesting involvement of auditory nerve and stapedial branch of facial nerve in right side as shown in Figure 2.

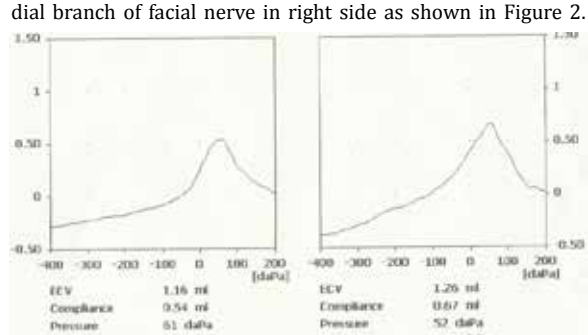

Fig 2: shows tympanograms of left ear (left panel) and right ear (right panel)

Transient evoked otoacoustic emissions (TEOAE's) were recorded for click stimuli at 88dBSpl in both ears separately. TEOAE were present in both ears with reproducibility of 80% and signal to noise ratio of 6dB and above at frequencies of 1000,2000,3000,4000 and 5000Hz. The TEOAE results as in Figure 3 indicate adequate physiological functioning of the outer hair cells in both the ears.

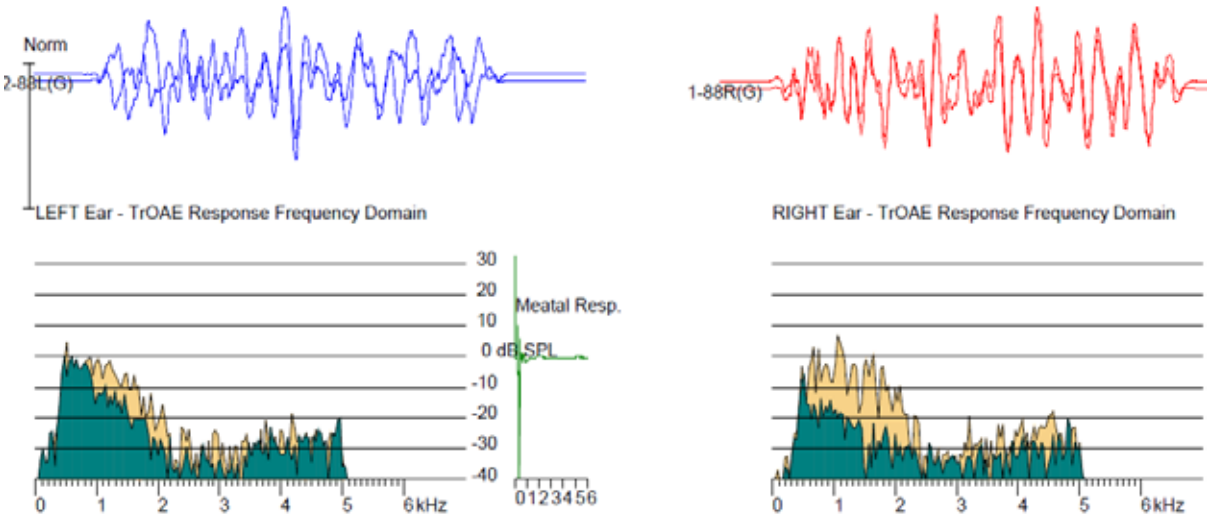

Fig 3: Temporal and spectral representation of TEOAE recorded for the child with ependymoma

Auditory brainstem responses (ABR) were recorded for click stimuli at 99dBnHL at 11.1/sec stimulation rate using Intelligent Hearing smart evoked potentials systems. Replicable Wave I, III & V peaks were observed within the latency ranges of 1.5,3.4& 5.6msec respectively in left ear, but no replicable responses were recorded in the right ear except peak I as shown in Figure 4.

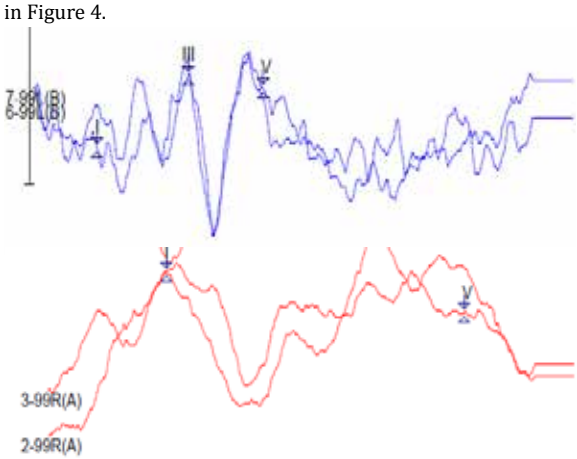

Fig 4: Auditory Brain stem responses recorded at 90dBnHL in Right ear (Red) & left ear (Blue).

Discussion

Audiological findings in patients with ependymoma are rarely reported in the literature. Though free field audiometry indicated normal hearing sensitivity in this child absence of ABR responses indicated significant severe to profound hearing impairment in right ear. 'A' type tympanogram and present TEOAEs results ruled out any middle ear pathology in both the ears. Ipilateral and contralateral acoustic reflexes indicated 7th and 8th cranial nerve dysfunction in right ear. Presence of TEOAE's suggested normal outer hair cell functioning and indicates that the tumor has not compressed the common cochlear artery supplying cochlea in right ear. Also auditory brainstem responses morphology was poor in right ear suggesting compression of auditory nerve at cochlear nucleus, Lateral lemniscus and inferior colliculus. These findings correlated with the case reports of acoustic tumors (Jerger et al, 1987).

Conclusion

Since hearing loss associated with ependymoma is uncommon, in this article we document the audiological findings associated with ependymoma. Comprehensive and detailed audiological evaluation is essential to identify and diagnose hearing loss. Investigations related to hearing can provide us with valuable information regarding the site of lesion which will help in further management.

REFERENCE

1.Russell,D.S. and Rubinstein, L.J. (1989). Pathology of Tumors of the Nervous system 5th Ed.., London, Edward Arnold. 2.Delong, G.R and Adams,R.D. (1975). Clinical aspects of tumour of the posterior fossa in childhood. In Vinken P.J., and Bruijn, G.W. (Eds). Handbook of Clinical Neurology, Vol.18: Tumors of the Brain and Skill, Part III, Amsterdam, North Holland, PP.387-411. 3.Naidich,T.P. and Zimmerman,R.A. (1984). Primary brain tumors in children. Seminars in Roentgenology,19,PP. 100-14. 4.Pierre-Kahm,a., Hirsch,J.F., Roux,F.X., Renier,D. and Sainte- Rose,C. (1983). Intracranial Ependymomas in childhood. Survival and Functional Results of 47 cases. Child's Brain, 10, pp. 145-56. 5.Ross, G.W. and Rubinstein,L.J. (1989) ' lack of histopathological correlation of malignant ependymomas with postoperative survival. Journal of Neurosurgery, 70, PP 31-6. 6.Salazar, O.M., Castro –Vita,H., Van Houtte, P., Rubin, P. and Aygun, C. (1983) ' Improved survival in cases of intracranial ependymoma agter radiation therapy: late report and recommendations. Journal of Neurosurgery, 59, pp. 652-9. 7.Jerger, J., Oliver, T.A., & Jenkins, H. (1987). Supra threshold abnormalities of the stapedial reflex in acoustic tumors. Ear and Hearing, 8, 131-139.