ORIGINAL RESEARCH PAPER

Volume-8 | Issue-1 | January-2019 | PRINT ISSN No 2277 - 8179

INTERNATIONAL JOURNAL OF SCIENTIFIC RESEARCH

BLACK MOLD STEALS LIFE: A FATAL CASE OF RHINO-ORBITO-CEREBRAL MUCORMYCOSIS

Microbiology

Dr. Subhranshu Mandal* The calcutta Medical Research Institute , Kolkata *Corresponding Author

Dr. Pragati Sinha The calcutta Medical Research Institute , Kolkata

Dr. Debkishore Gupta The calcutta Medical Research Institute , Kolkata

Dr. Saikat Pal The calcutta Medical Research Institute , Kolkata

Paromita Majumdar The calcutta Medical Research Institute , Kolkata

ABSTRACT

A 45 yrs old muslim woman with uncontrolled diabetes presented in unconscious state with a black eschar in left infraorbital region. MRI brain and orbit revealed a large extensive infarct in left middle cerebral artery and anterior cerebral territory with mass effect and uncal herniation. Pupil was nonreacting in right eye with reduced intraocular Proptosed Left Eye. Broad aseptate hyphae suggestive of zygomycetes was identified in nasal swab microscopy, which was confirmed by fungal culture. Inspite of early administration of Amphotericin B and strict sugar control, patient succumbed as debridement of necrosed tissue could not be done. For improving survival rates in rhino-orbito-cerebral mucormycosis, a combined approach involving early diagnosis, reversal of risk factors , surgical debridement and prompt antifungal therapy is required.

KEYWORDS

Rhino-orbito-cerebral mucormycosis, zygomycetes, Amphotericin B

INTRODUCTION

Rhino-orbito-cerebral mucormycosis is the most common form of mucormycosis seen in patients with uncontrolled diabetes[1].Though not so common in incidence, it has a rapidly progressive course and associated with high mortality[2]. Clinical presentation depends on the arteries involved resulting in infarct in cerebral areas and necrosis of affected organs. A high index of suspicion and early diagnosis is crucial but not enough for improving survival rates.

CASE REPORT

We report a case of a 45 yrs old muslim woman who was brought to the emergency department in unconscious state with a black eschar in the left infraorbital region.She was admitted to other hospital with c/o chest pain 10 days back. Later, she developed pain, redness and loss of vision in left eye with charring of skin below left eye. There was no history of fever. She was a known hypertensive and diabetic for 14 years, but on irregular medications. There was also a history of admission to other hospital 1 month back from where she was discharged with diagnosis of lower respiratory infection. No history of trauma was found. Nothing significant was found in her personal and past history.

At the time of admission, pulse rate was 92/min, blood pressure 140/90 mm Hg, temperature 98.7 F and respiratory rate was 27/min. No icterus, cynosis, clubbing, oedema and lymphadenopathy was noted. Oxygen saturation at room air was 91%. glosgow coma score was 8/15 : E2M5V1. Chest was bilaterally clear with fair air entry. No added sounds were found on chest auscultation. Abdomen was soft and tender with no organomegaly.

She was put on ventilator. Initial management started with amphotericin B due to suspicion of mucormycosis and rapid acting insulin for sugar control. An urgent MRI Brain and orbit was sought along with an ophthalmologist opinion. Nasal swab for fungal microscopy and culture with other routine investigations were sent. IV mannitol, dexamethasone and antiseizure prophylaxis were added in the treatment regime.

Her blood reports came as: Hemoglobin -8.6%, capillary blood glucose -258 mg/dl, Total leucocyte count 24,200.

Nasal swab for fungal microscopy showed broad aseptate hyaline hyphae suggestive of zygomycetes. Gram stain of the same showed moderate number of pus cells with no pathogenic organism.

Right eye showed clear cornea with non reacting pupil. Left eye was proptosed with hazy cornea due to stromal oedema. Digital intraocular pressure of left eye was reduced.

Chest X-ray showed patchy inhomogenous opacities in left upper and mid zones. Left hilar prominence and blunting of left costophrenic angle was present. MRI brain and orbit showed a large extensive infarct in left middle cerebral artery and anterior cerebral territory with mass effect and uncal herniation. Small acute infarct in left cerebellum was observed. Inflammatory changes were seen in left maxillary, left frontal and both ethmoid and sphenoid sinuse suggestive of zygomycetes.

Later, fungal culture grew mucor species that confirmed the diagnosis of mucormycosis.

However, due to advanced disease condition, debridement of necrosed tissue and/or orbital exenteration could not be done. Patient continued to deteriorate and expired.

DISCUSSION

Mucormycosis is caused by fungi of the order mucorales. Clinically, it can be classified according to the site affected as rhino-orbito-cerebral mucormycosis, pulmonary, gastrointestinal, cutaneous, renal and disseminated types. It has an extremely aggressive course and early diagnosis is crucial. A high index of suspicion has to be maintained. In recent years, its incidence has increased in patients with compromised immune status like uncontrolled diabetes, transplant recepients and in patients with hematological malignancies undergoing chemotherapy. Iron overload and prematurity constitute the other risk factors.[3,4]

Prevalence of mucormycosis in India is around 0.14 cases/1000 cases and 1.6 cases/1000 in diabetics[5,6]. Though mostly sporadic, outbreaks have also been documented in community and hospital settings[7,8]. Most common genera responsible for these invasive infections are Rhizopus, Rhizomucor, mucor and Absidia . Mucormycosis due to mucor is rare[9].Espinel-Ingroff et al reported 156 cases of mucormycosis, of which fungus was identified in all cases. Among them,mucor was involved in 19 cases only while rhizopus was in 95 cases.[10] Mucor are saprophytic and found in soil and air. Infection occurs mainly through spore inhalation and sometimes through skin laceration. The fungal hyphae and found in spread through the paranasal sinuses and into the blood stream and rapidly spreads to other organs. In the blood vessels, hyphae form thrombi which reduces

vascularity and form necrotic eschar[11]. Defective phogocytosis and impaired neutrophilic activation appears to be the pathogenesis in diabetic patients. Impaired iron binding and transport are contributory as iron helps in growth of this fungi.[12]

The principles of management includes early diagnosis, surgical debridement of necrosed tissue, reversal of risk factors and prompt antifungal therapy[13]. For diagnosis, serological and molecular tests are lacking so, microscopy is the most rapid diagnostic method. Aseptate, hyaline ribbon like hyphae presumptively diagnose mucormycosis. Surgical debridement of necrosed tissue is crucial as it interferes with penetration of antifungal agents. Multiple case series have also been reported from other parts of the world that support the fact that those who did not undergo surgical debridement have higher mortality rates.[14-15]

Early initiation of antifungal therapy improves survival rates[15]. concluded in many studies. Chamilos et al in his study found that if treatment as was initiated within 5 days of diagnosis, survival markedly improved compared to >=6 days after diagnosis.[16] Liposomal Amphotericin B remains the first choice antifungal agent for treatment of mucormycosis.It has been associated with better survival rates as compared to amphotericin B deoxycholate[17]. Posaconazole is the only FDA approved azole with intrinsic activity against mucorales, Inferior to amphotericin B , it can be used as salvage therapy.[18] Combination therapy of polyene-caspofungin has been found to be associated with improved outcomes in few studies but data is limited.[19] Deferasirox in salvage therapy has favourable outcome but experience is limited.[17]

CONCLUSION

For improving survival rates in rhino-orbito-cerebral mucormycosis, a combined approach involving early diagnosis, reversal of risk factors , surgical debridement and prompt antifungal therapy is required.



PATIENT WITH BLACK ESCHAR BELOW LEFT EYE

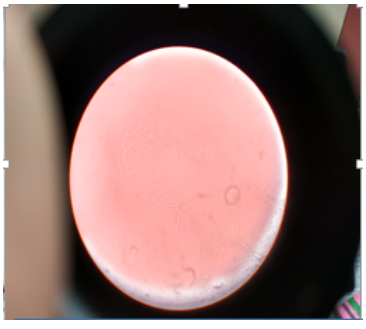

BROAD ASEPTATE HYPHE SEEN ON MICROSCOPY.

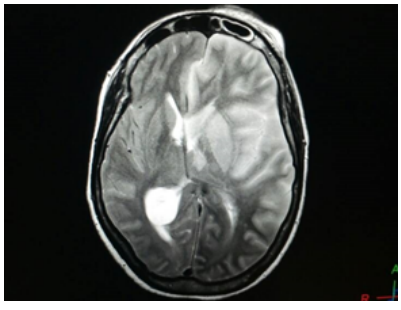

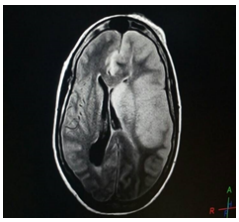

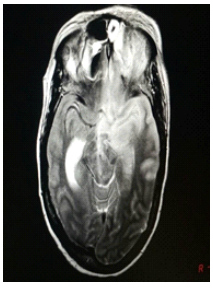

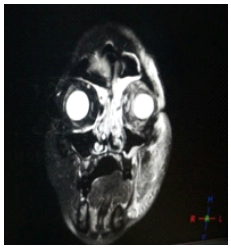

MRI BRAIN AND ORBIT SHOWING INFARCT

REFERENCES

1) Spellberg B, Edwards J, Ibrahim A. Novel perspectives on mucormycosis: pathophysiology, presentation, and management. Clin Microbiol Rev . 2005;18(3):556–569
2) del Río Pérez O, Santín Cerezales M, Mañós M, Rufí Rigau G, Gudiol Munté F.[Mucormycosis: a classical infection with a high mortality rate. Report of 5 cases]. Rev Clin Esp. 2001 Apr;201(4):184-7. Spanish. PubMed PMID: 11447902.
3) Petrikkos G, Skiada A, Lortholary O, Roilides E, Walsh T J, Dimitrios P. Kontoyiannis; Epidemiology and Clinical Manifestations of Mucormycosis, Clinical Infectious Diseases, Volume 54, Issue suppl_1, 1 February 2012, Pages S23–S34
4) Saegeman V., Maertens J., Meersseman W., Spriet I., Verbeken E., Lagrou K. Vol. 16. University Hospital, Belgium; 2010. Increasing Incidence of Mucormycosis. pp. 1456–1458
5) Bhansali A, Bhadada S, Sharma A et al. Presentation and outcome of rhino-orbital-cerebral mucormycosis in patients with diabetes. Postgrad Med J 2004;80:670-4.
6) Chakrabarti A, Sood P, Denning D. Estimating fungal infection burden in India using computational models: mucormycosis burden as a case study. European Society of Clinical Microbiology and Infectious Diseases, Berlin, Germany;27-30 April,2013.
7) Rammaert B, Lanternier F, Zahar JR, et al. Healthcare -associated mucormycosis. Clin Infec Dis 2012;54 (suppl 1):S44-S54.
8) Al-Ajam MR,Bizri AR,, Mokhbat J et al. Mucormycosis in Eastern Mediterranean: a seasonal disease.Epidemiol Infect 2006;134:341-6
9) Lunge SB, Sajjan V, Pandit AM, Patil VB. Rhinocerebrocutaneous mucormycosis caused by Mucor species: A rare causation. Indian Dermatol Online J. 2015;6(3):189-92.
10) Lunge SB, Sajjan V, Pandit AM, Patil VB. Rhinocerebrocutaneous mucormycosis caused by Mucor species: A rare causation. Indian Dermatol Online J. 2015;6(3):189-92.
11) Hosseini S, Borghei P. Rhinocerebral mucormycosis:pathways of spread. Eur Arch Otorhinolaryngol. 2005;262:932–938.
12) Ibrahim AS, Spellberg B, Walsh TJ, Kontoyiannis DP. Pathogenesis of mucormycosis. Clin Infect Dis. 2012;54 Suppl 1(Suppl 1):S16-22.
13) Cornely O.A., Arikan-Akdagli S., Dannaoui E., Groll A.H., Lagrou K., Chakrabarti A. ESCMID and ECMM joint clinical guidelines for the diagnosis and management of mucormycosis. Clin. Microbiol. Infect. 2014;20(3):5–26
14) Jin-Geun Kim, Hye Jeong Park, Jung Hyun Park, Jiwoong Baek, Hyung Jun Kim, In-Ho Cha, Woong Nam. Importance of immediate surgical intervention and antifungal treatment for rhinocerebral mucormycosis.
15) Yohai R.A., Bullock J.D., Aziz A.A., Markert R.J. Survival factors in rhino-orbital-cerebral mucormycosis. Surv. Ophthalmol. 1994;39(1):3–22
16) Chamilos G, Lewis RE, Kontoyiannis DP: Delaying amphotericin B-based frontline therapy significantly increases mortality among patients with hematologic malignancy who have zygomycosis. Clin Infect Dis 2008, 47:503–509.
17) Spellberg B, Ibrahim AS. Recent advances in the treatment of mucormycosis.
18) Curr Infect Dis Rep. 2010 Nov;12(6):423-9
19) Van Burik JA, Hare RS, Solomon HF, et al. Posaconazole is effective salvage therapy in zygomycosis: a retrospective summary of 91 cases. Clin Infect Dis. 2006;42:e61-65.
20) Reed C, Bryant R, Ibrahim AS, Edwards J Jr, Filler SG, Goldberg R, SpellbergB. Combination polyene-caspofungin treatment of rhino-orbital-cerebralmucormycosis. Clin Infect Dis. 2008 Aug 1;47(3):364-71.